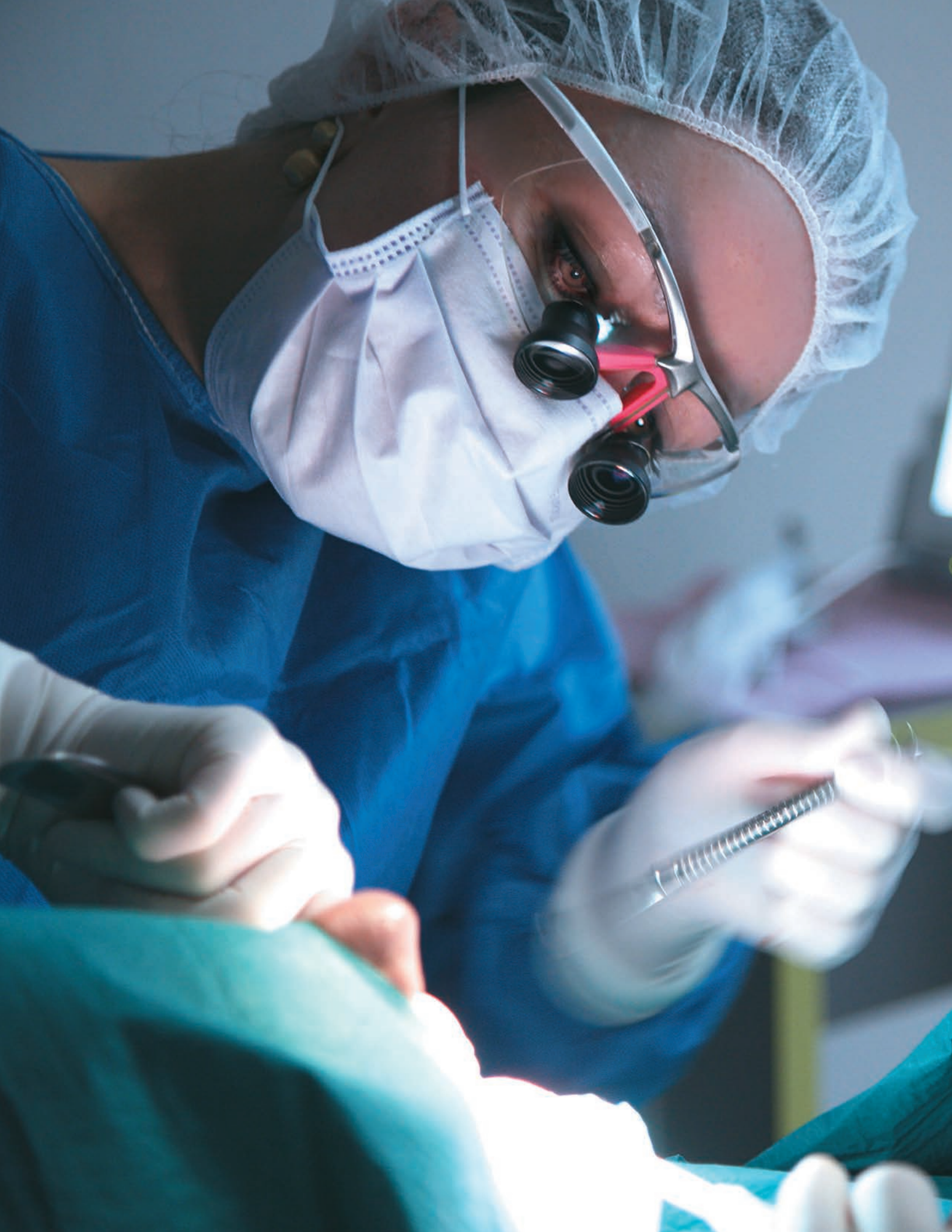

CopiOs Extend[®] Membranes

Clinical Case Studies





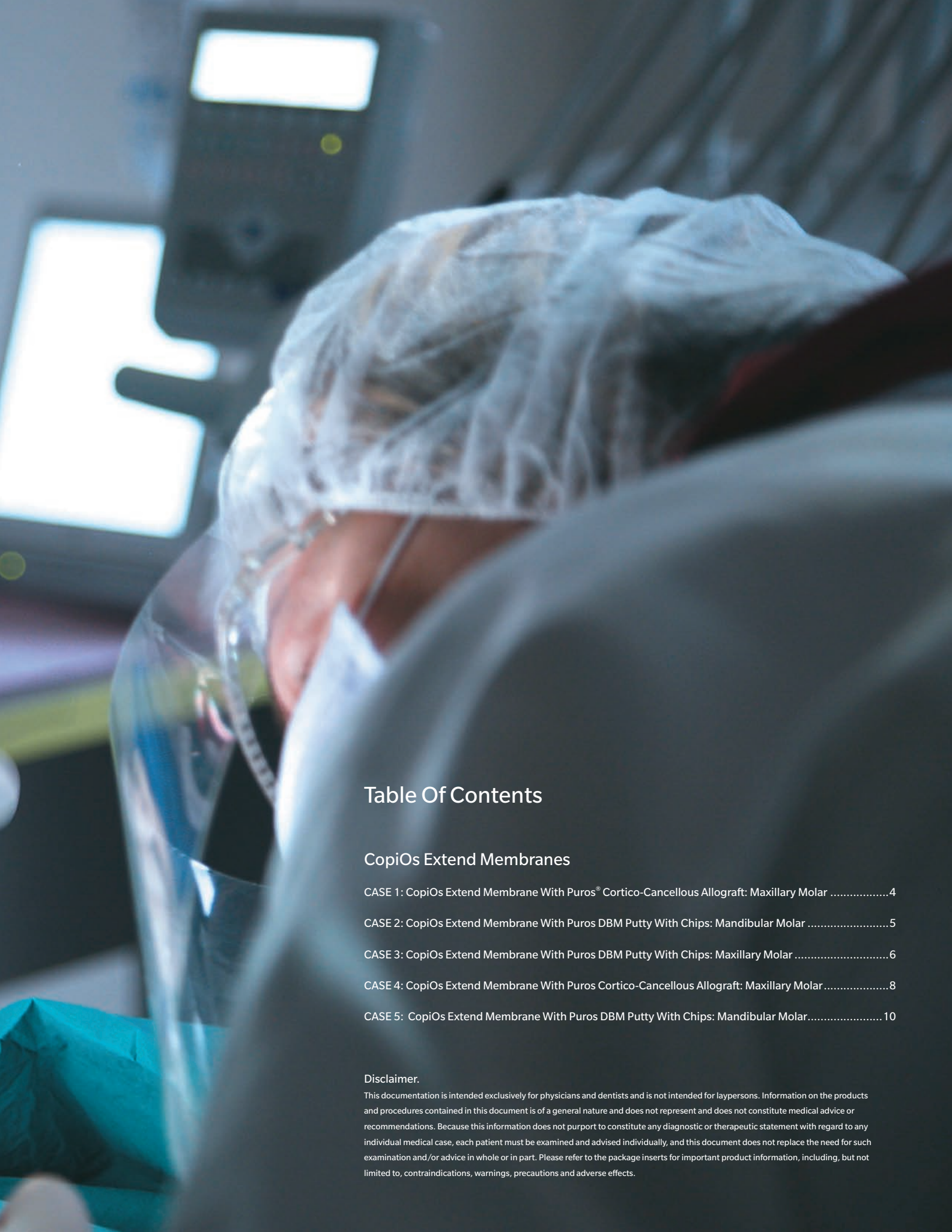

Table Of Contents

CopiOs Extend Membranes

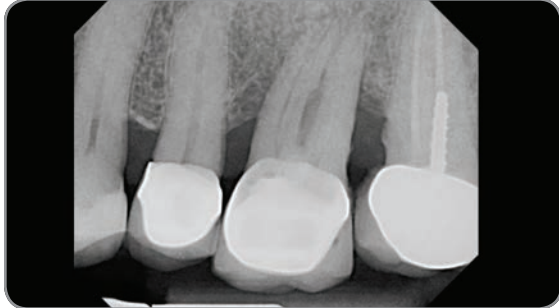CASE 1: CopiOs Extend Membrane With Puros® Cortico-Cancellous Allograft: Maxillary Molar	4
CASE 2: CopiOs Extend Membrane With Puros DBM Putty With Chips: Mandibular Molar	5
CASE 3: CopiOs Extend Membrane With Puros DBM Putty With Chips: Maxillary Molar	6
CASE 4: CopiOs Extend Membrane With Puros Cortico-Cancellous Allograft: Maxillary Molar	8
CASE 5: CopiOs Extend Membrane With Puros DBM Putty With Chips: Mandibular Molar	10

Disclaimer.

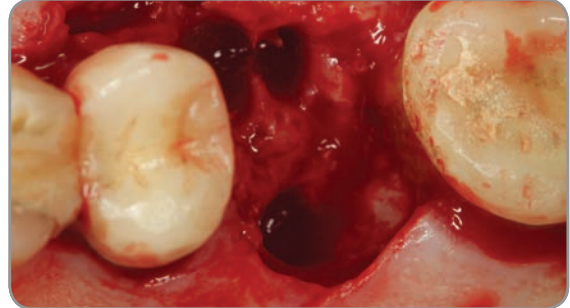
This documentation is intended exclusively for physicians and dentists and is not intended for laypersons. Information on the products and procedures contained in this document is of a general nature and does not represent and does not constitute medical advice or recommendations. Because this information does not purport to constitute any diagnostic or therapeutic statement with regard to any individual medical case, each patient must be examined and advised individually, and this document does not replace the need for such examination and/or advice in whole or in part. Please refer to the package inserts for important product information, including, but not limited to, contraindications, warnings, precautions and adverse effects.

CASE #1

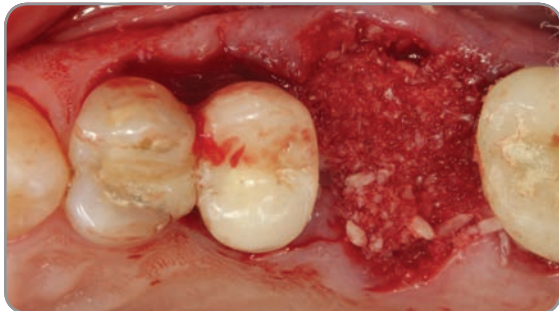
CopiOs Extend Membrane with Puros Cortico-Cancellous Allograft: Maxillary Molar



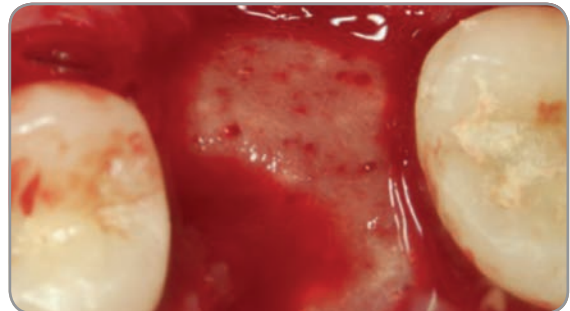
1. Preoperative radiograph showing the poor periodontal prognosis of 1st molar and bone loss on mesial of the 2nd molar.



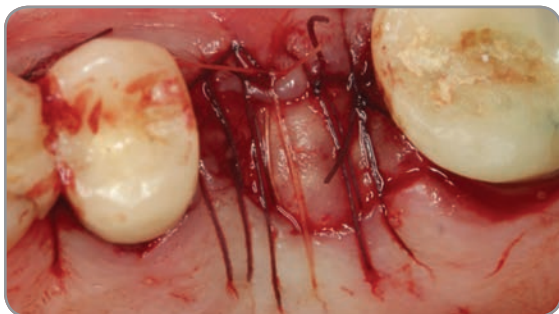2. View of the extraction socket revealing the extent of bone loss on the mesial of the 2nd molar.



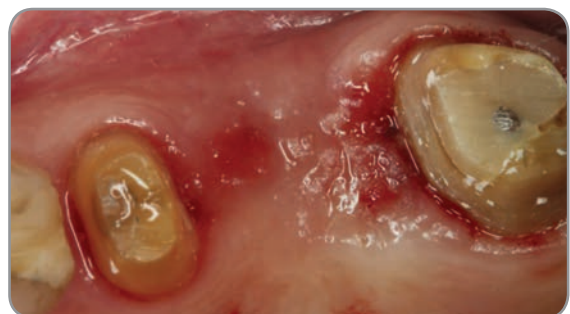3. Puros Cortico-Cancellous Allograft placed in the socket.



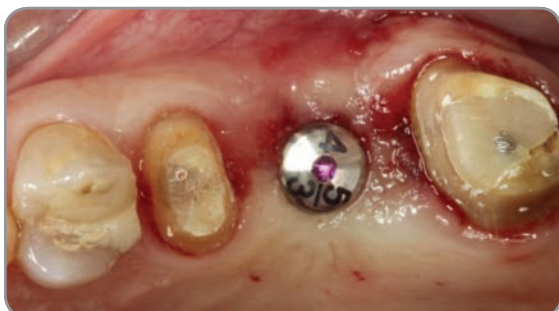4. CopiOs Extend Membrane tucked under the flap and laid over the graft.



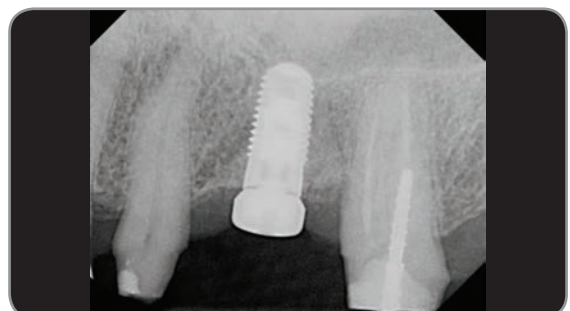5. Sutures stabilize the membrane.



6. Healing at six months.



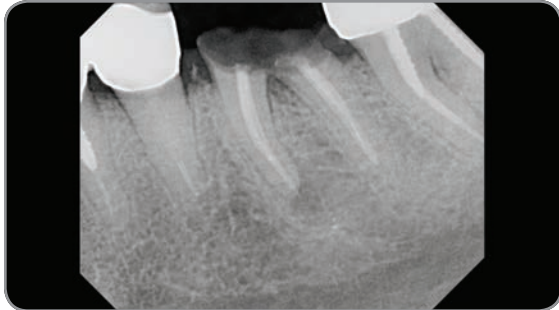7. Zimmer® Tapered Screw-Vent® implant placed without flap.



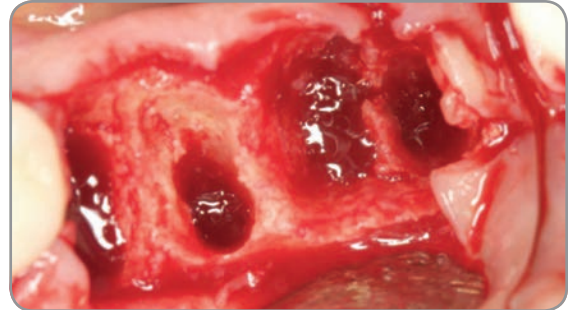
8. Post-operative radiograph four months after the Zimmer Tapered Screw-Vent implant placement.

CASE #2

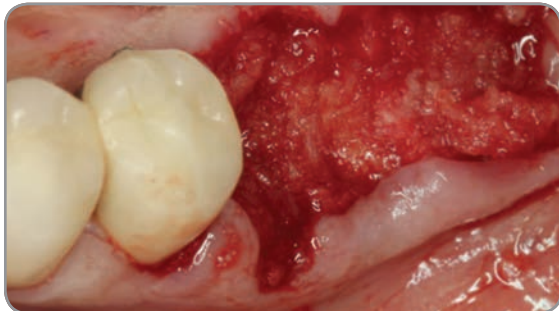
CopiOs Extend Membrane with Puros DBM Putty with Chips: Mandibular Molar



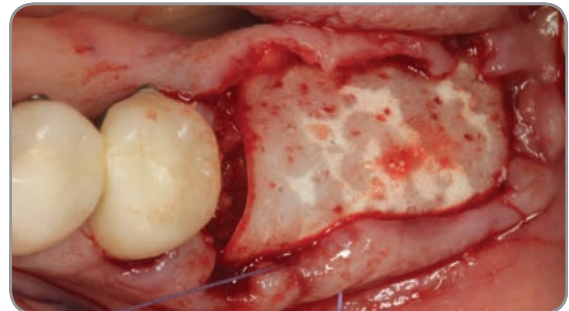
1. Preoperative radiograph revealing fractured molars.



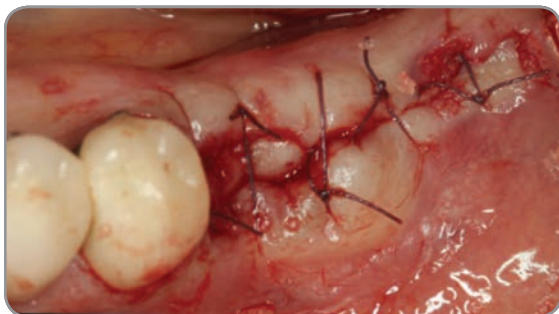2. Surgical site after extraction exhibiting substantial bone loss on the buccal wall of mandibular molars.



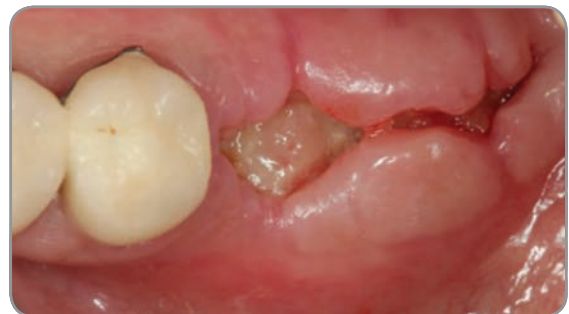3. Puros DBM Putty with Chips molded in place.



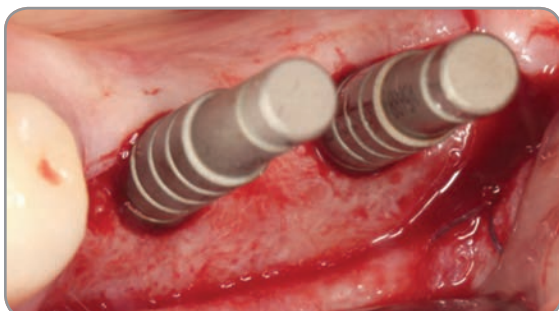
4. CopiOs Extend Membrane placed over the graft and stabilized by the flap.



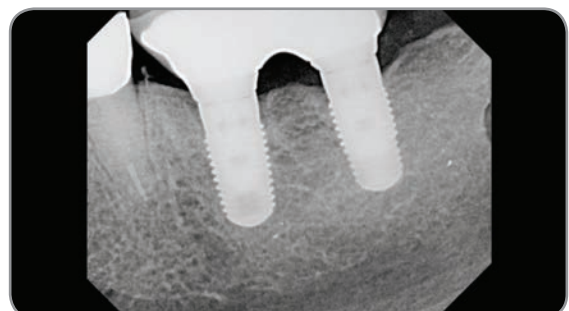
5. Flap sutured.



6. Two-weeks post-operative image.



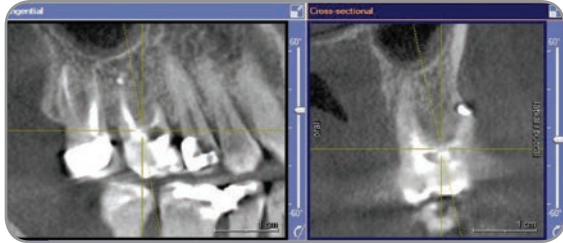
7. Site preparation at six months to receive two Zimmer Tapered Screw-Vent implants.



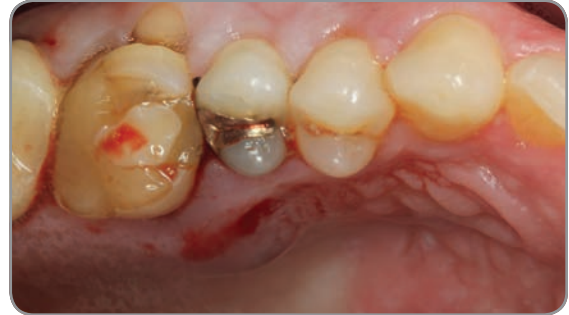8. Radiograph of implants one-year post loading.

CASE #3

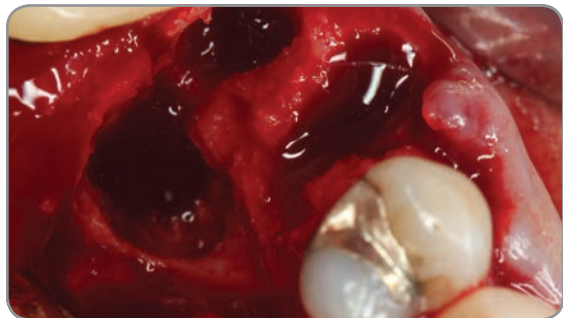CopiOs Extend Membrane with Puros DBM Putty with Chips: Maxillary Molar



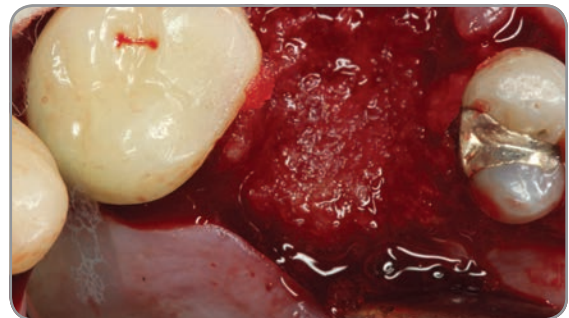
1. Preoperative CBCT showing the extensive bone loss mostly on the palatal root.



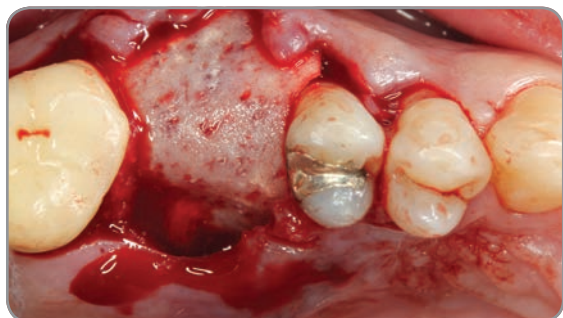2. Clinical image showing the palatal abscess.



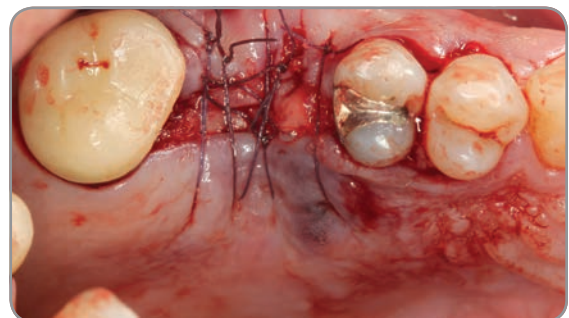
3. Clinical image showing the extensive bone loss on the palatal area extending past apex.



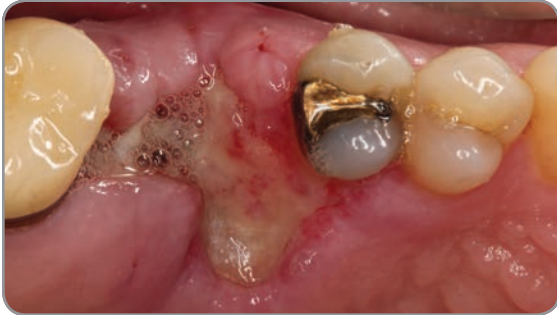4. Puros DBM Putty with Chips was molded in the area.



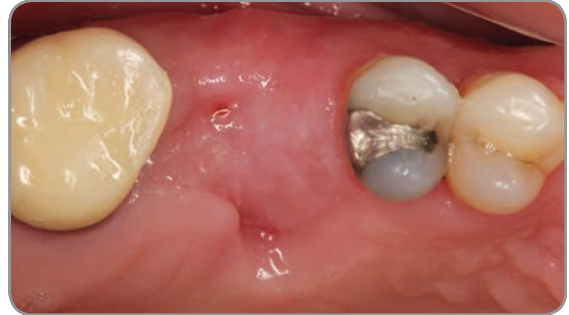5. CopiOs Extend Membrane was laid over the graft and tucked under the flap.



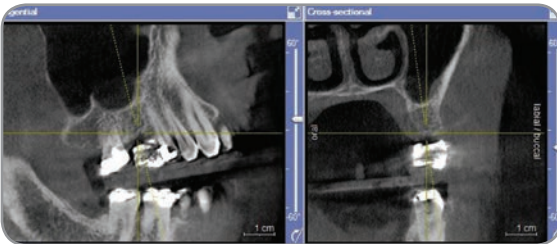
6. Flap sutured over the membrane.



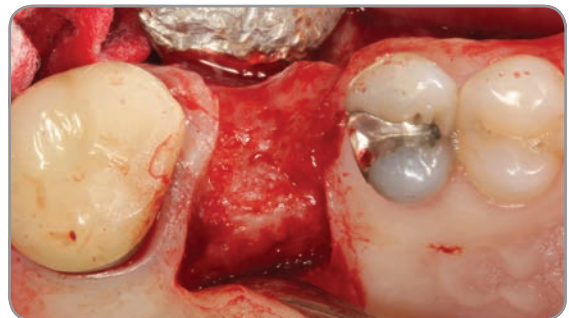7. One-week post-operative.



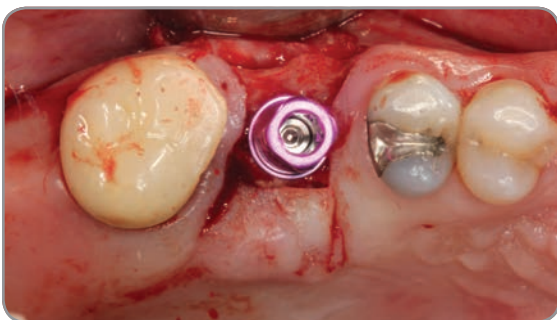
8. Two-months post-operative.



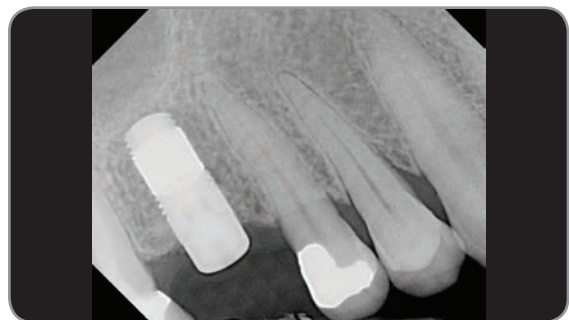
9. Six-month CBCT scan showing the bone regenerated in the grafted site.



10. Clinical view of grafted site at six months with flap raised for implant placement.



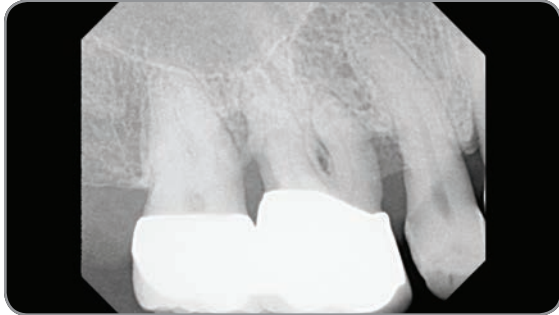
11. Zimmer Trabecular Metal™ Dental Implant in place.



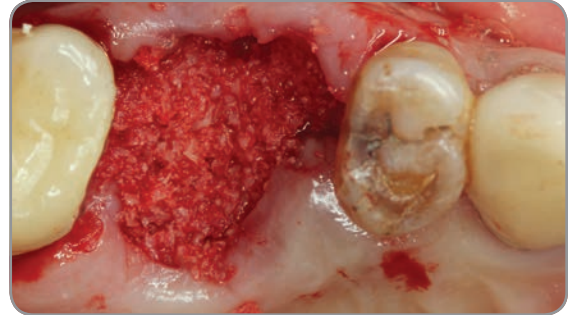
12. Post-operative radiograph of Zimmer Trabecular Metal Dental Implant in place.

CASE #4

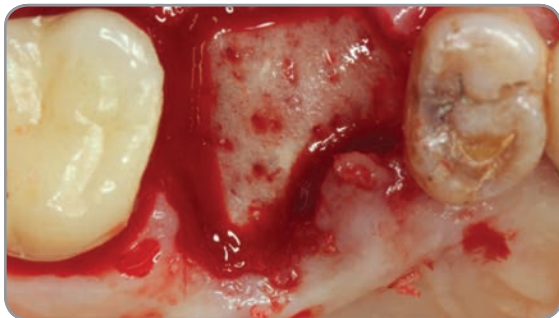
CopiOs Extend Membrane with Puros Cortico-Cancellous Allograft: Maxillary Molar



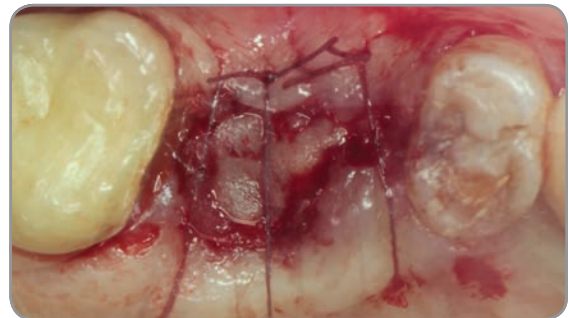
1. Preoperative radiograph showing the poor periodontal prognosis.



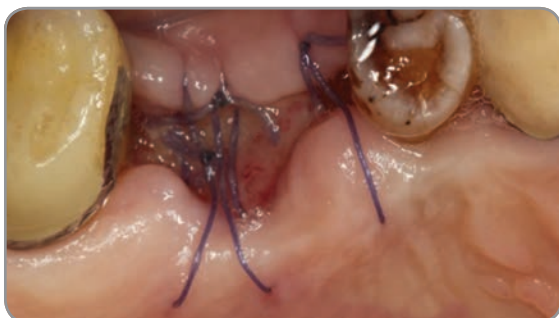2. Puros Allograft placed in the socket.



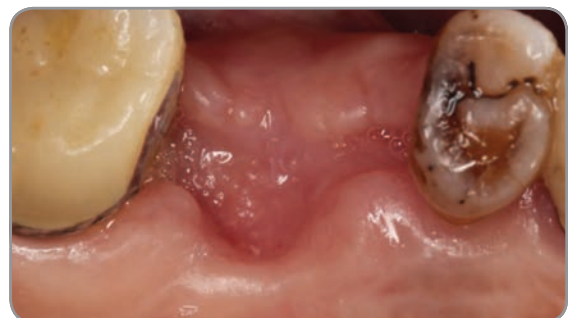3. CopiOs Extend Membrane tucked under the flap over the graft.



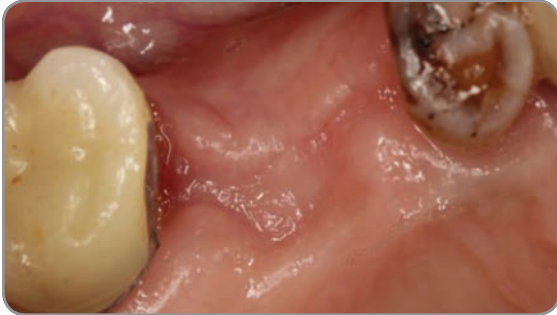
4. Sutures secure the membrane.



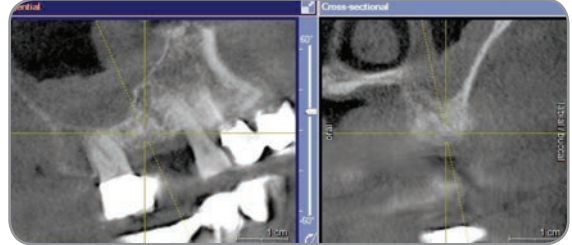
5. Two-weeks post-operative.



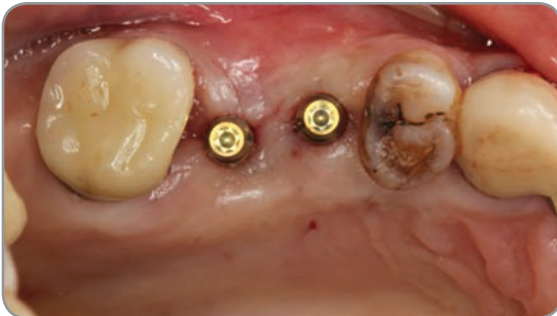6. One-month post-operative.



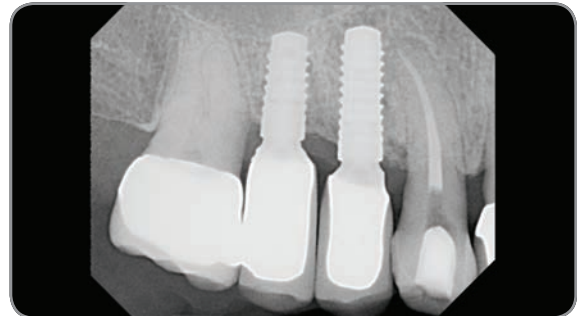7. Six-months post-operative.



8. A CBCT image before implant placement showing adequate bone regeneration at the site.



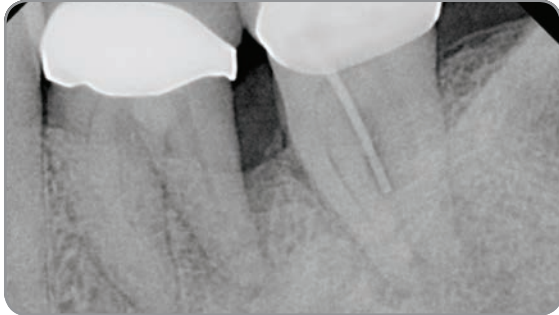
9. Two 3.0 mm small diameter implants placed.



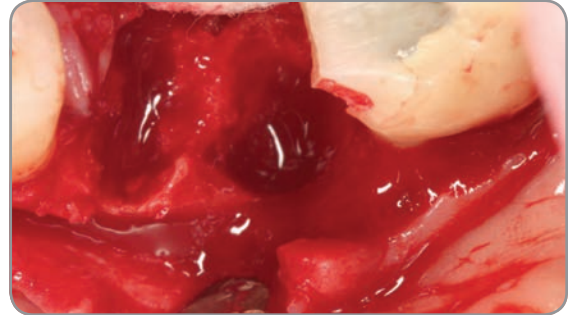
10. Two-year post-operative radiograph.

CASE #5

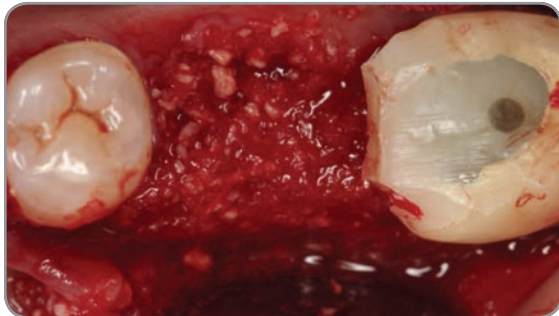
CopiOs Extend Membrane with Puros DBM Putty with Chips: Mandibular Molar



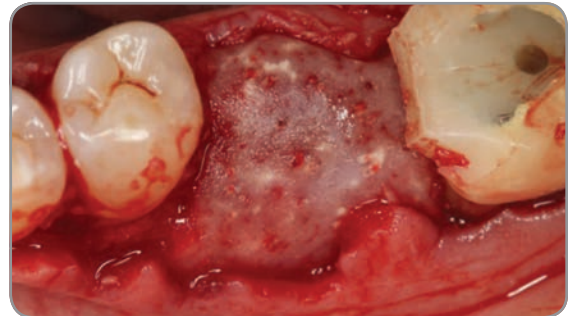
1. Preoperative radiograph showing the perio-endodontic lesion around the distal root of 1st molar.



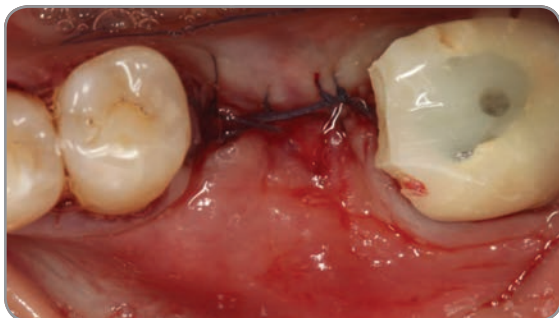2. Surgical site after extraction exhibiting a substantial bone loss on the disto-buccal wall of 1st molar and mesial root of 2nd molar.



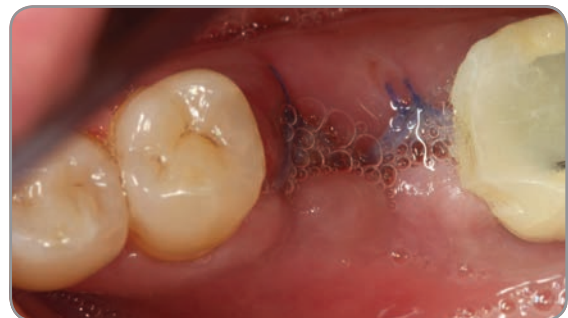3. Puros DBM Putty with Chips molded in place.



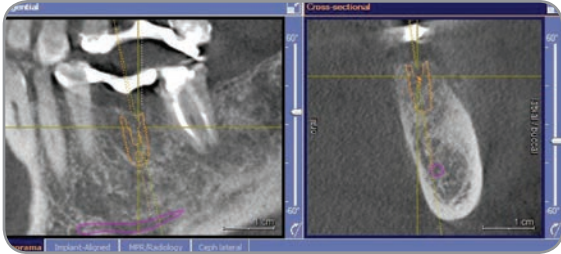
4. CopiOs Extend Membrane laid over the graft and stabilized by the flap and a tack on the buccal.



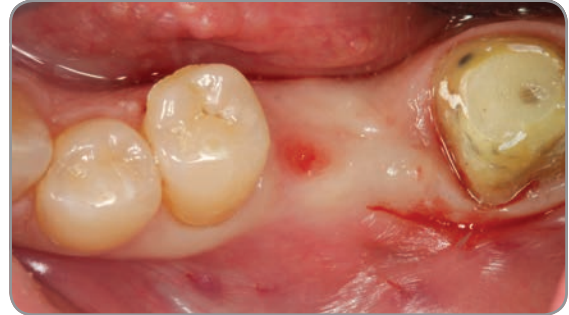
5. Flap sutured.



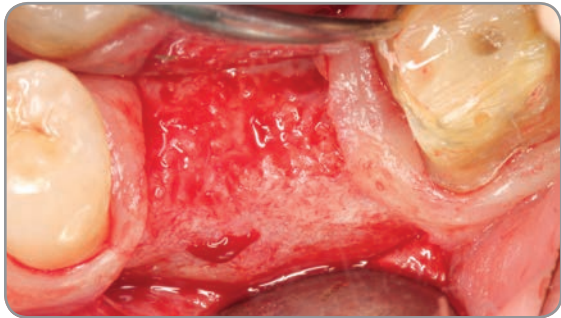
6. One-week post-operative.



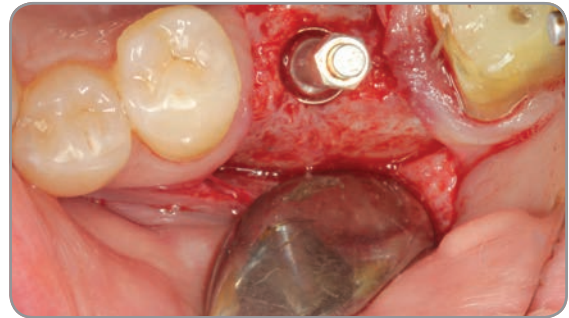
7. Six-month post-operative CBCT image prior to implant placement showing adequate regeneration.



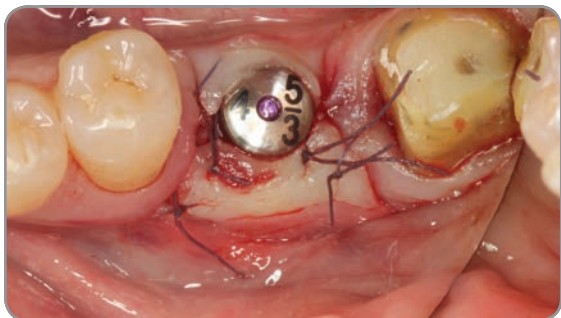8. Six-month post-operative image.



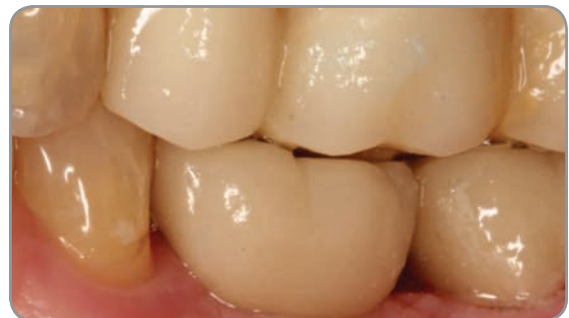9. Clinical image of the site regenerated.



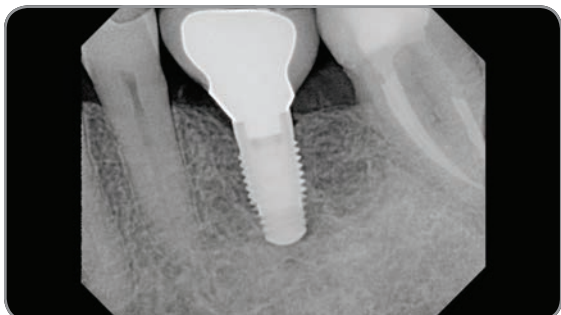
10. Site preparation to receive a Zimmer Tapered Screw-Vent implant.



11. Flap sutured around the healing abutments. Implant stability was sufficient for a single-stage procedure.



12. Picture of final restoration at one-year post-operative.



13. Radiograph of implants one year post loading.



+31 (0)577 461927 | www.implacom.nl

All references to Zimmer Biomet Dental contained herein refer to the dental subsidiaries of Zimmer Biomet Holdings, Inc. Unless otherwise indicated, as referenced herein, all trademarks are the property of Zimmer Biomet; and all products are manufactured, distributed and marketed by Zimmer Biomet Dental (and, in the case of distribution and marketing, its authorized marketing partners). CopiOs Extend Membranes are manufactured by Collagen Matrix, Inc. Puros Allografts are manufactured by RTI Surgical, Inc. For additional product information, please refer to the individual product labeling/IFU. Product clearance and availability may be limited to certain countries/regions. This material is intended for clinicians only and does not comprise medical advice or recommendations. This material may not be copied or reprinted without the express written consent of Zimmer Biomet. ZB0020 REV B 01/18 ©2018 Zimmer Biomet. All rights reserved.

