

Clinical Cases For Regenerative Materials

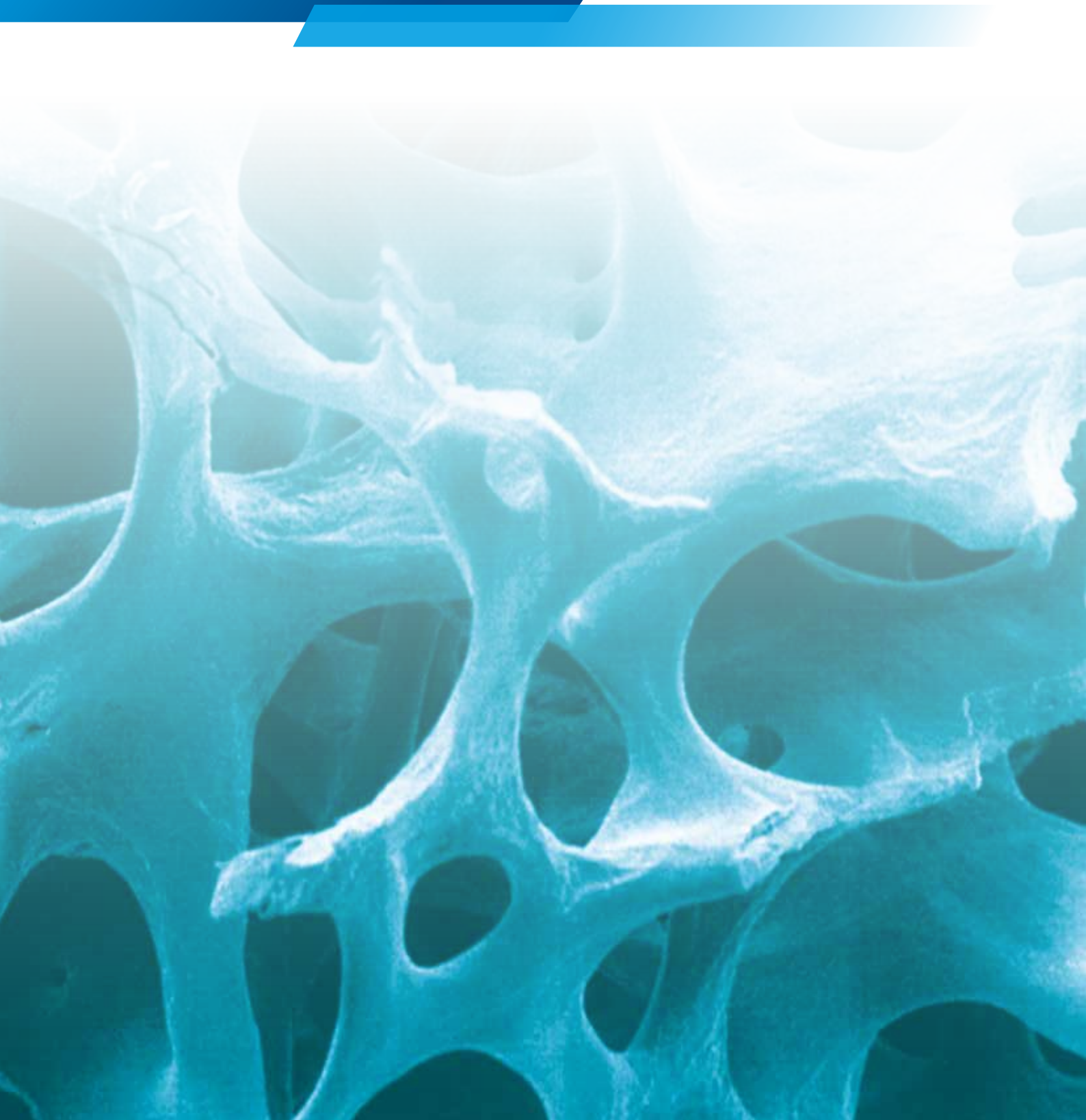


Table of Contents

Ridge Augmentation Using Allogenic Bone Blocks

Page

CASE 1	Lateral Onlay Graft Site [21]	4	
HIGHLIGHT	CASE 2	Lateral Onlay Graft Site [21-22]	6
	CASE 3	Lateral Onlay Graft Site [34-37]	8
HIGHLIGHT	CASE 4	Lateral Onlay Graft Site [33-36], Histological Analysis	10
	CASE 5	Vertical Onlay Graft With Simultaneous Sinus Lift Site [14-16]	12
	CASE 6	Lateral Onlay Graft Site [21]	14
	LITERATURE REVIEW	18
	Vertical grafting with Puros® Allograft Bone Blocks compared to xenogeneic material.....	18	
	Augmentation Using Puros Allograft Bone Blocks.....	19	
	BIBLIOGRAPHY	20

Ridge Augmentation Using Customized Allogenic Bone Blocks

CASE 1	Vertical Onlay Graft Site [45-47].....	22	
CASE 2	Lateral And Vertical Onlay Graft Site [21-22]	26	
CASE 3	Lateral And Vertical Onlay Graft Site [12-22]	28	
CASE 4	Vertical And Lateral Augmentation Sites [12-16] and [22-26]	32	
CASE 5	Vertical And Lateral Augmentation Sites [12-16] and [22-26]	36	
	DESIGN AND MANUFACTURE OF A PUROS ALLOGRAFT CUSTOMIZED BLOCK	40
	BIBLIOGRAPHY	41

Socket & Ridge Preservation

CASE 1	Flapless Procedure With Free Tissue Graft Site [21]	42	
CASE 2	Ridge Preservation After Multiple Extraction, Site [11-12]	44	
	LITERATURE REVIEW	46
	Grafting Of Extraction Sites With Puros Allograft Cancellous Particles Compared To Non-Grafted Sites	46	
	Grafting Of Extraction Sites With Puros Allograft Cancellous Particles Healing Period 3.5 Months Vs. 6 Months	47	
	BIBLIOGRAPHY	48

Treatments Using Particulate Bone Graft Substitute

CASE 1	Lateral Augmentation Prior To Implantation Site [21]	50	
HIGHLIGHT	CASE 2	Lateral Augmentation Prior To Implantation Site [44-47], Histomorphometric Analysis	52
	CASE 3	Implantation And Lateral Augmentation Site [12-22]	54
	CASE 4	Implantation And Lateral Augmentation Site [12-22]	56
	CASE 5	Delayed Implant Placement And Vertical Augmentation, Site [43]	58
	CASE 6	Lateral Augmentation Prior To Implantation Site [16] With Xenogeneic Bone Substitute, Histomorphometric Analysis	60
	CASE 7	Lateral Augmentation Prior To Implantation Site [34-37] With Xenogeneic Bone Substitute.....	64

LITERATURE REVIEW	66
Augmentation Of Facial Dehiscences On Implant Surfaces With Puros Allograft Particles Effect Of Covering With CopiOs® Pericardium Membrane	66
CASE SERIES	67
Lateral Augmentation Using Puros Allograft Particles, Histology And Histomorphometry	67
Defect Fill With CopiOs Xenograft Cancellous Particles Compared To Xenogeneic Materials	68
BIBLIOGRAPHY	69

Maxillary Sinus Floor Augmentation

CASE 1 Sinus Lift With Allogenic Bone Graft Site [15-17]	70
CASE 2 Histological And Histomorphometric Analysis Following Sinus Lift With Allogenic Bone Graft Site [25-26].....	72
CASE 3 Histological Analysis Following Sinus Lift With Xenogeneic Bone Substitute, Site [26-27]	76
LITERATURE REVIEW	80
Maxillary Sinus Augmentation With Puros Allograft Cancellous Particles Maxillary Sinus Augmentation With Bio-Oss®, BoneCeramic™ And Autologous Bone	80
Maxillary Sinus Augmentation With Puros Allograft Particles Maxillary Sinus Augmentation With Bio-Oss.....	81
BIBLIOGRAPHY	82

Regeneration Of Periodontal Defects

HIGHLIGHT

CASE 1 Tooth [14-16]	84
LITERATURE REVIEW	86
Treatment of periodontal defects using Puros Allograft Cancellous Particles	86
BIBLIOGRAPHY	87

Regeneration Of Peri-Implant Defects

CASE 1 Site [21-22]	88
BIBLIOGRAPHY	90
PUROS ALLOGRAFT – FACTS YOU SHOULD KNOW	91
REFERENCES	92
THE PROPRIETARY TUTOPLAST® PROCESS	93

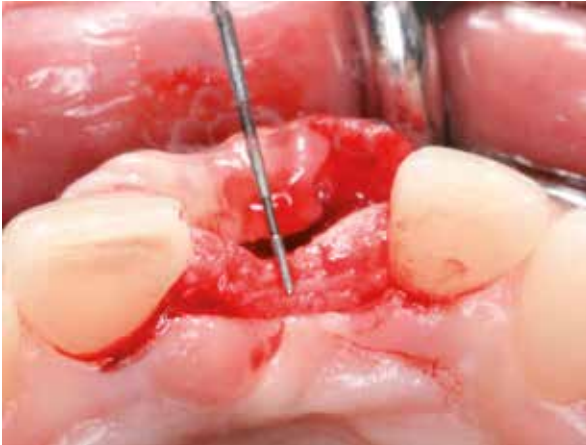CASE 1 Lateral Onlay Graft Site [21]

PRACTITIONER

Dr. O. Richter
Hamburg (Germany)

MATERIAL

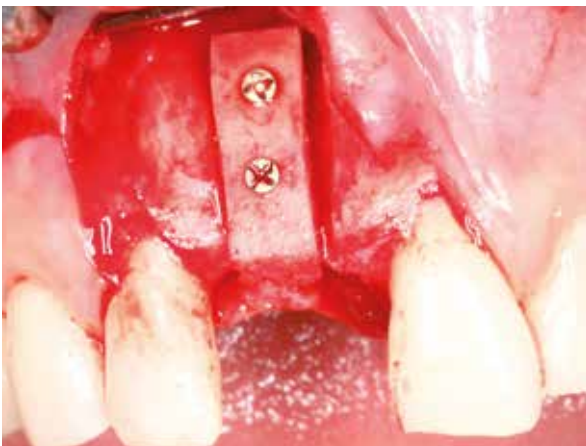- Puros Allograft Block 15 x 10 x 9 mm
- Puros Allograft Cancellous Particles 0.25–1 mm, 0.5 cc
- CopiOs Pericardium Membrane 30 x 40 mm



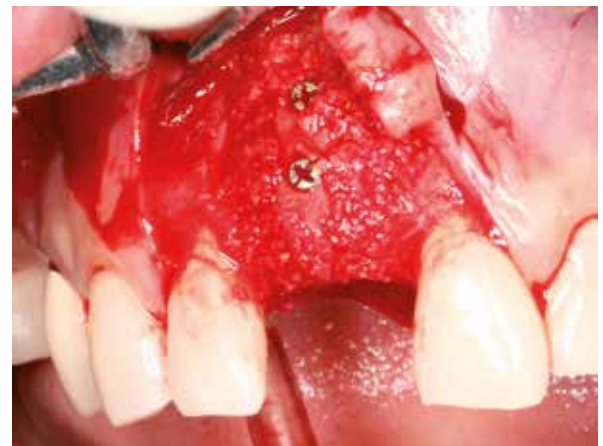1 Residual ridge width 3 mm.



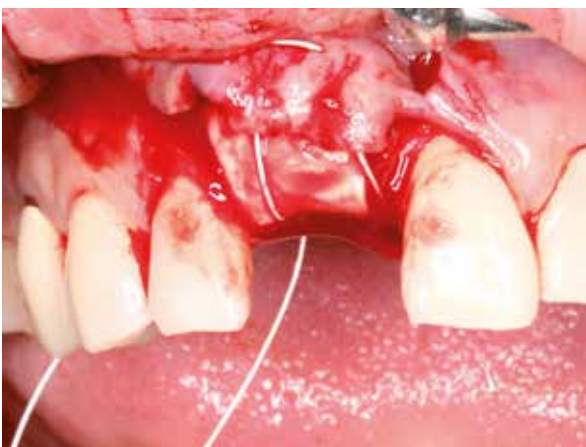
2 Shaping the Puros Allograft Block under saline solution using a circular saw.



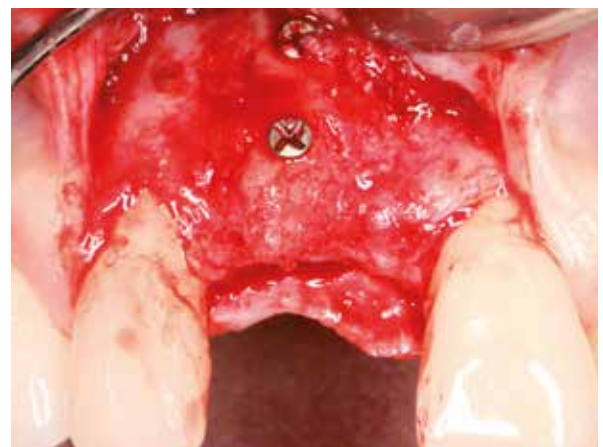
3 Puros Allograft Block in place.



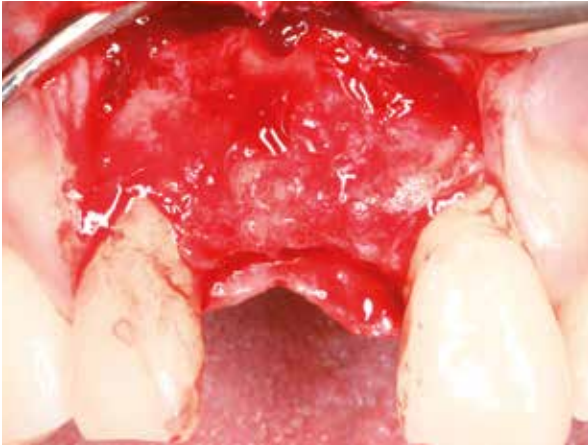
4 Filling inconsistencies in shape with Puros Allograft Cancellous Particles.



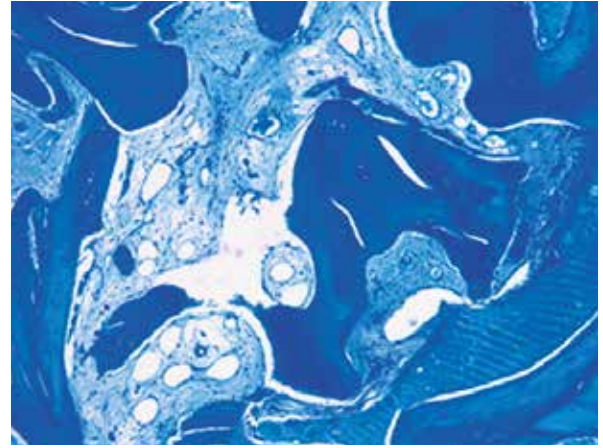
5 CopiOs Pericardium Membrane draped over bone graft prior to closure.



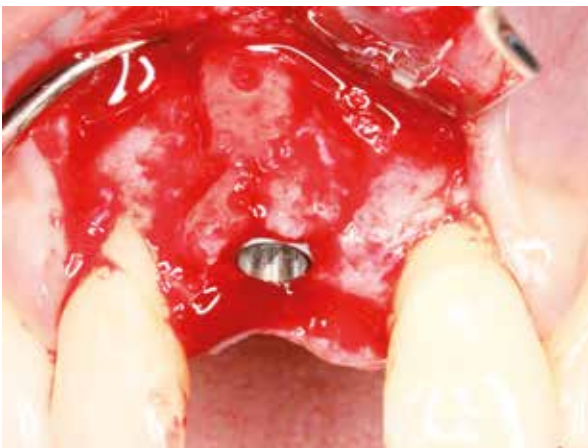
6 6-month post-op re-entry, minimal crestal resorption.



7 Situation following removal of osteosynthesis screws.



8 Histology, toluidine blue.



9 Implant in place.

Clinical photographs courtesy of Dr. O. Richter. Individual results may vary.

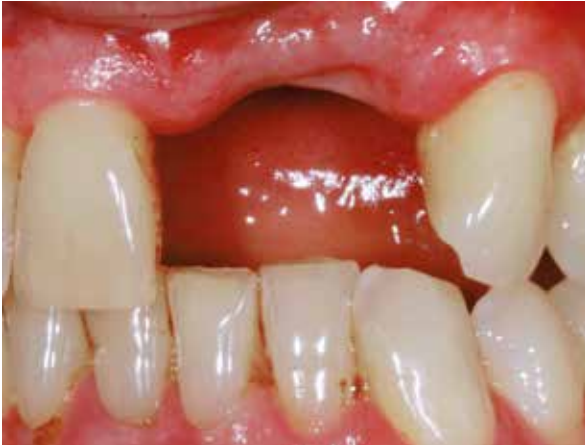CASE 2 Lateral Onlay Graft Site [21-22]

PRACTITIONERS

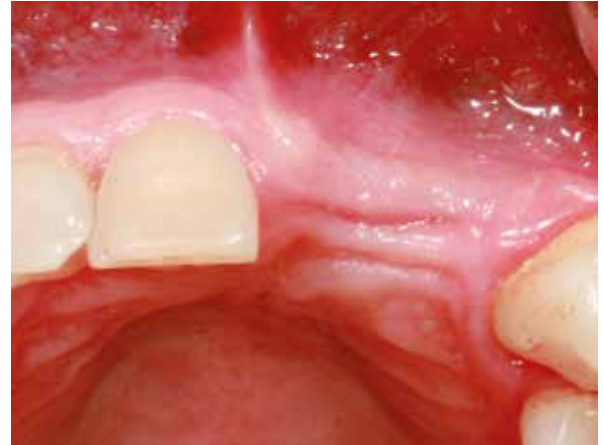PD Dr. Dr. K. K. Würzler
Dr. F. Will
Würzburg (Germany)

MATERIAL

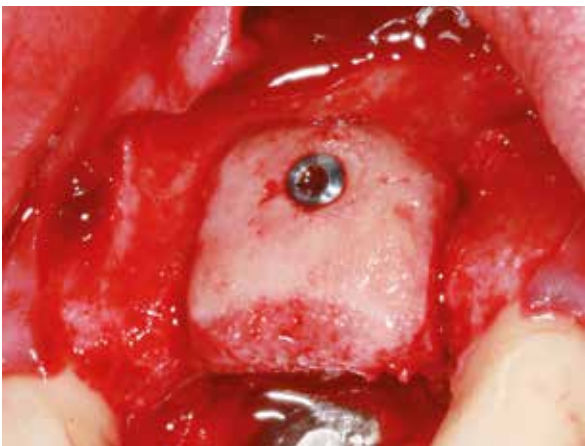
- Puros Allograft Block 15 x 15 x 9 mm
- Puros Allograft Cancellous Particles 0.25–1 mm, 1 cc
- CopiOs Pericardium Membrane 30 x 40 mm



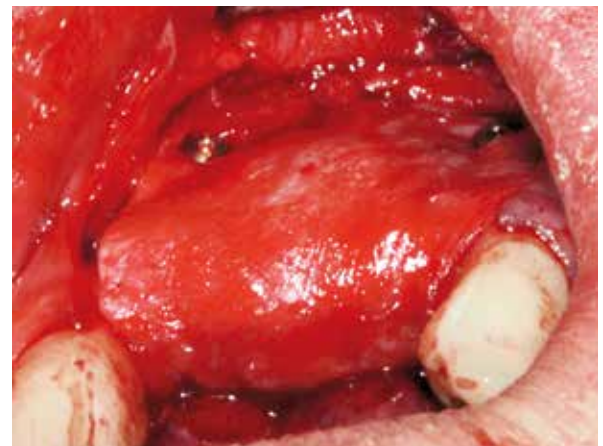1 Defect situation, lateral view.



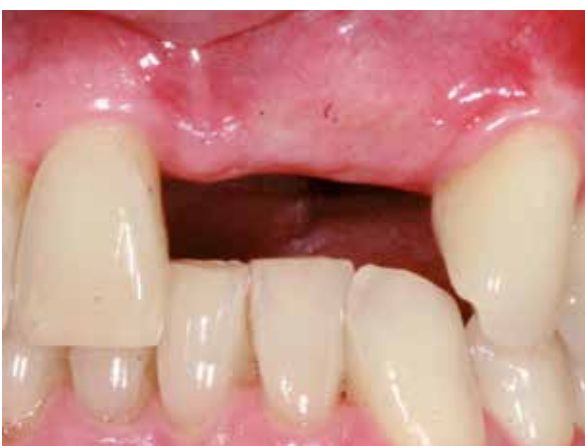2 Defect situation, occlusal view.



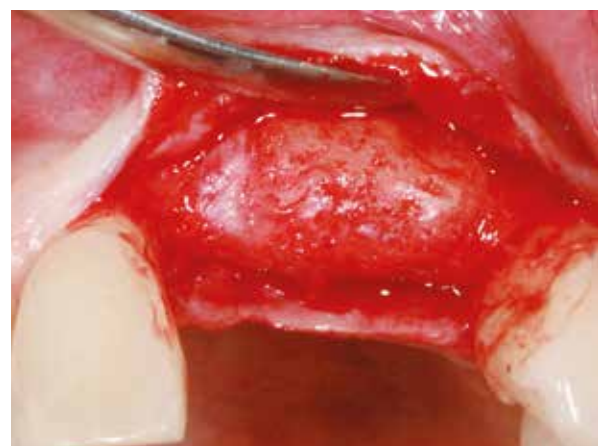
3 Puros Allograft Block in place.



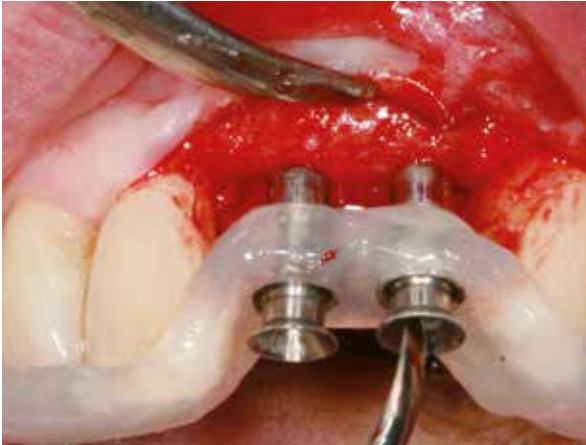
4 CopiOs Pericardium Membrane draped over bone graft prior to closure.



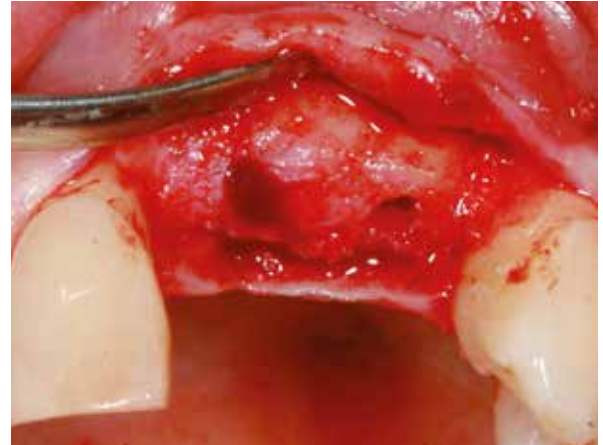
5 Soft tissue, 9 months post-operative.



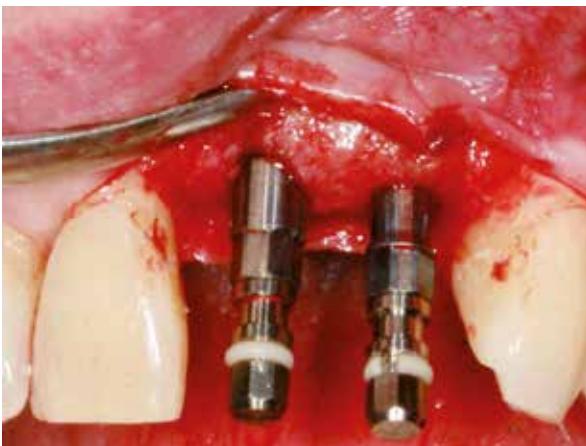
6 9-month post-op re-entry, no visible resorption.



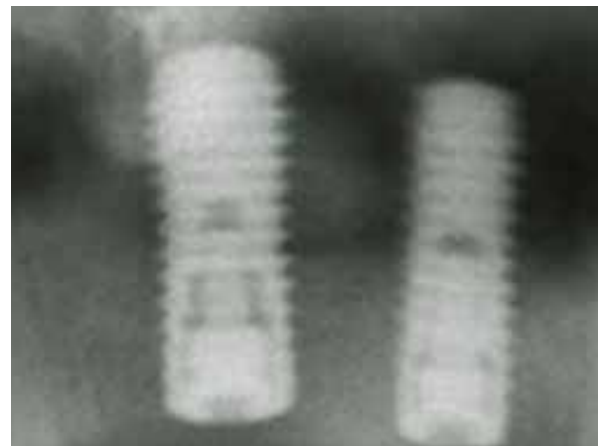
7 Surgical guide in place.



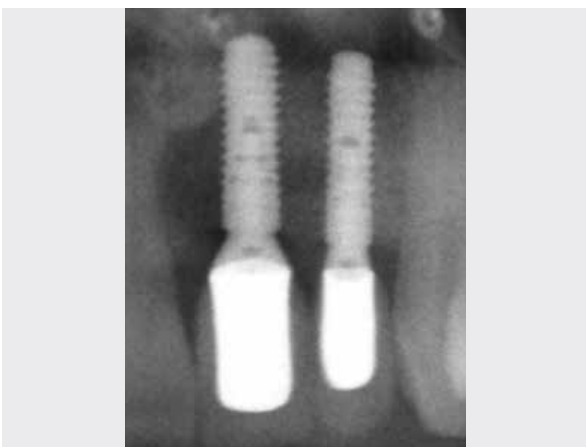8 Final osteotomies.



9 Implants in place.



10 Post-placement radiograph.



11 4-years follow-up radiograph. Note the stable bone conditions.

Clinical photographs courtesy of PD Dr. Dr. K. K. Würzler and Dr. F. Will. Individual results may vary.

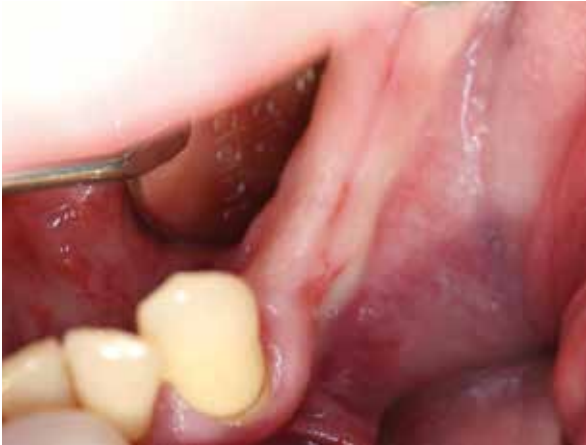CASE 3 Lateral Onlay Graft Site [34-37]

PRACTITIONER

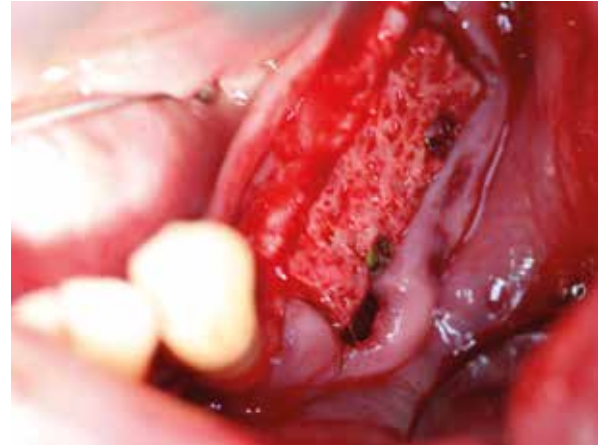R. Stutzki
Magdeburg (Germany)

MATERIAL

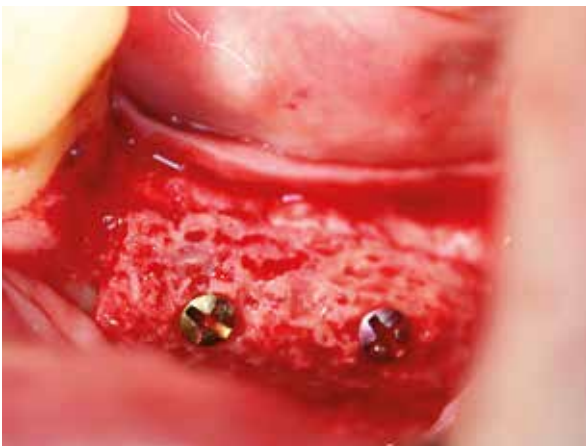- Puros Allograft Cancellous Block 10 x 10 x 20 mm
- Puros Allograft Cancellous Particles 1–2 mm, 1 cc
- CopiOs Pericardium Membrane 30 x 40 mm
- Tapered Screw-Vent® Implants



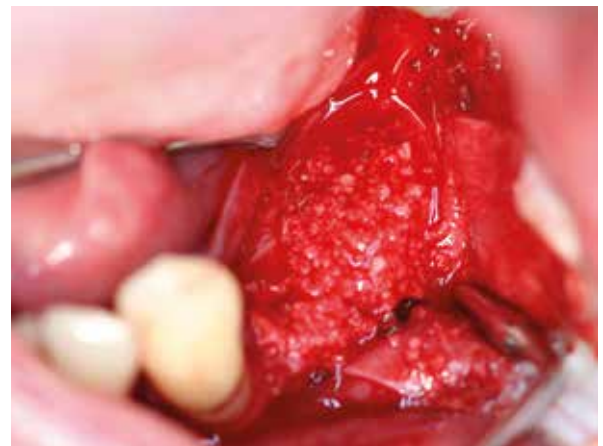1 Initial situation, narrow ridge left mandible.



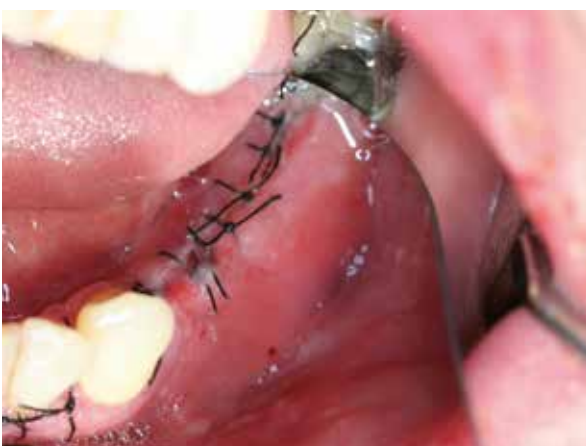2 Puros Allograft Cancellous Block in place, occlusal view.



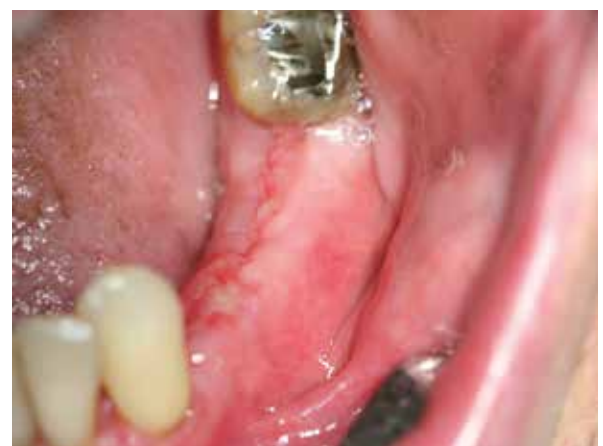3 Puros Allograft Cancellous Block in place, lateral view.



4 Puros Allograft Cancellous Particles placed around the block graft and covering with a CopiOs Pericardium Membrane.

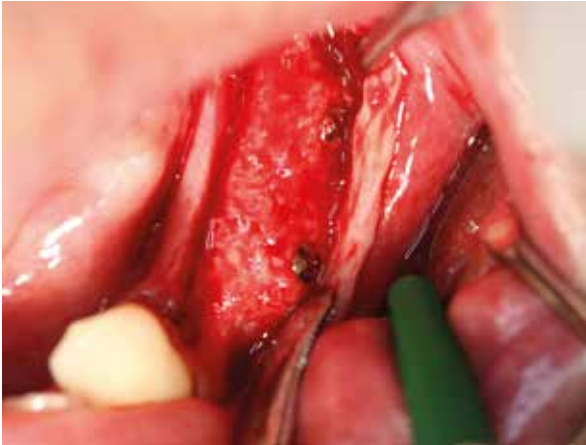

5 Wound closure.

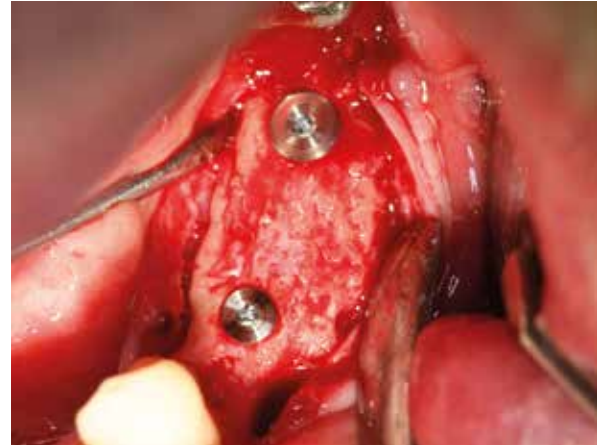

6 Soft tissue, 14 days post-operative.

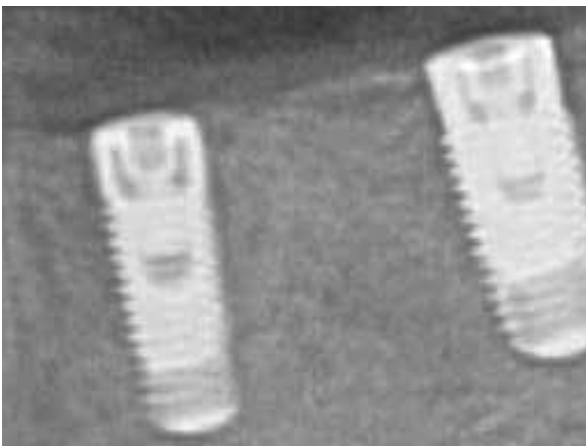
3 YEAR FOLLOW-UP



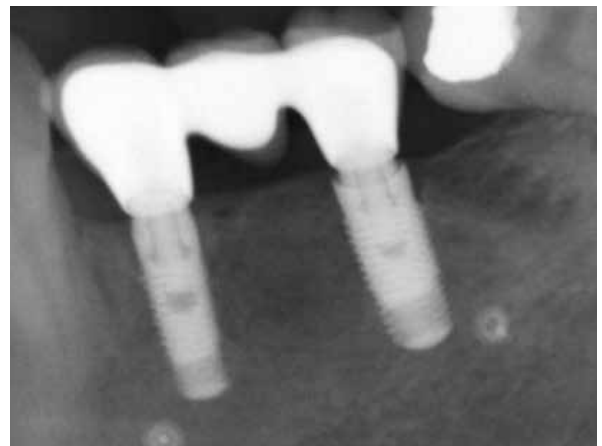7 6-month post-op re-entry, no resorption.



8 Tapered Screw-Vent Implants in place, occlusal view.



9 Final radiograph.



10 Radiograph taken 3 years post-placement. Note the stable bone conditions.

Clinical photographs courtesy of R. Stutzki. Individual results may vary.

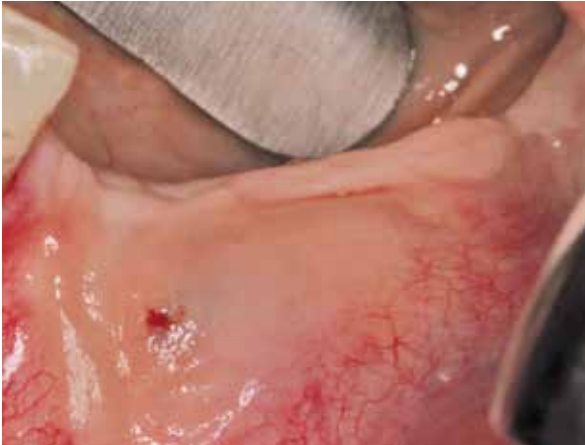CASE 4 Lateral Onlay Graft Site [33-36], Histological Analysis

PRACTITIONER

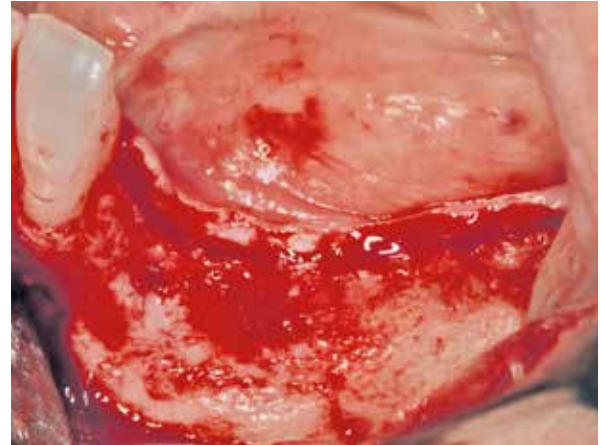Dr. W. Gutwerk
Aschaffenburg (Germany)

MATERIAL

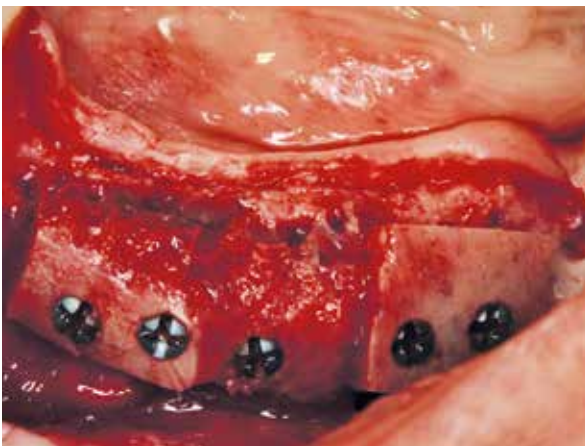
- Puros Allograft Block 15 x 15 x 9 mm
- Puros Allograft Cancellous Particles 0.25–1 mm, 1 cc



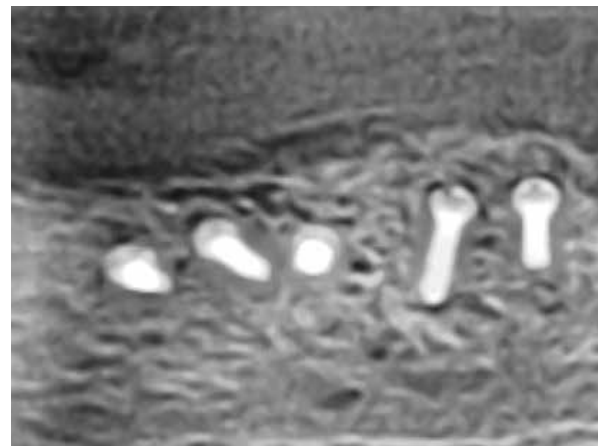
1 Initial situation, narrow ridge left mandible.



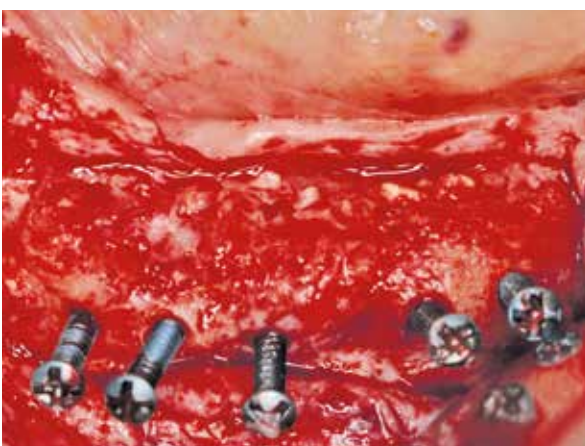2 Elevated flap, revealing reduced ridge width.



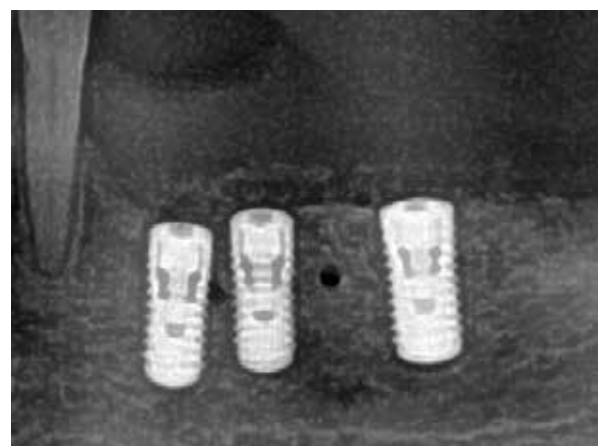
3 Puros Allograft Block in place.*



4 6-month post-operative radiograph.

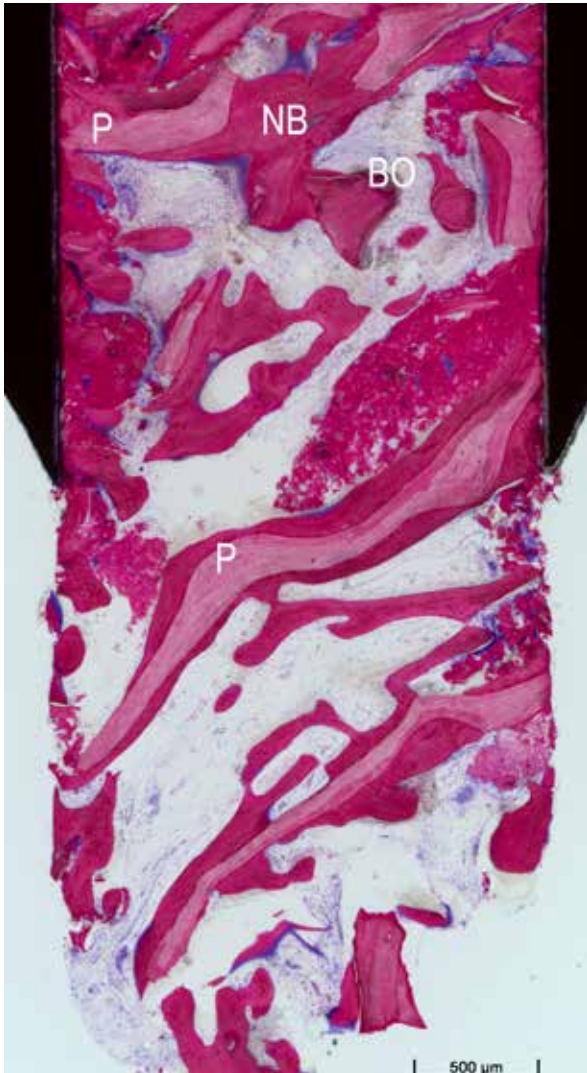


5 6-month post-op re-entry, reconstructed, ridge showing vital bone.

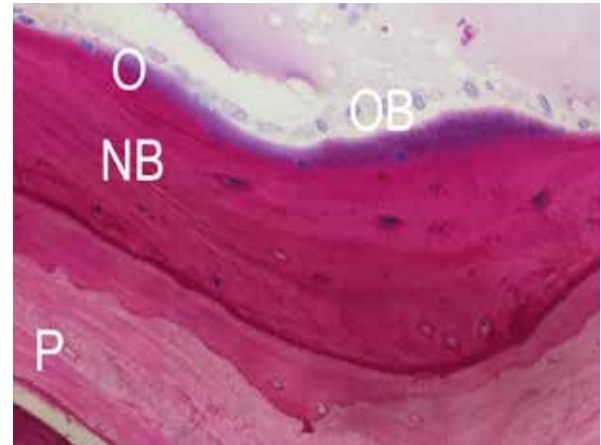


6 Radiograph after implant placement, note the mental foramen distal to site [35].

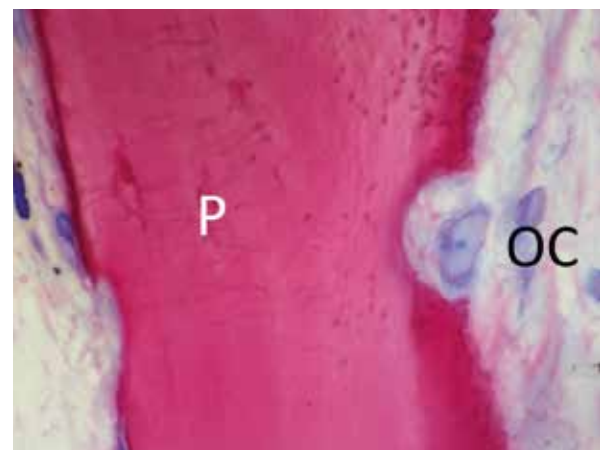
*Gaps grafted with a xenograft and covered with a non-absorbable membrane.



7 Histological cross-section (non-decalcified thin section) 50 fold: Healing time 6 months. Formation of vital, new bone (NB, mauve) and remaining Puros Block (P, reddish purple) and Bio-Oss (BO, grey) is clearly discernible.



8 Histological cross-section (non-decalcified thin section) 200 fold: Healing time 6 months. Osteoblasts (OB, blue) produce osteoid (O, purple rim). Maturation into newly formed lamellar bone (NB, mauve). Puros Block surface (P, reddish purple).



9 Histological cross-section (non-decalcified thin section) 200 fold: Healing time 6 months. Osteoclasts (OC, blue) forming a lacuna on the Puros Block surface (P, reddish purple).

CASE 5 Vertical Onlay Graft With Simultaneous Sinus Lift Site [14-16]

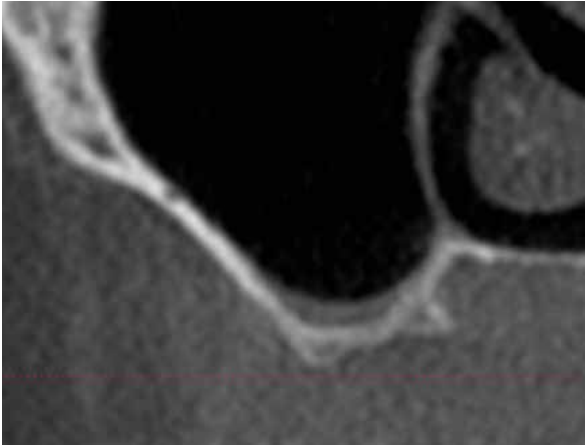
PRACTITIONERS

Dr. Dr. Dr. O. Blume
Dr. Dr. T. Müller-Hotop

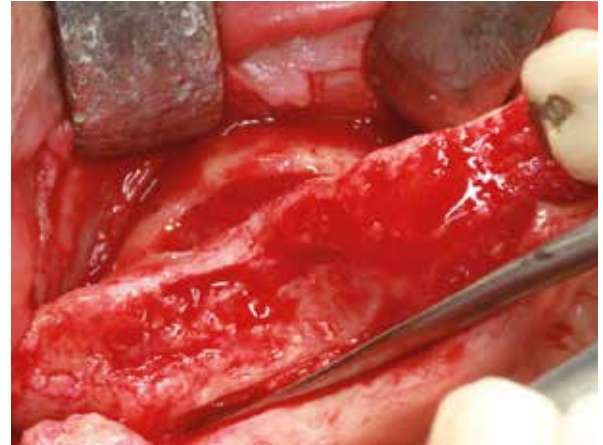
Dr. M. Back
Munich (Germany)

MATERIAL

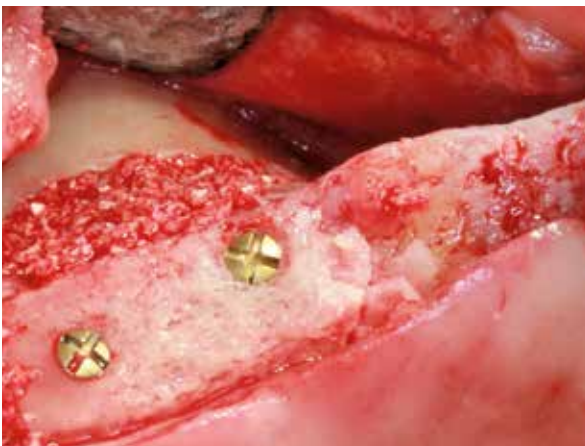- Puros Allograft Block 15 x 15 x 9 mm
- Puros Allograft Cancellous Particles 0.25–1 mm, 2 cc



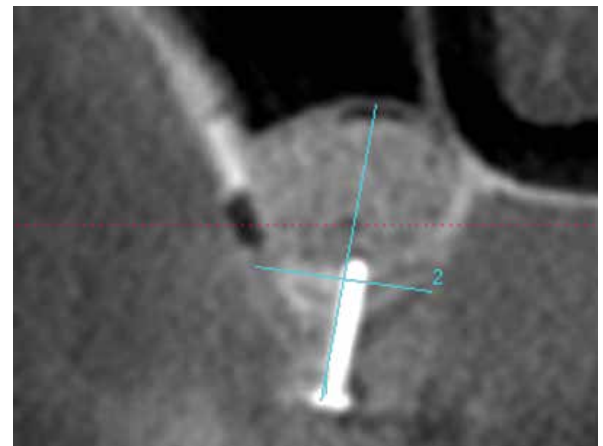
1 Initial situation, CBCT scan showing thin sinus floor.



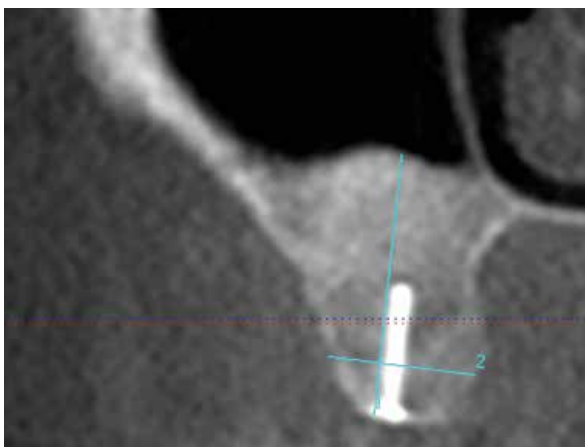
2 Initial situation, occlusal view, lateral window for sinus lift.



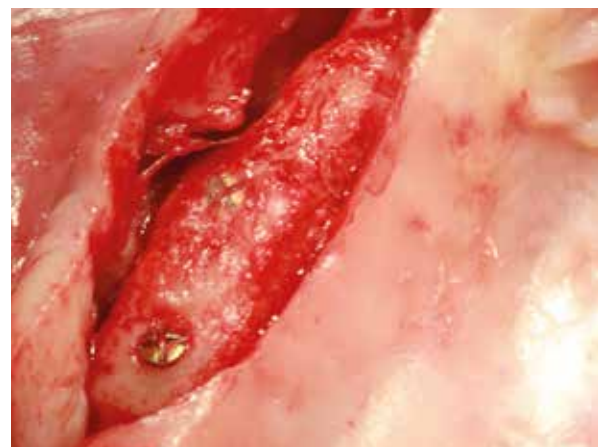3 Puros Allograft Block in place, inconsistencies in shape filled with Puros Allograft Cancellous Particles.



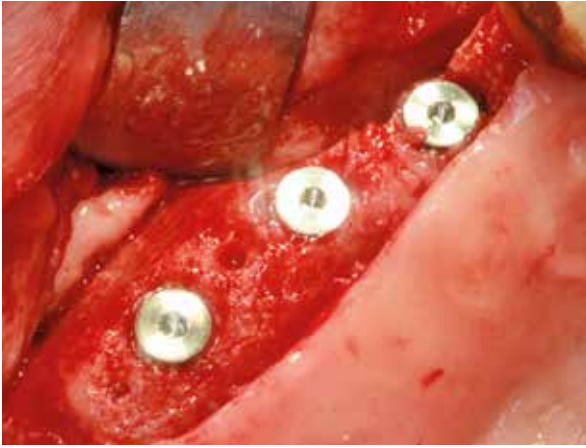
4 Post-augmentation CBCT scan.



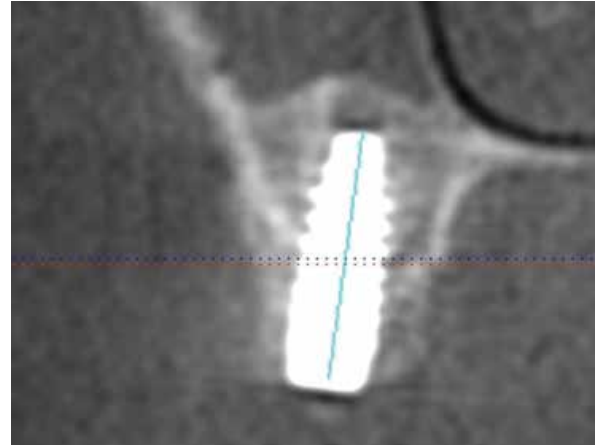
5 CBCT scan 7 months after augmentation.



6 7-month post-op re-entry, no resorption.



7 Implant placement, occlusal view.



8 Final CBCT scan.

Clinical photographs courtesy of Dr. Dr. Dr. O. Blume, Dr. Dr. T. Müller-Hotop, Dr. M. Back. Individual results may vary.

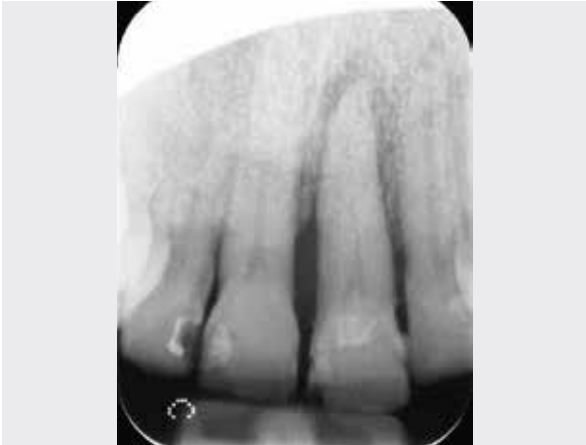CASE 6 Lateral Onlay Graft Site [21]

PRACTITIONER

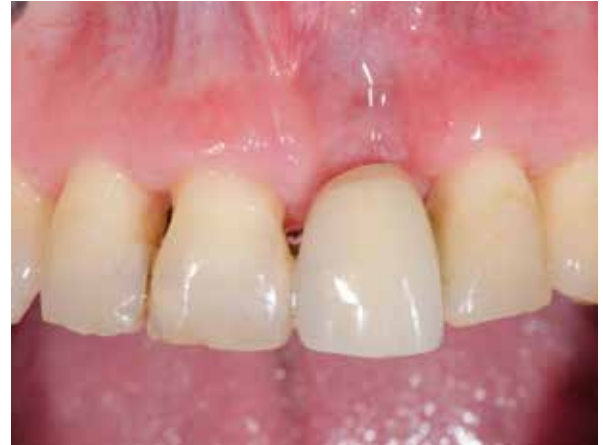Dr. M. Hinze
Gräfelfing (Germany)

MATERIAL

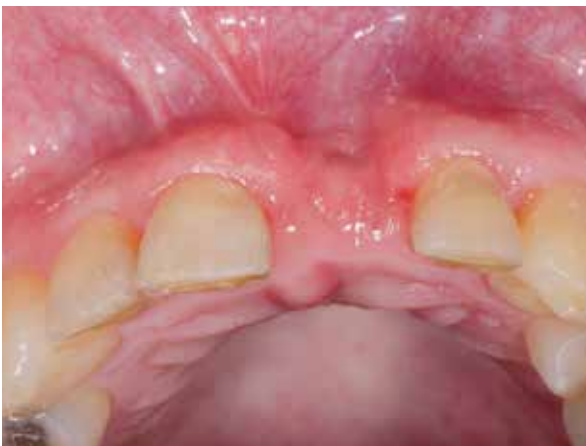- Puros Allograft Cancellous Block 10 x 10 x 20 mm
- CopiOs Pericardium Membrane 20 x 30 mm



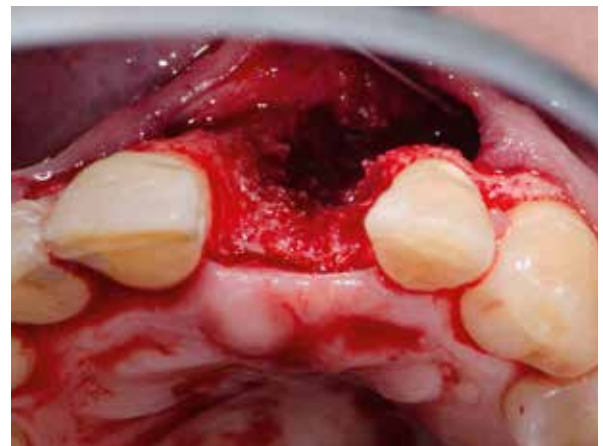1 Initial situation tooth [21] needs to be removed.



2 Volume deficit, facial view.



3 Volume deficit, occlusal view.



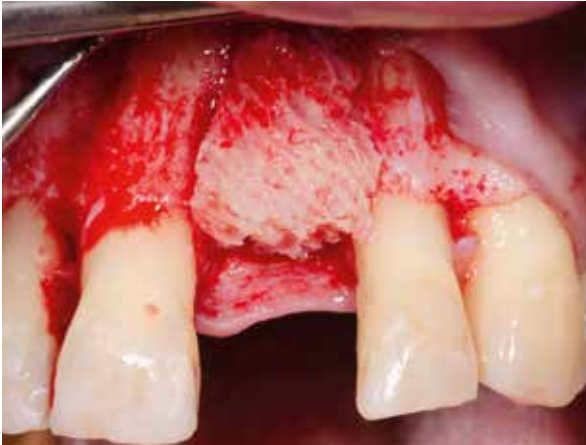4 Surgical site, large bony defect.



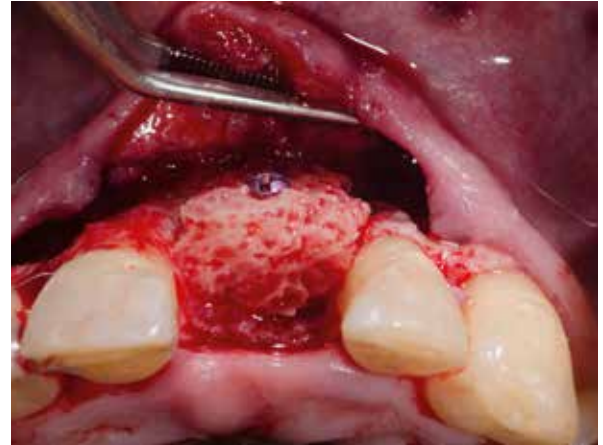
5 Puros Allograft Cancellous Block and CopiOs Pericardium Membrane.



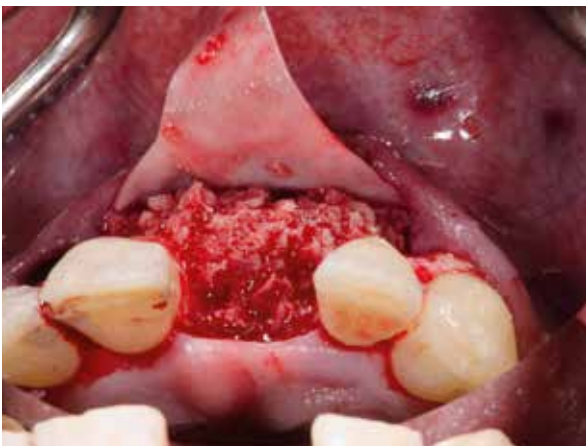6 Rehydration of Puros Block in a syringe.



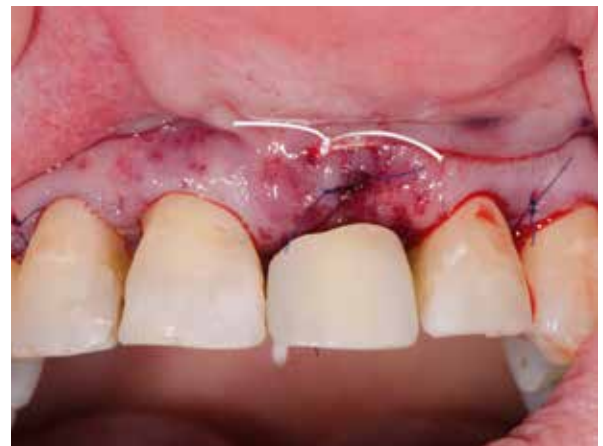7 Puros Allograft Cancellous Block in place, lateral view.



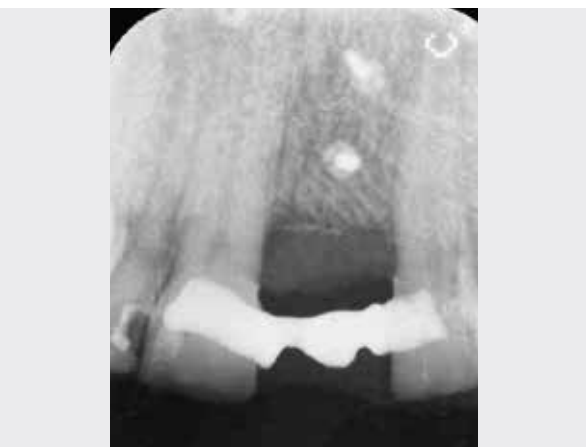8 Fixed Puros Allograft Cancellous Block in place, occlusal view.



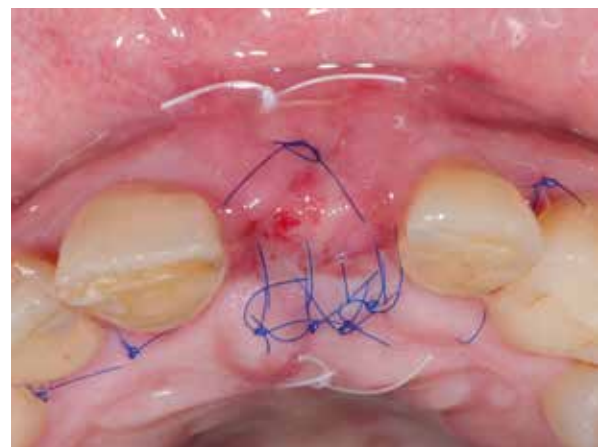
9 Inconsistencies in shape filled with Allograft Particles and covered with a CopiOs Pericardium Membrane.



10 Wound closure and provisional restoration.



11 Post-operative radiograph.



12 Soft tissue, 3 days post-op.

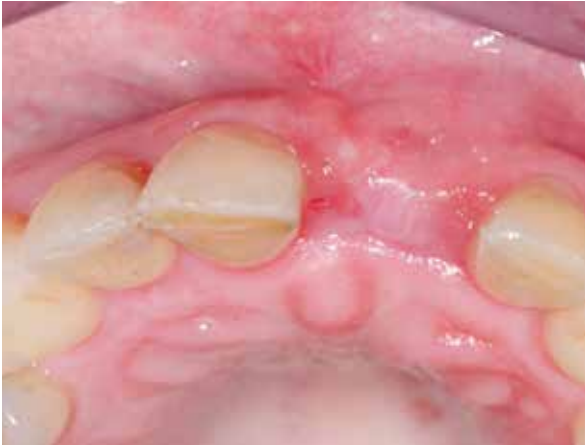CASE 6 Lateral Onlay Graft Site [21]

PRACTITIONER

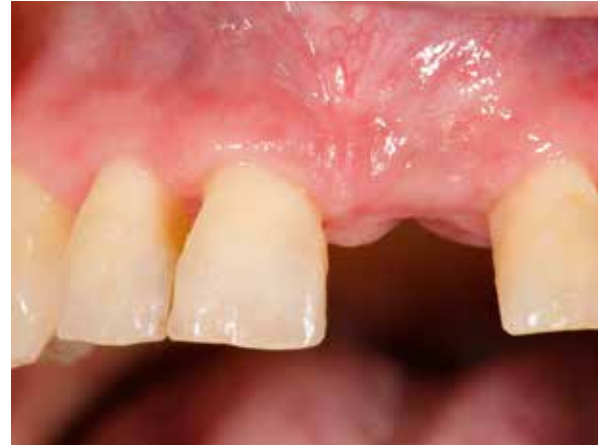Dr. M. Hinze
Gräfelfing (Germany)

MATERIAL

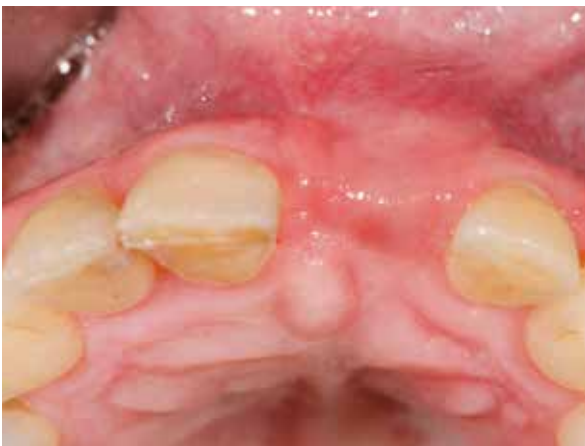- Puros Allograft Cancellous Block 10 x 10 x 20 mm
- CopiOs Pericardium Membrane 20 x 30 mm



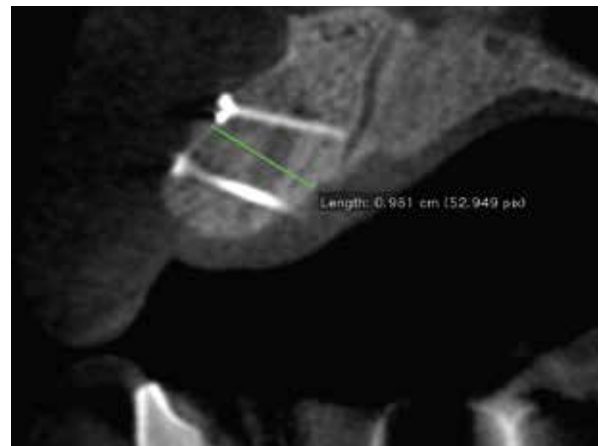13 Soft-tissue, 15 days post-op.



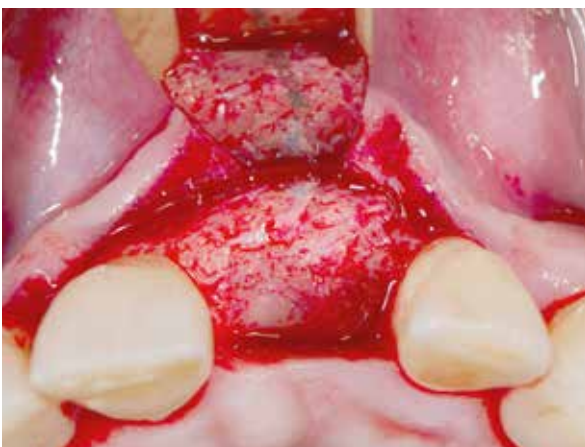14 Soft-tissue, 3 months post-op.



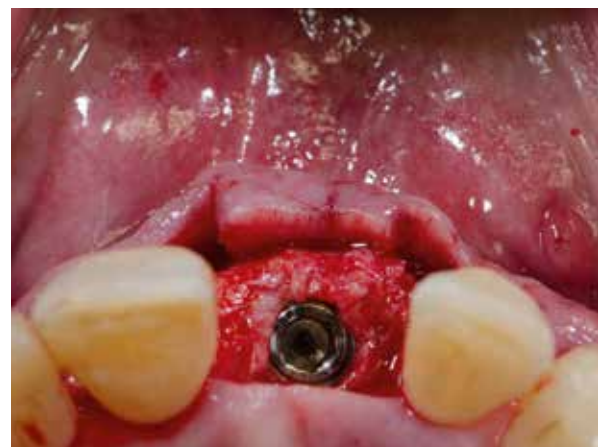15 Tissue contours, 3 months post-op.



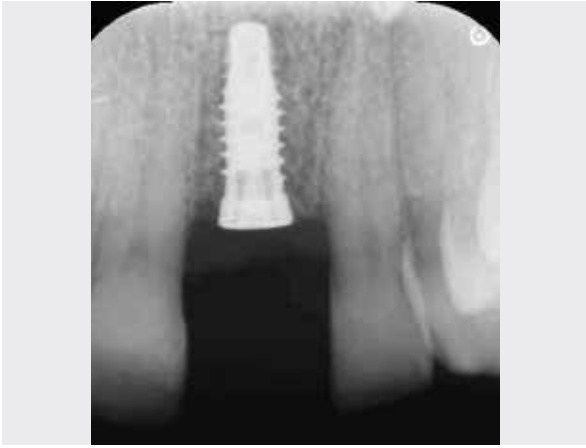16 3D diagnostics, 7-months post-op, no resorption detected.



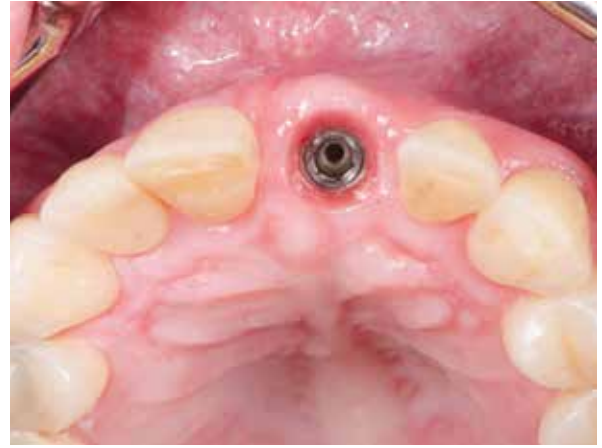
17 Re-entry 7-months post-op, screw head in tight contact with bone.



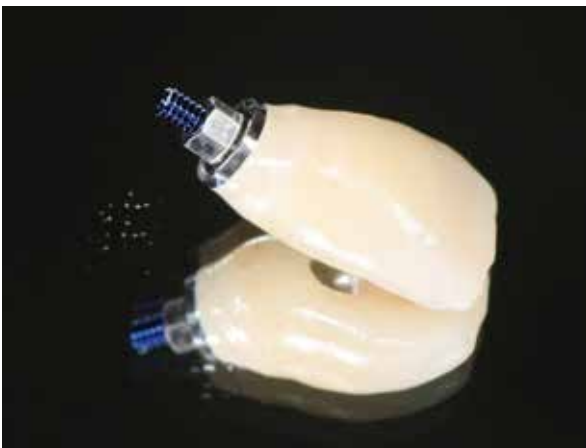
18 Implant in place.



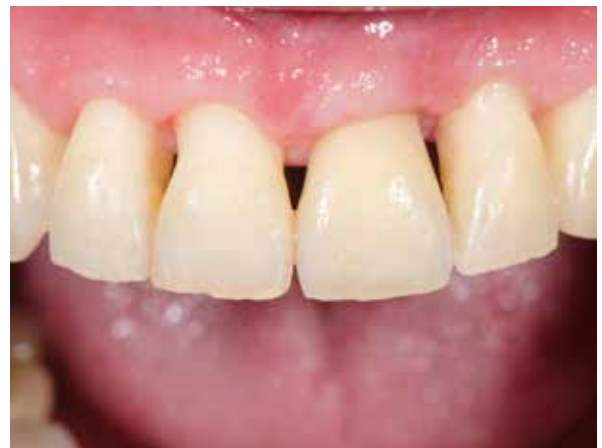19 Radiograph taken after implant placement.



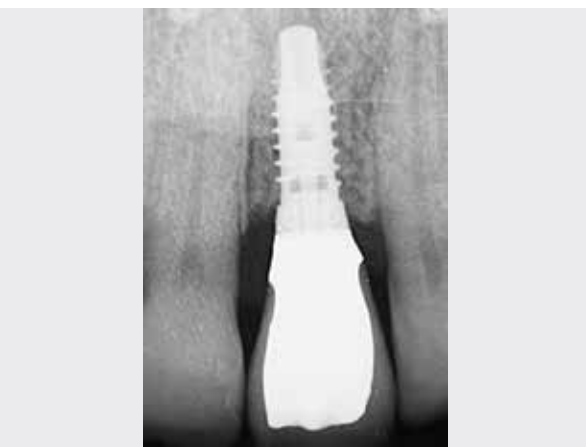20 Well-shaped soft tissue.



21 Single tooth crown.



22 Final aesthetic restoration 15 months after augmentation.



23 Final radiograph.

Clinical photographs courtesy of Dr. H. Hinze. Individual results may vary.

PROSPECTIVE TRIAL

Vertical grafting with Puros Allograft Bone Blocks compared to xenogeneic material

Kim Sj et al. Effect of bone block graft with rh-BMP2 on vertical bone augmentation. Int J Oral Maxillofac Surg (2010) 39:883-888.

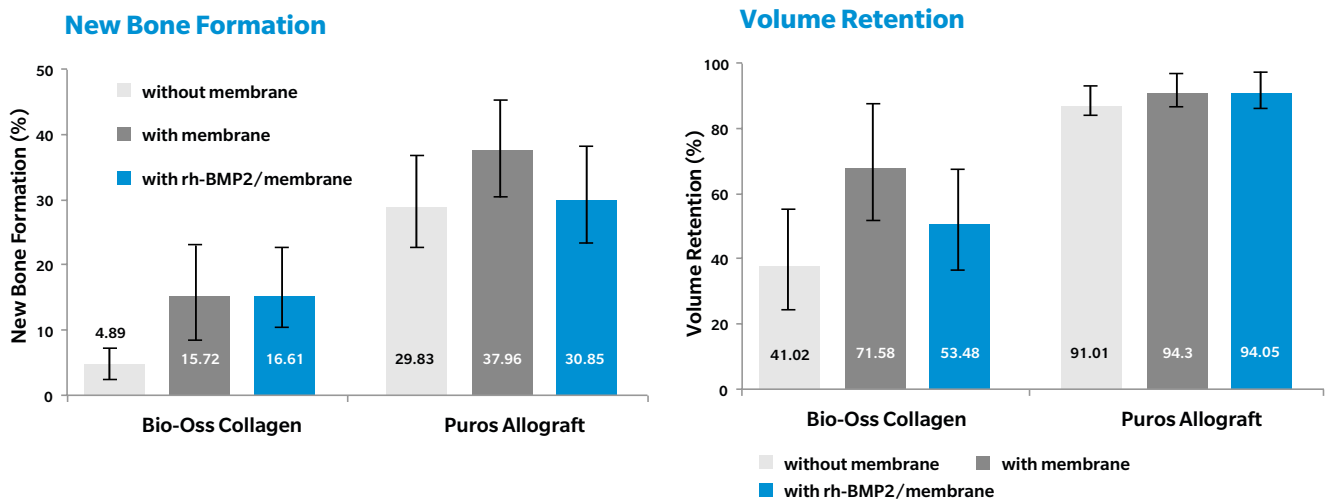
Study Design

Animal experiment on rabbits (white New Zealands), n=15. Formed defect (inlay diameter 6 mm, depth 1 mm) in calvarium and vertical augmentation with bone blocks (diameter 6 mm, height 4 mm) (I) without membrane covering, (II) with membrane covering (PTFE barrier membrane) and (III) after grafting with rh-BMP2 and membrane covering. Histological analysis after healing period of three months.

Results

Compared with the Bio-Oss Collagen groups, new bone formation was significantly higher in the **Puros Allograft groups**. New bone formation was greater in bone blocks covered with a membrane than blocks without a membrane in both groups. **Volume maintainance in the Puros Allograft groups** was >90%, with less resorption during healing compared to the Bio-Oss collagen groups. For vertical augmentation no additional benefit is observed either in new bone formation or volume preservation by adding rh-BMP2.

Conclusion



Vertical augmentation with Puros Allograft Blocks has shown excellent results with respect to new bone formation and volume retention.

CASE SERIES

Augmentation Using Puros Allograft Bone Blocks

Keith JD et al. Clinical and histologic evaluation of a mineralized block allograft: Results from the developmental period (2001–2004). Int J Periodont Rest (2006) 26:321-327.

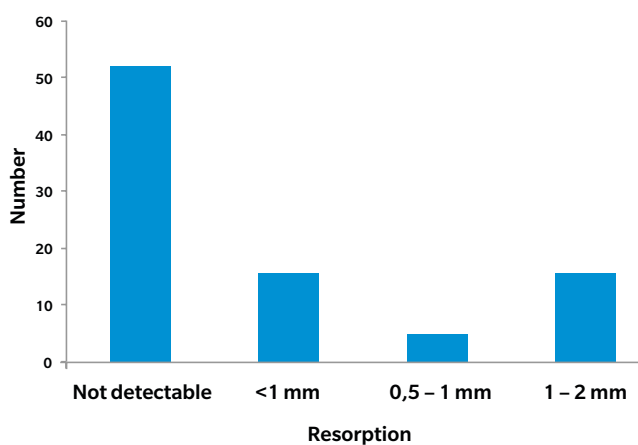
Study Design

73 patients with 82 defects were treated with Puros Allograft Bone Blocks. The allograft blocks were covered with a collagen membrane and the resorption behavior during the healing period has been studied. After a 4–6-month healing period the patients have been treated with Tapered Screw-Vent Implants. There is a three-year follow-up period. Histological analysis of regenerated allograft blocks after a 6-month healing period.

Results

During the 12-month follow-up, 93% of inserted blocks survived. The histological analysis revealed rapid incorporation of the Puros Block Allografts accompanied by active new bone formation on the block surface. In **69%** of the blocks **NO RESORPTIONS** were observed, and in just 31% minor resorptions around the osteosynthesis screws were observed. The implant survival rate was 99% (96/97) at three-year follow-up.

Resorption During Healing Time



Conclusion

Ridge augmentation with Puros Allograft Blocks **in combination with a collagen membrane** exhibits **low resorption rates** during the healing period. Further studies are required to investigate long-term outcomes.

1. Leonetti JA, Koup R. Localized maxillary ridge augmentation with a block allograft for dental implant placement: case reports. *Implant Dent* (2003) 12:217-26.
2. Keith JD. Localized ridge augmentation with a block allograft followed by secondary implant placement: A case report. *Int. J Periodont Rest Dent* (2004) 24:11-17.
3. Minichetti JC, D'amore JC, Hong AY, Cleveland DB. Human histologic analysis of mineralized bone allograft (Puros) placement before implant surgery. *J Oral Implantol* (2004) 30:74-82.
4. Petrungraro PS, Amar S. Localized ridge augmentation with allogenic block grafts prior to implant placement: case reports and histologic evaluations. *Implant Dent* (2005) 14:139-48.
5. Schau I, Plöger M, Von Der Haar A. Blockaugmentation ohne Knochenentnahme. *Oralchirurgie Journal* (2005) 4:34-36.
6. Keith JD, Petrungraro P, Leonetti JA, Elwell CW, Zeren KJ, Caputo C, Nikitakis NG, Schopf C, Warner MM. Clinical and histologic evaluation of a mineralized block allograft: Results from the developmental period (2001-2004). *Int J Periodont Rest Dent* (2006) 26:321-327.
7. Plöger M, Schau I. Rekonstruktion von Kieferkammdefekten mittels allogener Spongiosa. *Implantologie Zeitung* (2006) 10:16-18.
8. Giray B, Meral G. Allogenic grafts in oral surgery: clinical findings and follow-up. *Journal of Hacettepe Faculty of Dentistry* (2007) 31:31-37.
9. Morelli T, Neiva R, Wang HL. Human histology of allogeneic block grafts for alveolar ridge augmentation: case report. *Int J Periodont Rest Dent* (2009) 29:649-56.
10. Plöger M, Schau I. Kieferkammaugmentation mit allogenen Knochenblöcken. *Journal for Continuing Dental Education* (2009) 12:242-249.
11. Kim SG, Park JS, Lim SC. Placement of implant after bone graft using J block allograft. *Implant Dent* (2010) 19:21-8.
12. Peleg M, Sawatari Y, Marx RN, Santoro J, Cohen J, Bejarano P, Malinin T. Use of corticocancellous allogeneic bone blocks for augmentation of alveolar bone defects. *Int J Oral Maxillofac Implants* (2010) 25:153-62.
13. Plöger M, Schau I. Allogener Knochenblock zur präimplantologischen Augmentation. *Journal for Continuing Dental Education* (2010) 13:84-88.
14. Kim SJ, Shin HS, Shin SW. Effect of bone block graft with rhBMP-2 on vertical bone augmentation. *Int J Oral Maxillofac Surg* (2010) 39:883-8.
15. Jacotti M, Wang HL, Fu JH, Zamboni G, Bernardello F. Ridge augmentation with mineralized block allografts: clinical and histological evaluation of 8 cases treated with the 3-dimensional block technique. *Implant Dent* (2012) 21:444-8.
16. Araujo PP, Oliveira KP, Montenegro SC, Carreiro AF, Silva JS, Germano AR. Block allograft for reconstruction of alveolar bone ridge in implantology: a systematic review. *Implant Dent* (2013) 22:304-8.
17. Schlee M, Dehner J-F, Baukloh K, Happe A, Seitz O, Sader R. Esthetic outcome of implant-based reconstructions in augmented bone: comparison of autologous and allogeneic bone block grafting with the pink esthetic score (PES). *Head & Face Medicine* (2014) 10:21.
18. Monje A, Picos MA, Chan HL, Suarez F, Gargallo-Albiol J, Hernandez-Alfaro F, Galindo-Moreno P, Wang HL. On the feasibility of utilizing allogeneic bone blocks for atrophic maxillary augmentation. *Biomed Res Int* (2014). Article ID 814578 doi:10.1155/2014/814578.
19. Leong DJ, Oh TJ, Benavides E, Al-Hezaimi K, Misch CE, Wang HL. Comparison between sandwich bone augmentation and allogenic block graft for vertical ridge augmentation in the posterior mandible. *Implant Dent* (2015) 24:4-12.
20. Laino L, Iezzi G, Piattelli A, Lo Muzio L, Cicciu M. Vertical ridge augmentation of the atrophic posterior mandible with sandwich technique: bone block from the chin area versus corticocancellous bone block allograft-clinical and histological prospective randomized controlled study. *Biomed Res Int* (2014). Article ID 982104 doi:10.1155/2014/982104.
21. Checchi V, Felice P. The inlay technique with an allograft block used for the rehabilitation of an atrophic posterior mandible: a case report. *Clinical Advances in Periodontics* (2015) 5:68-74.



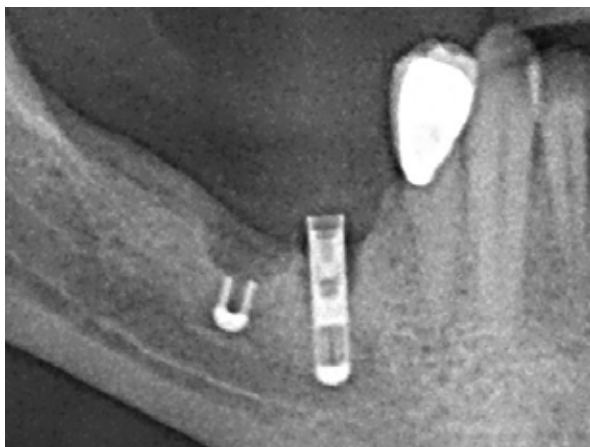
CASE 1 Vertical Onlay Graft Site [45-47]

PRACTITIONERS

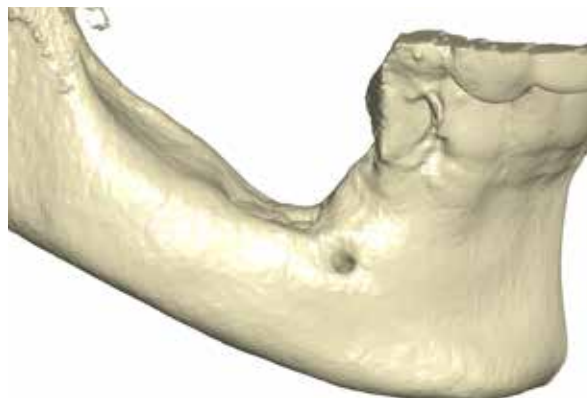
PD Dr. Dr. K. K. Würzler
Dr. F. Will
Würzburg (Germany)

MATERIAL

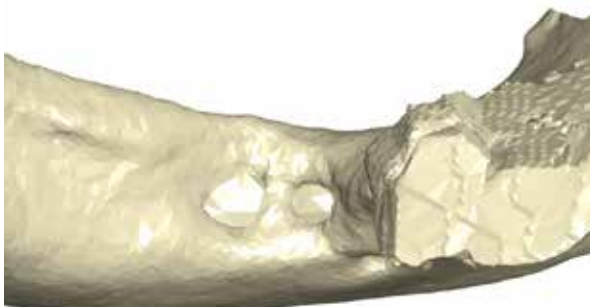
- Puros Allograft Customized Block
- Puros Allograft Cancellous Particles 0.25–1 mm, 0.5 cc
- CopiOs Pericardium Membrane 30 x 40 mm



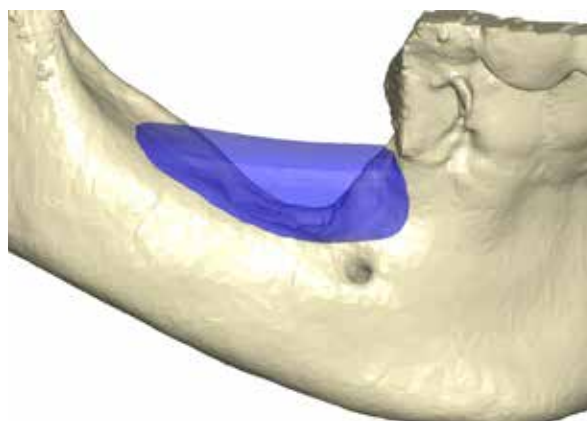
1 Initial situation; failed implants need to be removed.



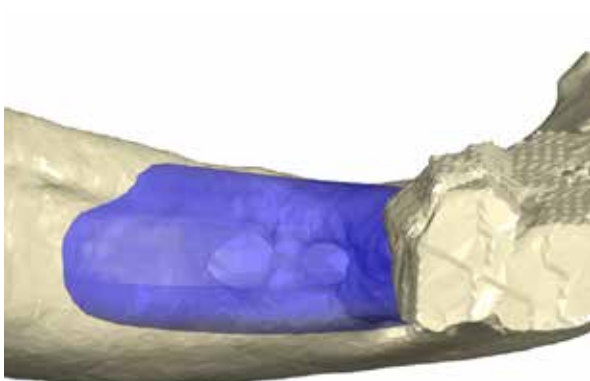
2 Three-dimensional reconstruction of the defect, lateral view.



3 Three-dimensional reconstruction of the defect, occlusal view.



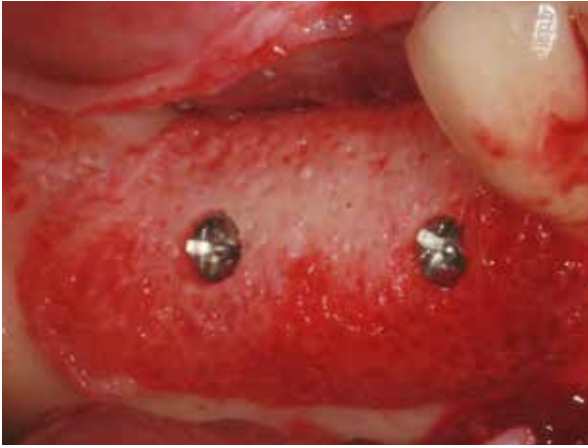
4 Designed bone block, lateral view.



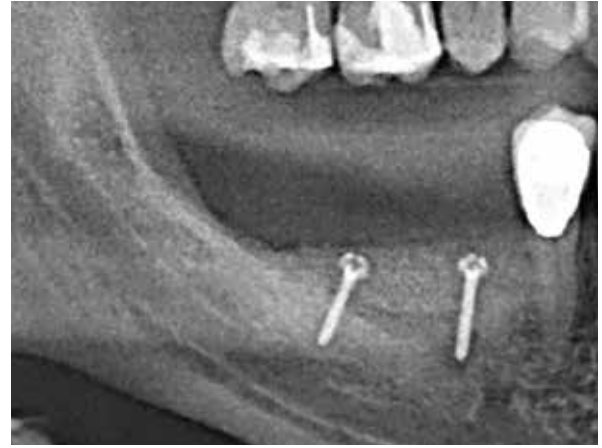
5 Designed bone block, occlusal view.



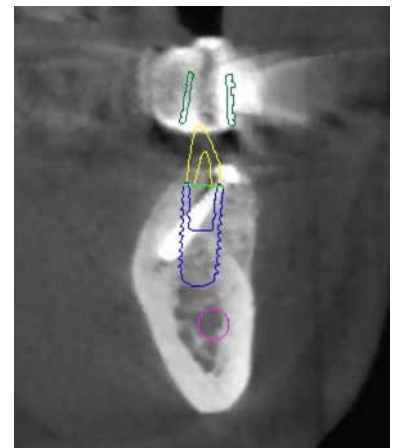
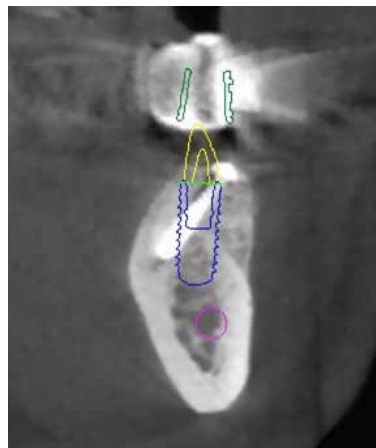
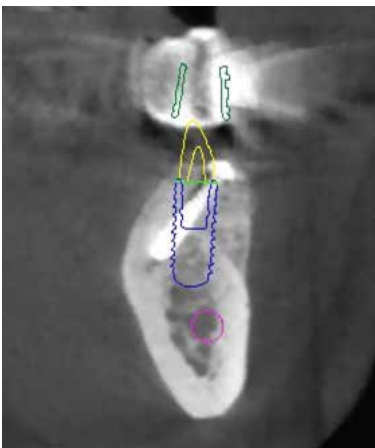
6 Milled Puros Allograft Customized Block.



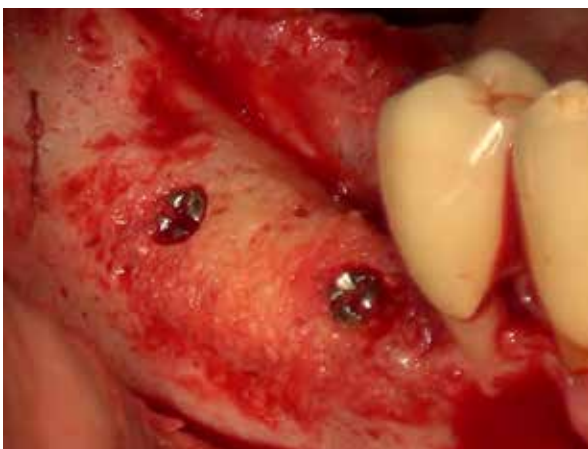
7 Fixed bone block placed.



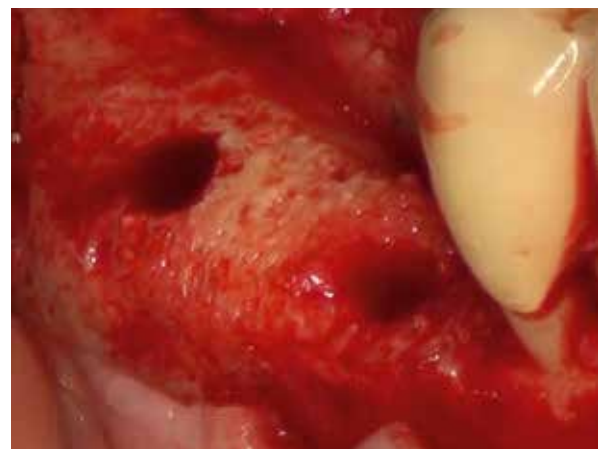8 Radiograph post-operative.



9 3D diagnostics and implant planning, 6 months post-op.



10 Re-entry 6-months post-op, screws are in tight contact with bone.



11 Vital bone bed.

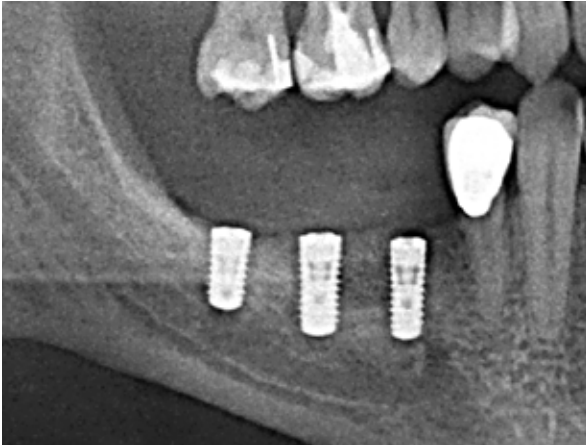CASE 1 Vertical Onlay Graft Site [45-47]

PRACTITIONERS

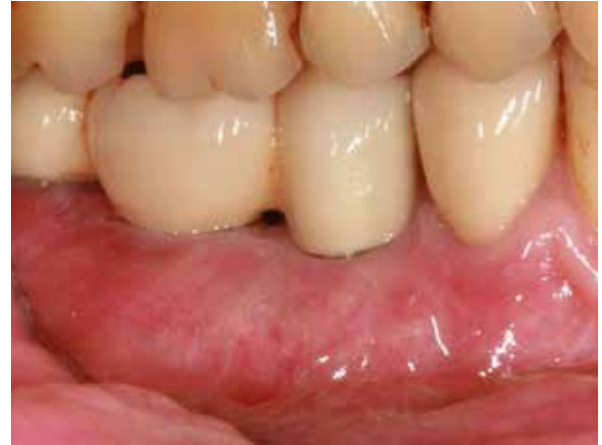PD Dr. Dr. K.K. Würzler
Dr. F. Will
Würzburg (Germany)

MATERIAL

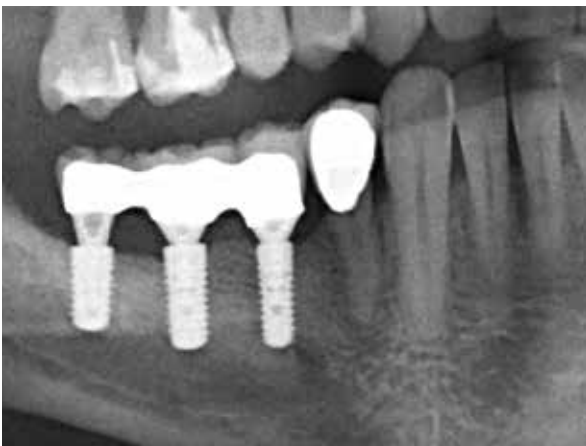- Puros Allograft Customized Block
- Puros Allograft Cancellous Particles 0.25–1 mm, 0.5 cc
- CopiOs Pericardium Membrane 30 x 40 mm



12 Radiograph after implant placement.



13 Final aesthetic restoration 10 months post-augmentation.



14 1-year follow up.

Clinical photographs courtesy of PD Dr. Dr. K. K. Würzler. Individual results may vary.



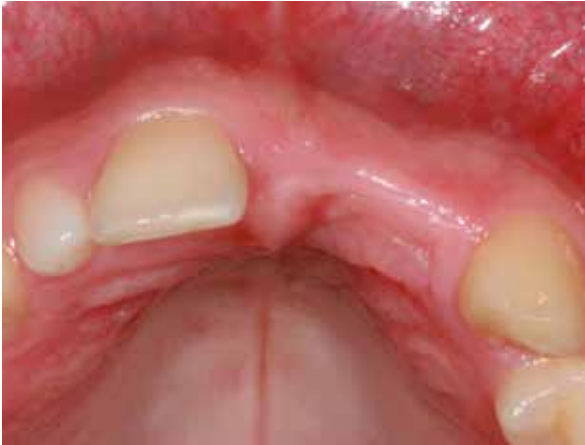CASE 2 Lateral And Vertical Only Graft Site [21-22]

PRACTITIONERS

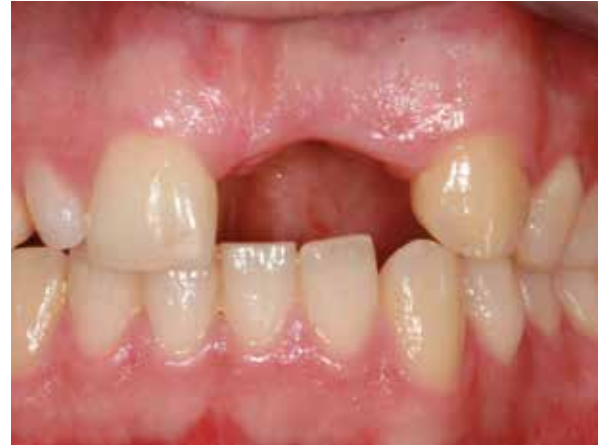PD Dr. Dr. K. K. Würzler
Dr. F. Will
Würzburg (Germany)

MATERIAL

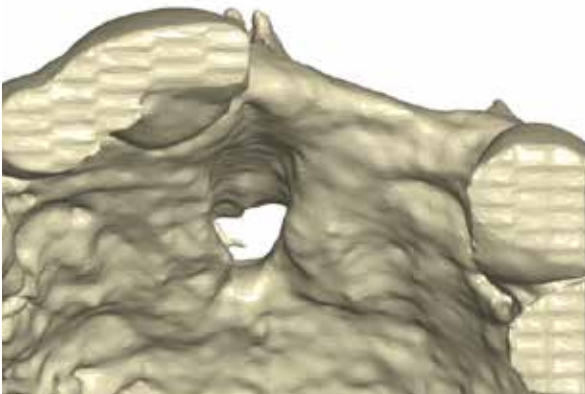
- Puros Allograft Customized Block
- Puros Allograft Cancellous Particles 0.25–1 mm, 0.5 cc
- CopiOs Pericardium Membrane 30 x 40 mm



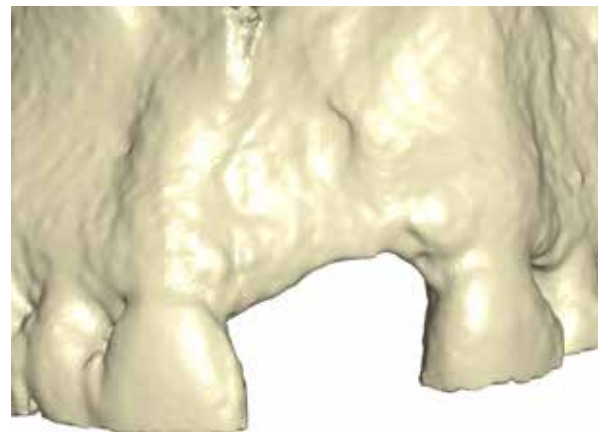
1 Initial situation; narrow ridge, occlusal view..



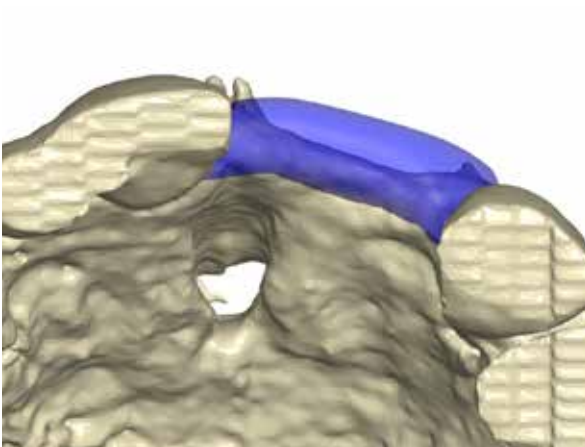
2 Initial situation; vertical deficiency, facial view..



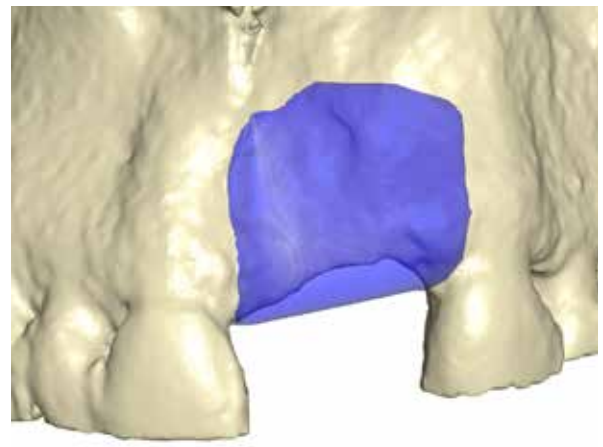
3 Three-dimensional reconstruction of the defect, occlusal view.



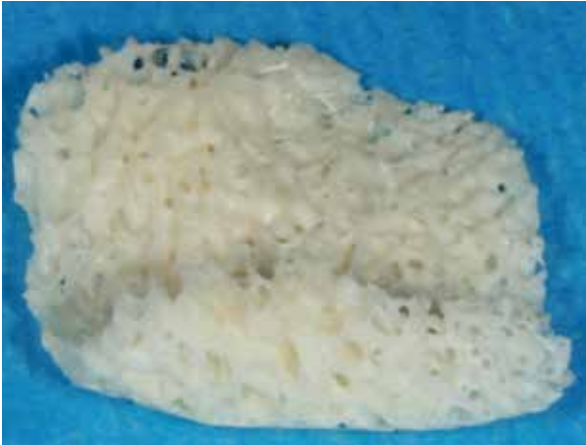4 Three-dimensional reconstruction of the defect, lateral view.



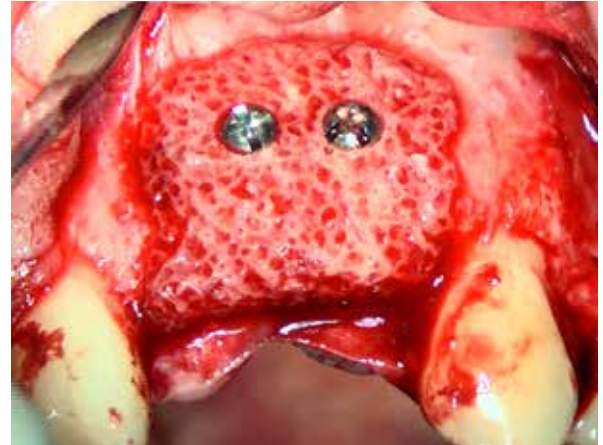
5 Designed bone block, occlusal view.



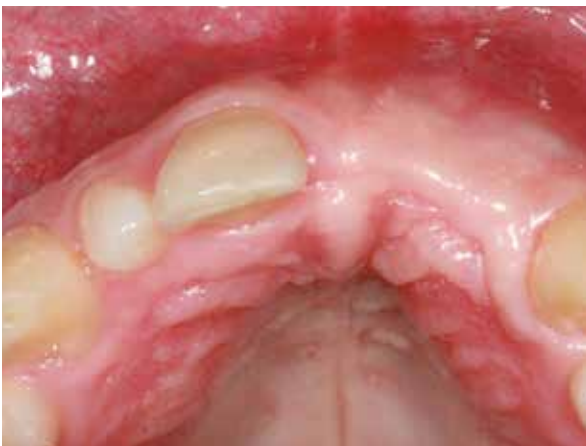6 Designed bone block, lateral view.



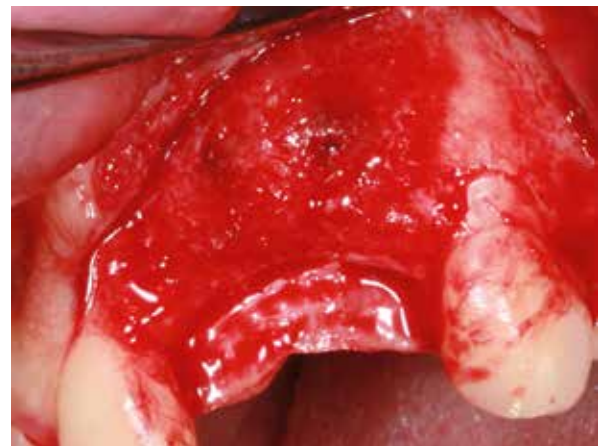
7 Milled Puros Allograft Customized Block.



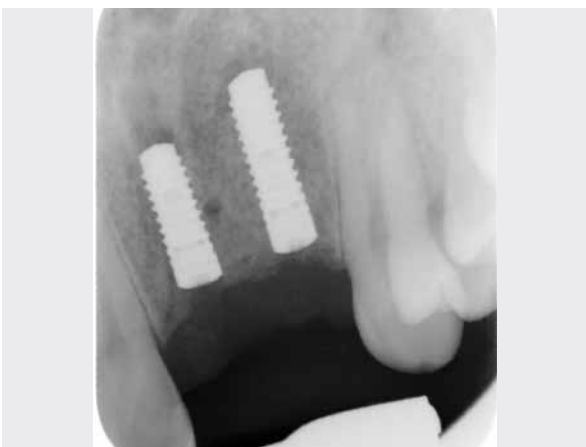8 Fixed bone block.



9 Soft tissue, 5-months post-operative.



10 Re-entry 6-months post-op, screw in tight contact with bone.



11 Radiograph taken after implant placement.

Clinical photographs courtesy of PD Dr. Dr. K. K. Würzler. Individual results may vary.

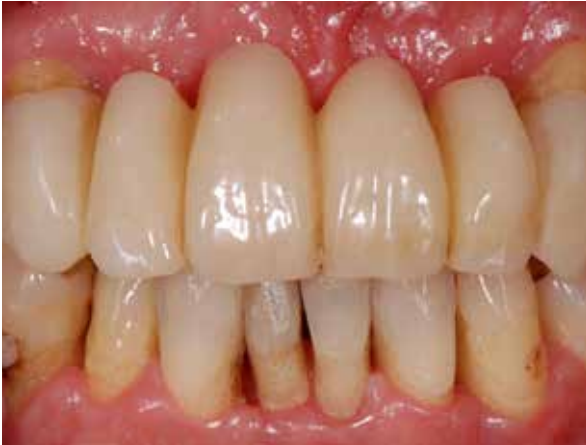CASE 3 Lateral And Vertical Onlay Graft Site [12-22]

PRACTITIONER

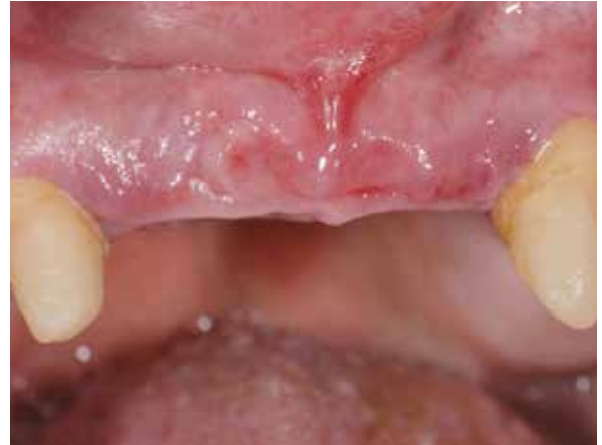Dr. K. Fischer
University of Witten/ Herdecke (Germany)

MATERIAL

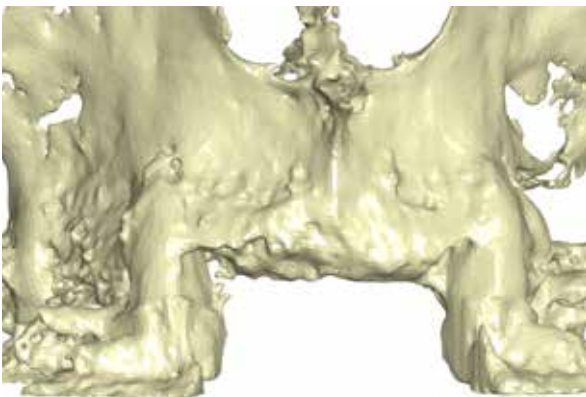
- Puros Allograft Customized Block
- Puros Allograft Cancellous Particles 0.25–1 mm, 0.5 cc



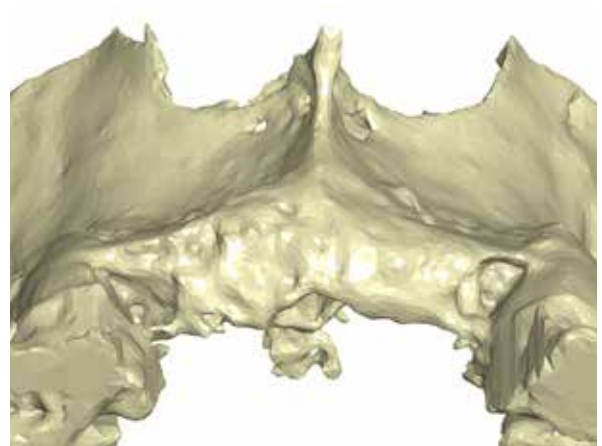
1 Initial situation anterior maxilla, central and lateral incisors are missing.



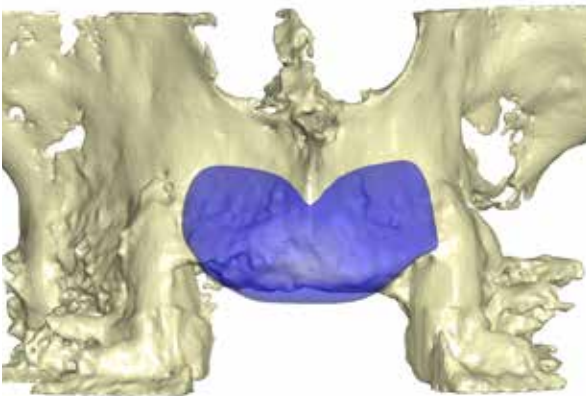
2 Initial situation after removal of the 4-unit fixed partial denture.



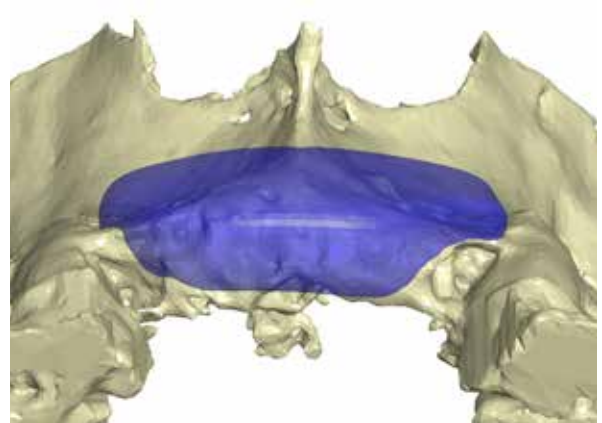
3 Three-dimensional reconstruction of the defect, lateral view.



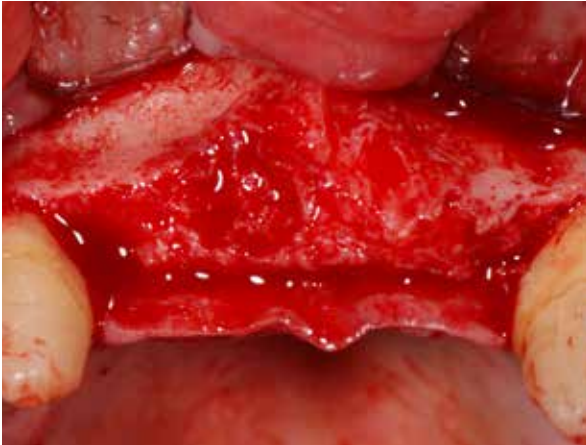
4 Three-dimensional reconstruction of the defect, occlusal view.



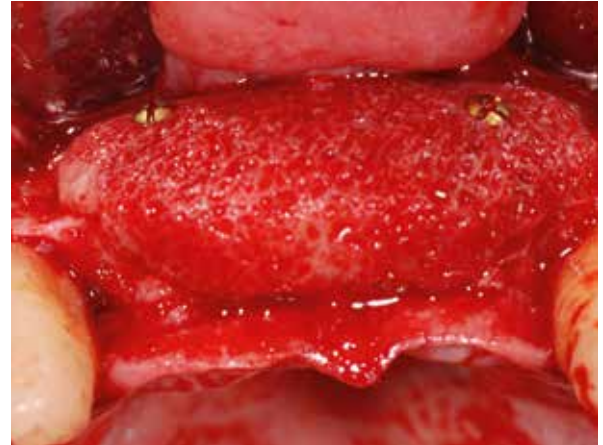5 Designed bone block, lateral view.



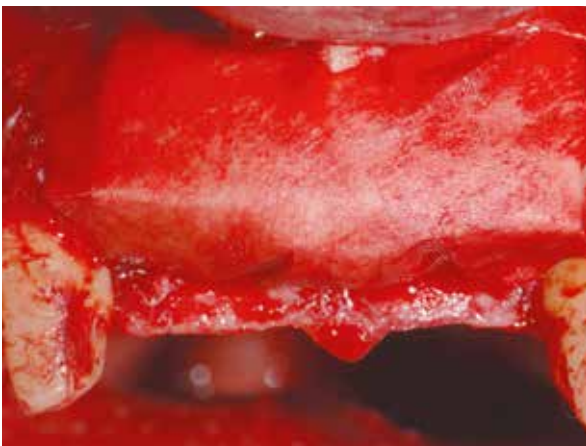6 Designed bone block, occlusal view.



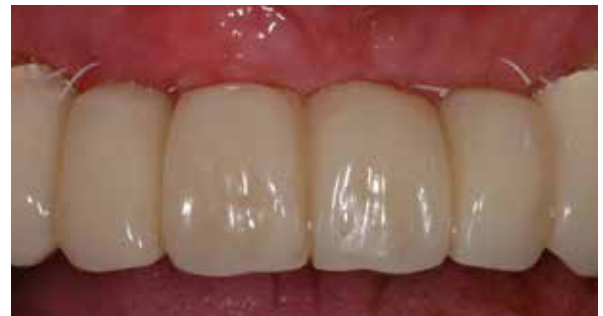7 Surgical site.



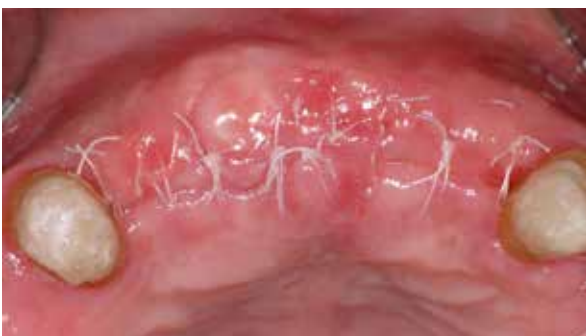8 Fixed bone block.



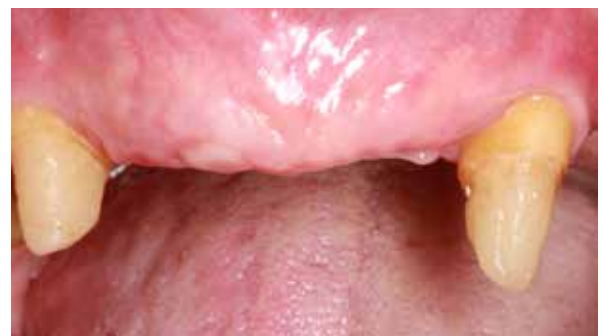9 Covering with a collagen membrane.*



10 Provisional Restoration.



11 Healing, 14 days post-op.



12 Soft-tissue situation and contour 6-months post-operative, facial view.

*The collagen membrane is not part of the Zimmer Biomet Dental portfolio.

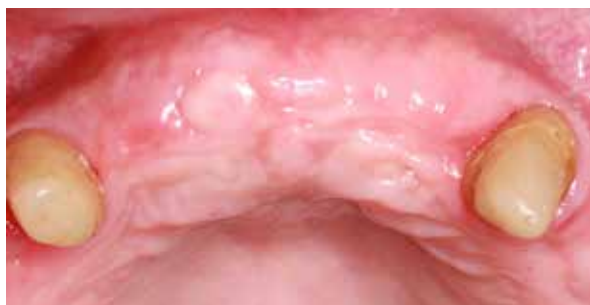CASE 3 Lateral And Vertical Onlay Graft Site [21-22]

PRACTITIONER

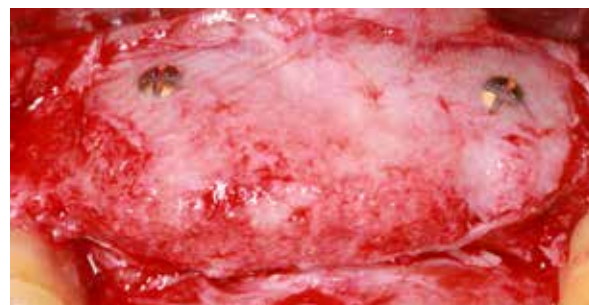Dr. K. Fischer
University of Witten/ Herdecke (Germany)

MATERIAL

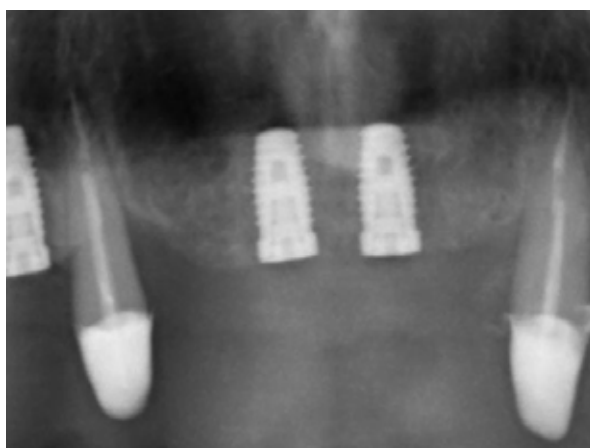
- Puros Allograft Customized Block
- Puros Allograft Cancellous Particles 0.25–1 mm, 0.5 cc



13 Soft-tissue situation and contour 6-months post-operative, occlusal view.



14 Re-entry 6-months post-op, screws in tight contact with bone, residual remnants of membrane visible.



15 Radiograph after implant placement.

Clinical photographs courtesy of Dr K. Fischer. Individual results may vary.



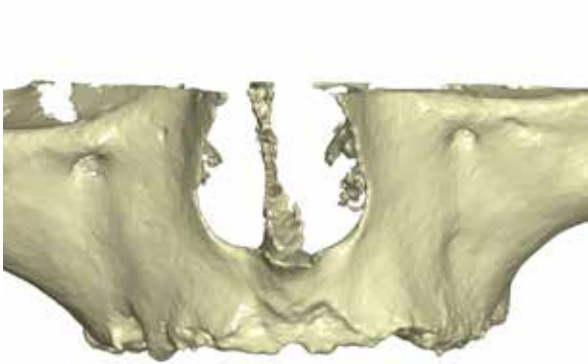
CASE 4 Vertical And Lateral Augmentation Sites [12-16] and [22-26]

PRACTITIONER

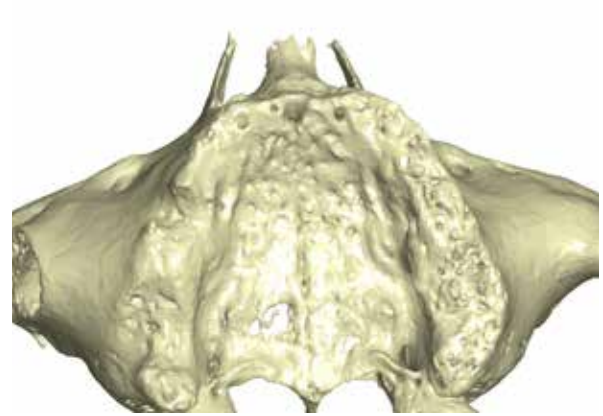
Dr. O. Richter
Hamburg (Germany)

MATERIAL

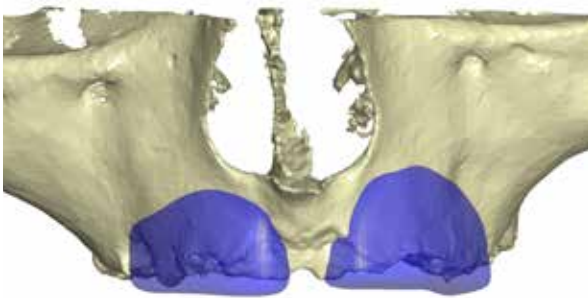
- Puros Allograft Customized Block
- Puros Allograft Cancellous Particles 0.25–1 mm, 0.5 cc
- CopiOs Pericardium Membrane 30 x 40 mm
- Tapered Screw-Vent Implants



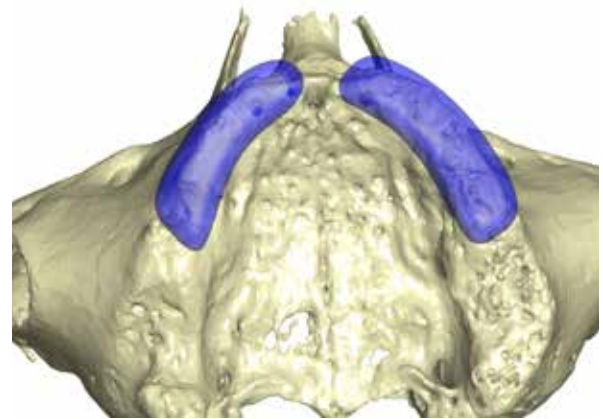
1 Three-dimensional reconstruction of the defect, facial view.



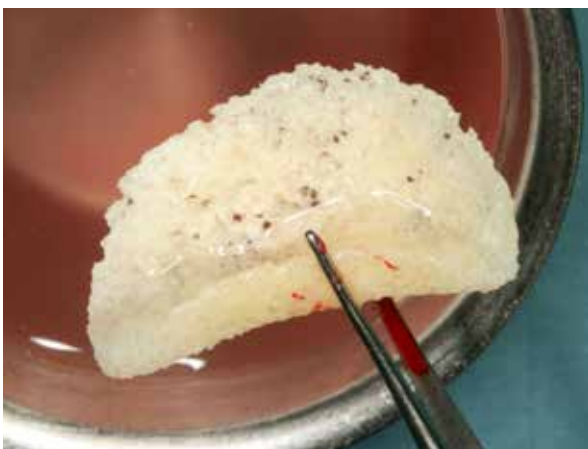2 Three-dimensional reconstruction of the defect, occlusal view.



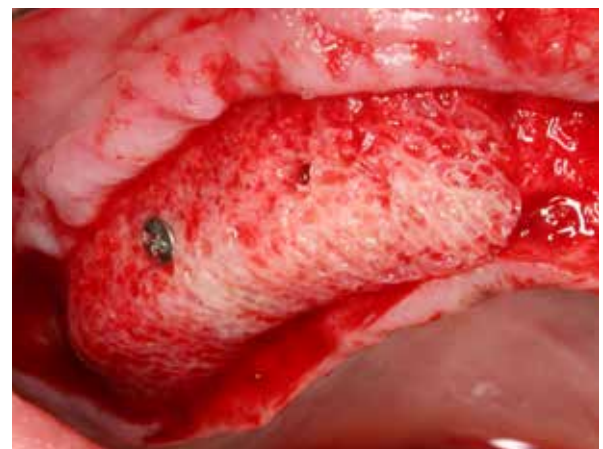
3 Designed bone block, facial view.



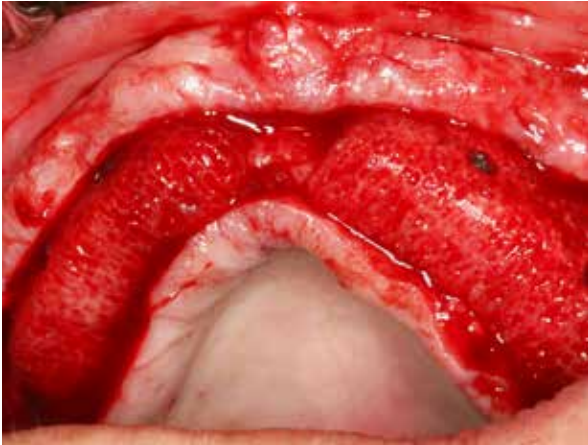4 Designed bone block, occlusal view.



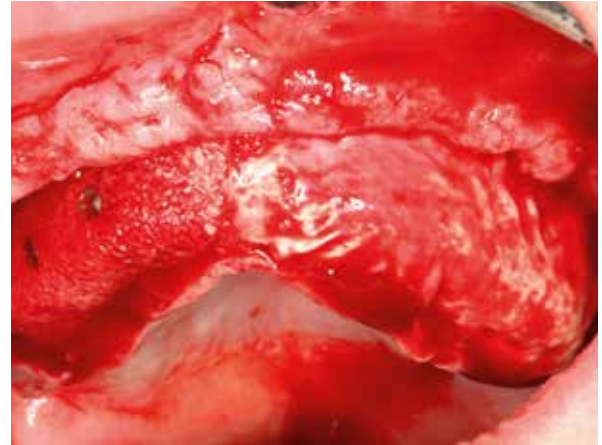
5 Milled Puros Allograft Customized Block.



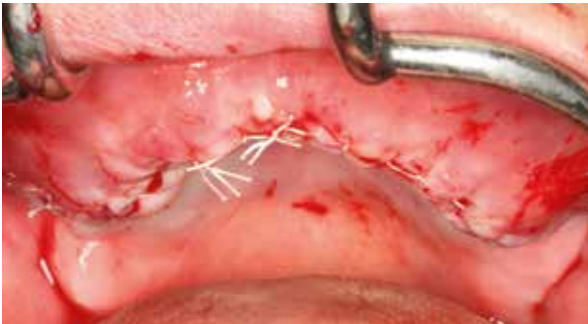6 Fixed bone block, maxillary right.



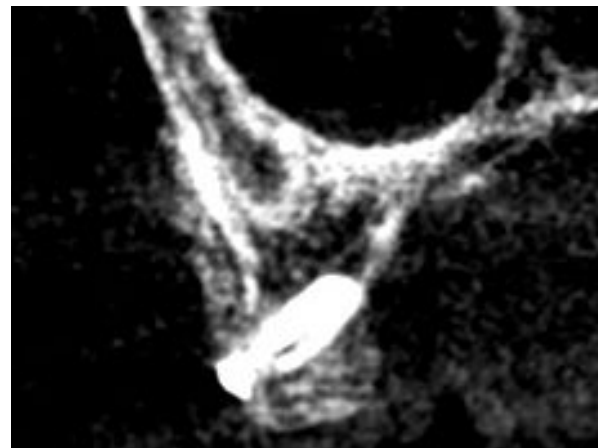7 Fixed bone blocks.



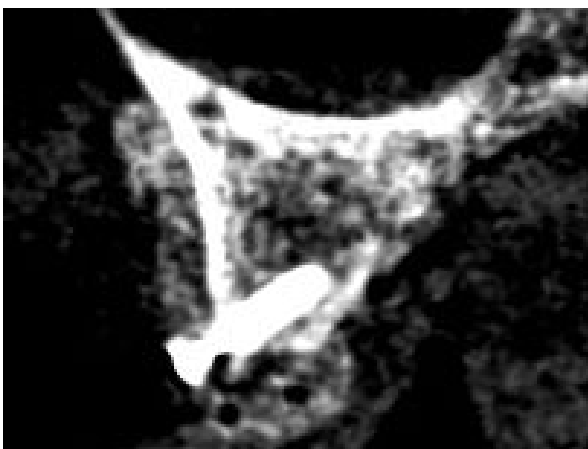8 Covered with a CopiOs Pericardium Membrane.



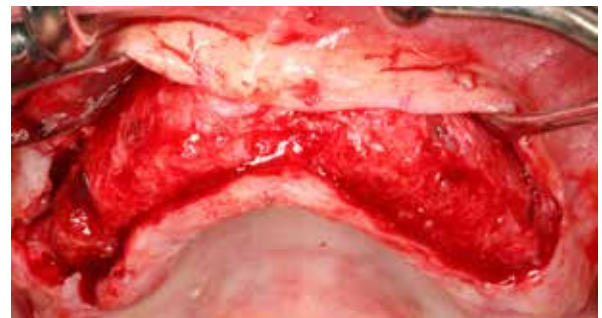9 Wound closure.



10 CBCT scan after augmentation showing, well fitting block, site [13].



11 CBCT scan after augmentation showing well fitting block, site [15].



12 Re-entry 6-months post-op, screw heads in tight contact with bone.

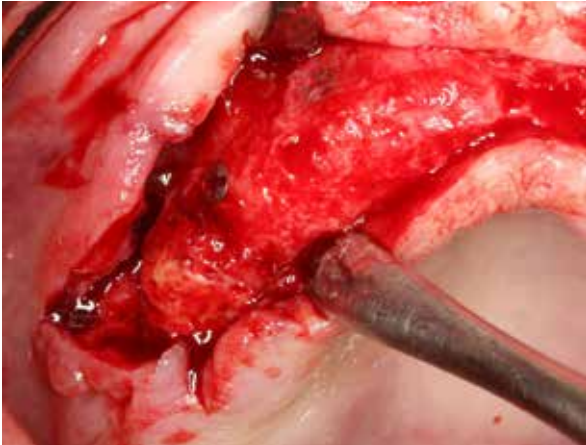
CASE 4 Vertical And Lateral Augmentation Sites [12-16] and [22-26]

PRACTITIONER

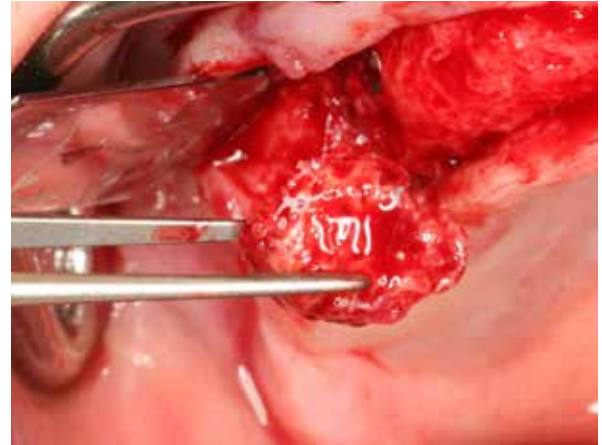
Dr. O. Richter
Hamburg (Germany)

MATERIAL

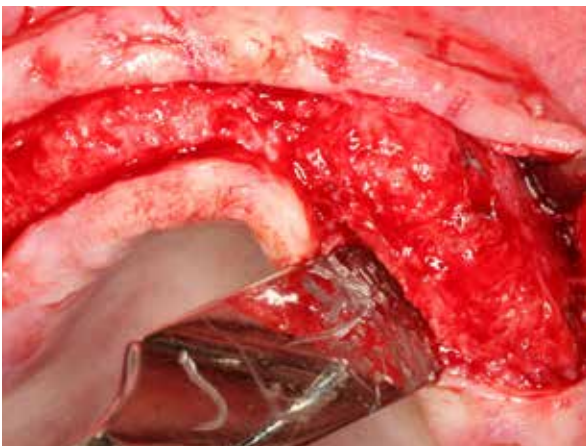
- Puros Allograft Customized Block
- Puros Allograft Cancellous Particles 0.25–1 mm, 0.5 cc
- CopiOs Pericardium Membrane 30 x 40 mm
- Tapered Screw-Vent Implants



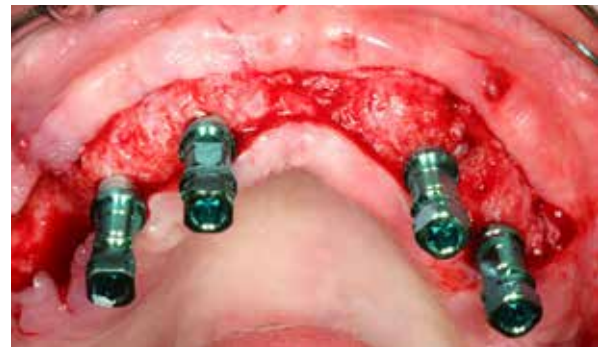13 Upper right maxilla 1, 6 months post-op, partial sequestrum, site [16].



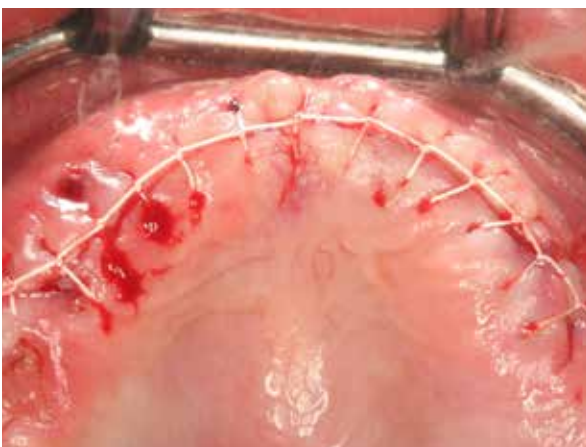
14 Sequestrum removed, site [16].



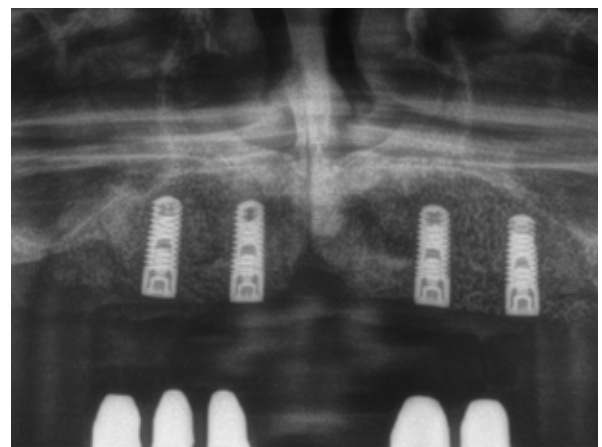
15 Maxillary left, 6 months post-op.



16 Tapered Screw-Vent Implants in place.



17 Wound closure.



18 Radiograph after implant placement.

Clinical photographs courtesy of Dr O. Richter. Individual results may vary.



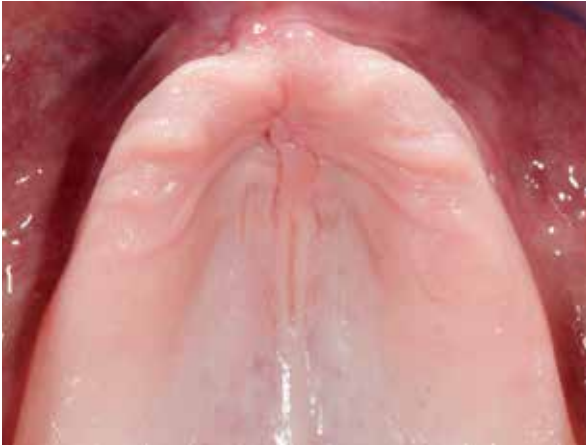CASE 5 Vertical And Lateral Augmentation Sites [12-16] And [22-26]

PRACTITIONER

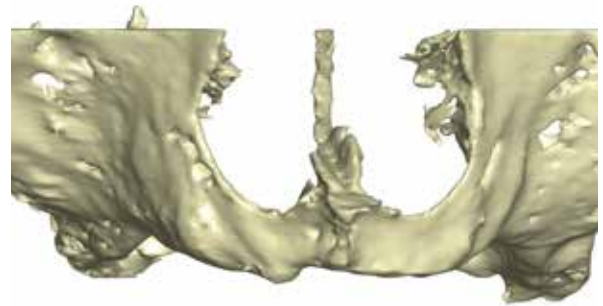
Dr. M. Hinze
Gräfelfing (Germany)

MATERIAL

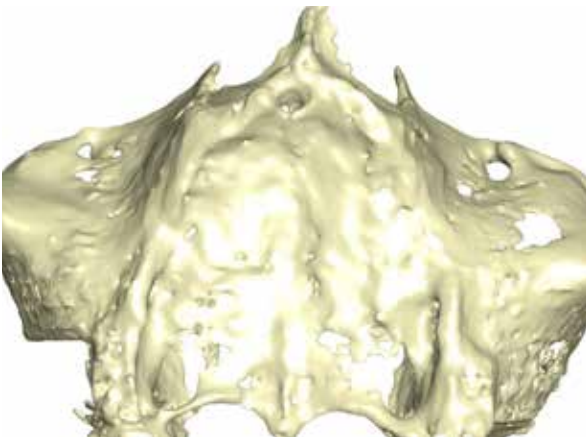
- Puros Allograft Customized Block
- Puros Allograft Cancellous Particles 0.25–1 mm, 0.5 cc
- CopiOs Pericardium Membrane 30 x 40 mm



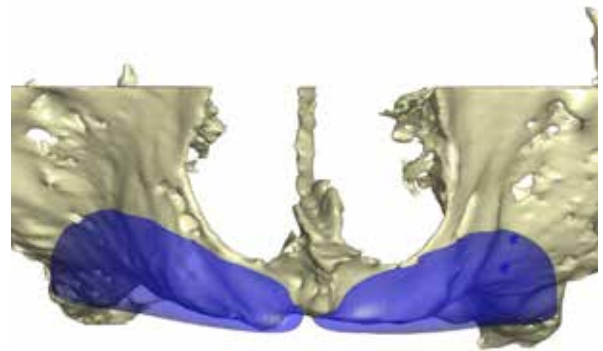
1 Initial situation is showing edentulous maxilla with severe horizontal and vertical bone deficiency.



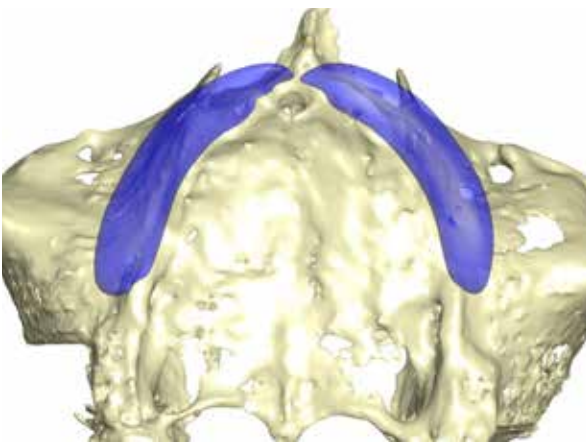
2 Three-dimensional reconstruction of the defect, facial view.



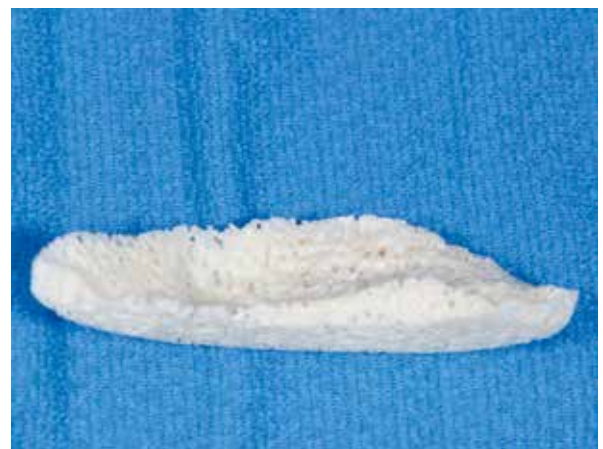3 Three-dimensional reconstruction of the defect, occlusal view.



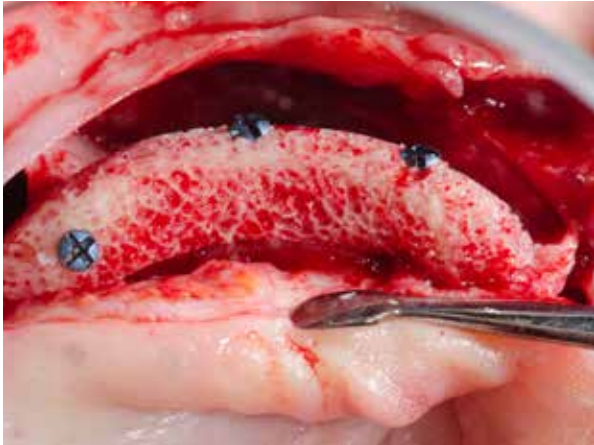4 Designed bone block, facial view.



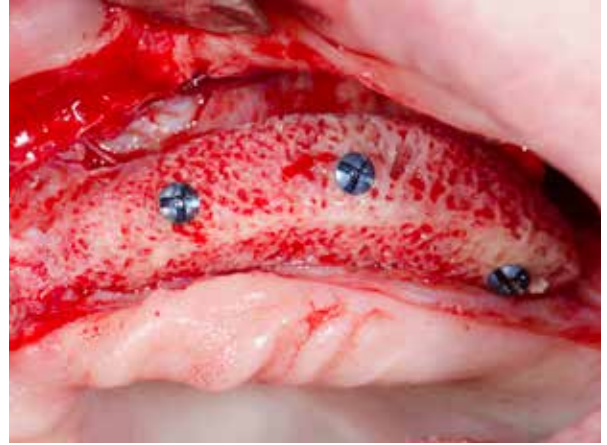5 Designed bone block, occlusal view.



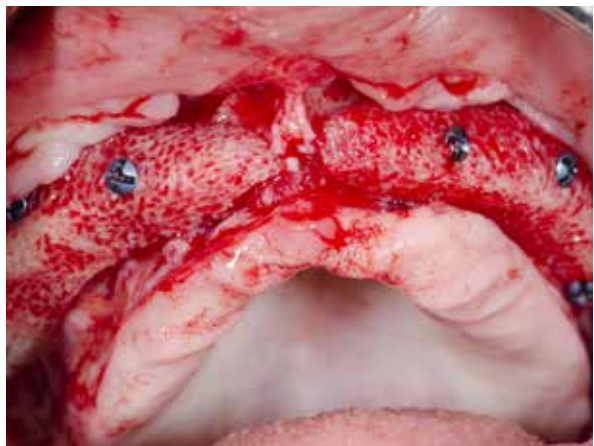6 Milled Puros Allograft.



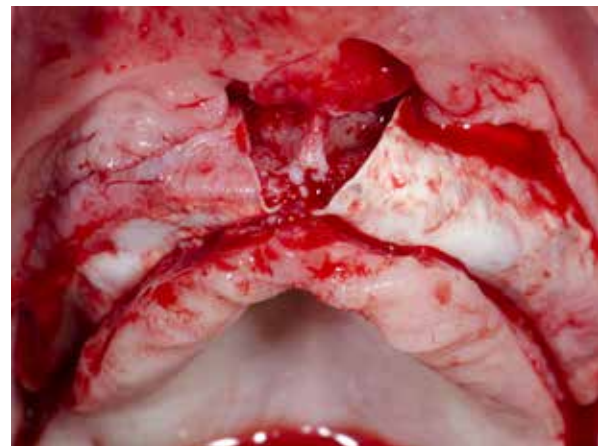7 Fixed bone block maxillary right.



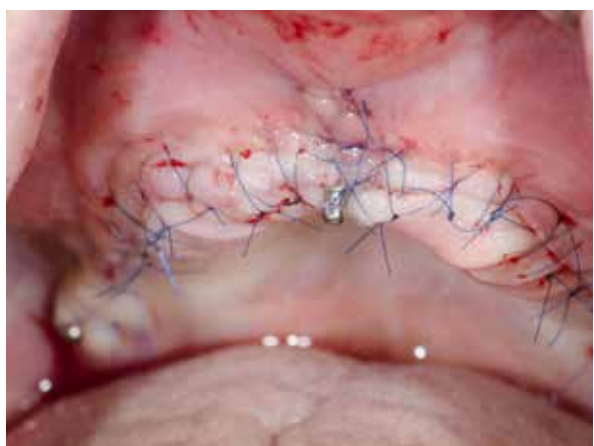
8 Fixed bone block maxillary left.



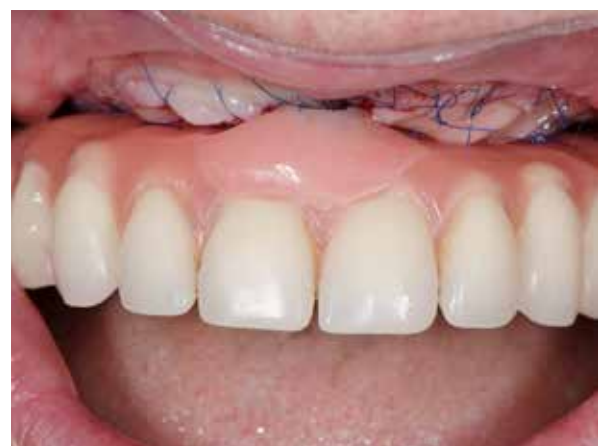9 Fixed bone blocks.



10 Covered with CopiOs Pericardium Membranes.



11 Wound closure, temporary implants placed to support provisional restoration.



12 Provisional restoration without pressure on graft.

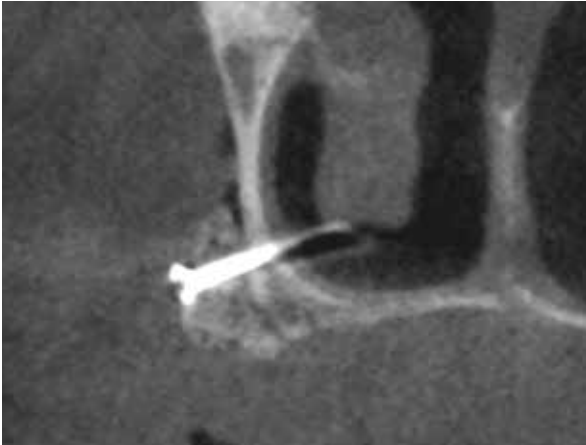CASE 5 Vertical And Lateral Augmentation Sites [12-16] And [22-26]

PRACTITIONER

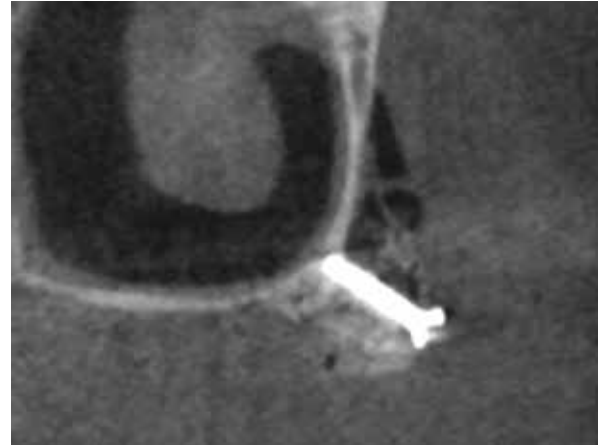
Dr. M. Hinze
Gräfelfing (Germany)

MATERIAL

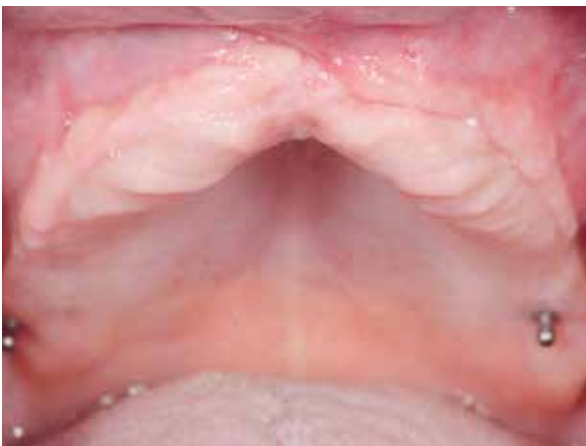- Puros Allograft Customized Block
- Puros Allograft Cancellous Particles 0.25–1 mm, 0.5 cc
- CopiOs Pericardium Membrane 30 x 40 mm



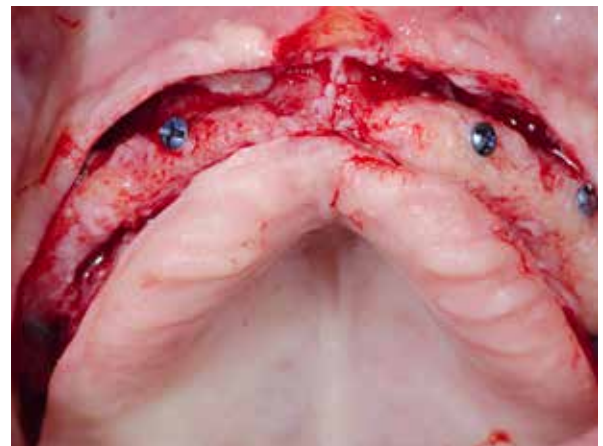13 Post-op CT scan, showing a well fitting block, site [14].



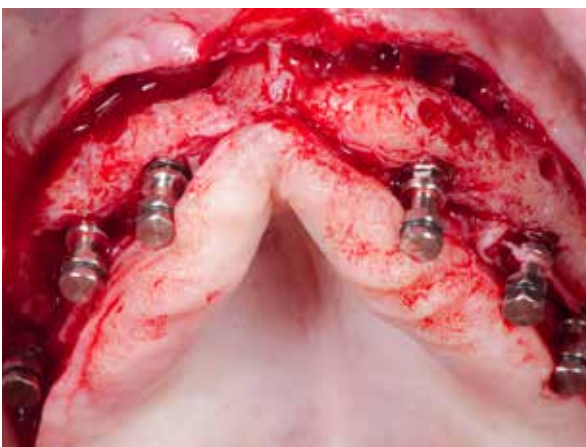
14 CBCT scan after augmentation showing well-fitting block, site [24].




15 Soft tissue, 5-months post-operative.



16 Re-entry 5-months post-op, screw heads in tight contact with bone.



17 Six implants in place.



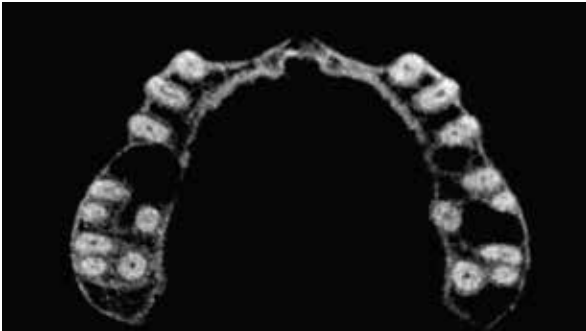18 Radiograph taken after implant placement.

Clinical photographs courtesy of Dr M. Hinze. Individual results may vary.



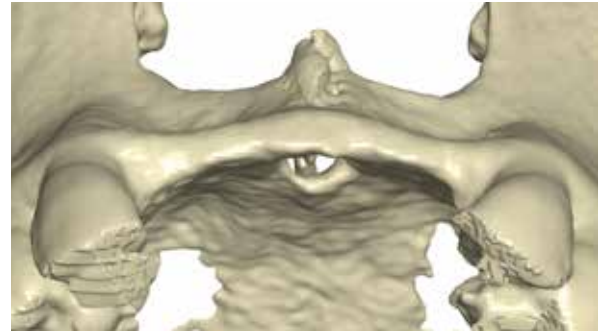
Design And Milling Of A Puros Allograft Customized Block

STEP BY STEP

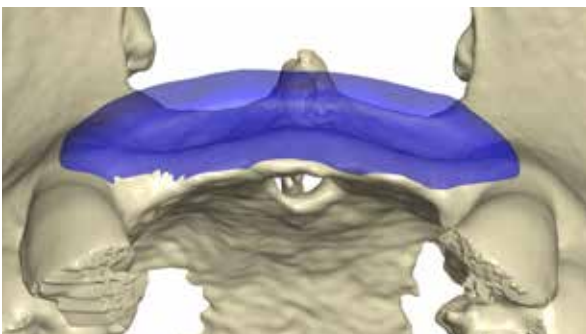


1 Imaging

CT or CBCT, DICOM data, cross-section thickness between 0.2–0.6 mm, high contrast image.

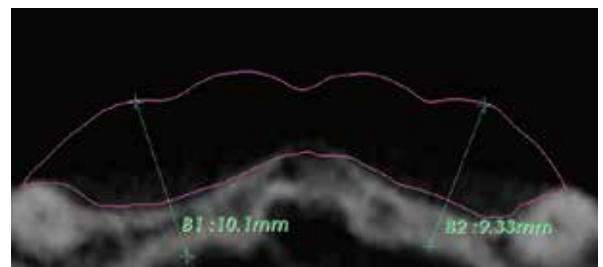


2 Modeling/segmentation



3 Block design

Determination of bony defect, shaping of block geometry.



4 Design control

Review and release by clinician.



5 Manufacture of block

Milling.

According to: Würzler KK, Will F, Berger S. Herstellung und Anwendung CAD/CAM-gefräster, patientenspezifischer Knochenblöcke. Implantologie Journal (2015) 5:30–36

Literature Regarding Puros Allograft Customized Block

1. Schlee M, Rothamel D. Ridge augmentation using customized allogenic bone blocks: proof of concept and histological findings. *Implant Dent* (2013) 22:304-8.
2. Würzler KK, Will F, Berger S. Herstellung und Anwendung CAD/CAM-gefräster, patientenspezifischer Knochenblöcke. *Implantologie Journal* (2015) 5:30-36.

General Literature Regarding Cad/Cam Techniques For Hard-Tissue Reconstruction

1. Eufinger H, Wehmoller M, Machtens E, Heuser L, Harders A, Kruse D. Reconstruction of craniofacial bone defects with individual alloplastic implants based on CAD/CAM manipulated CT-Data. *J. Craniomaxillofac. Surg.* (1995) 23:175-181.
2. Peters F, Groisman D, Davids R, Hanel T, Durr H, Klein M. Comparative study of patient individual implants from beta-tricalcium phosphate made by different techniques based on CT data. *Materialwiss. Werkstofftech.* (2006) 37:457-461.
3. Blume O, Back M, Born T, Smeets R, Jung O, Barbeck M. Treatment of a bilaterally severely resorbed posterior mandible due to early tooth loss by Guided Bone Regeneration using customized allogeneic bone blocks: A case report with 24 months follow-up data. *J Esthet Restor Dent* (2018), doi:10.1111/jerd.12388-
4. Klein M, Glatzer C. Individual CAD/CAM fabricated glass-bioceramic implants in reconstructive surgery of the bony orbital floor. *Plast Reconstr Surg* (2006) 117:565-570.
5. Hallermann W, Olsen S, Bardyn T, Taghizadeh F, Banic A, Iizuka T. A new method for computer-aided operation planning for extensive mandibular reconstruction. *Plast Reconstr Surg* (2006) 117:2431-7.
6. Khalyfa A, Vogt S, Weisser J, Grimm G, Rechtenbach A, Meyer W, Schnabelrauch M. Development of a new calcium phosphate powder-binder system for the 3D printing of patient specific implants. *J Mater Sci Mater Med* (2007) 18:909-16.
7. Binder WJ. Custom-designed facial implants. *Facial plastic surgery clinics of North America* (2008) 16:133-46, vii.
8. Cohen A, Laviv A, Berman P, Nashef R, Abu-Tair J. Mandibular reconstruction using stereolithographic 3-dimensional printing modeling technology. *Oral Surg Oral Med Oral Pathol Oral Radiol Endod* (2009) 108:661-6.
9. Guo LJ, Tian WD, Feng F, Long J, Li PF, Tang W. Reconstruction of orbital floor fractures comparison of individual prefabricated titanium implants and calvarial bone grafts. *Ann Plas Surg* (2009) 63:624-631.
10. Zhou L-B, Shang H-T, He L-S, Bo B, Liu G-C, Liu Y-P, Zhao J-L. Accurate reconstruction of discontinuous mandible using a reverse engineering/computer-aided design/rapid prototyping technique: a preliminary clinical study. *J Oral Maxillofac Surg* (2010) 68:2115-2121.
11. Lethaus B, Kessler P, Boeckman R, Poort LJ, Tolba R. Reconstruction of a maxillary defect with a fibula graft and titanium mesh using CAD/CAM techniques. *Head Face Med* (2010) 6:16.
12. Saldarriaga JFI, Vélez SC, Posada MDaC, Henao IEBB, Valencia MECaT. Design and manufacturing of a custom skull implant. *American Journal of Engineering & Applied Sciences* (2011) 4:169-174.
13. Brune JC, Hesselbarth U, Seifert P, Nowack D, Von Versen R, Smith MD, Seifert D. CT lesion model-based structural allografts: custom fabrication and clinical experience. *Transfusion Medicine and Hemotherapy* (2012) 39:395-404.
14. Ciocca L, Donati D, Fantini M, Landi E, Piattelli A, Iezzi G, Tampieri A, Spadari A, Romagnoli N, Scotti R. CAD-CAM-generated hydroxyapatite scaffold to replace the mandibular condyle in sheep: Preliminary results. *J Biomater Appl* (2013) 28:207-218.

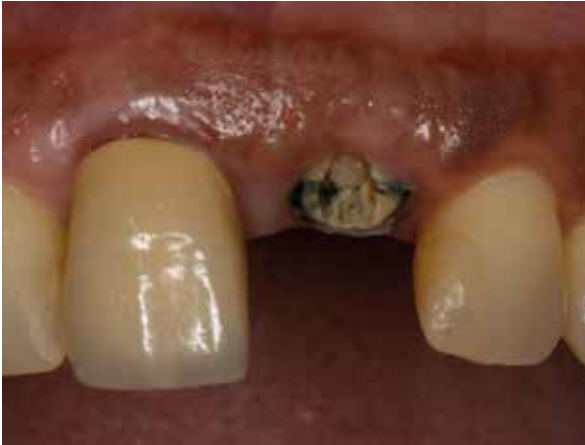CASE 1 Flapless Procedure With Free Gingival Graft Site [21]

PRACTITIONER

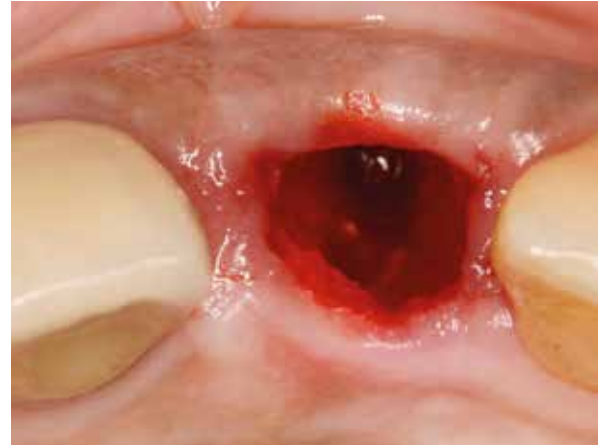Prof. S. Fickl
University of Würzburg (Germany)

MATERIAL

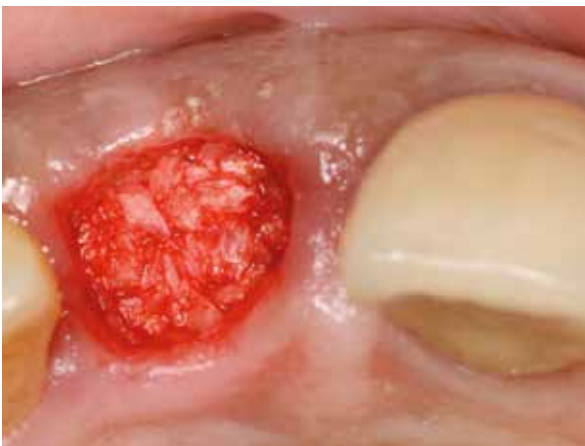• Puros Allograft Cancellous Particles 1–2 mm, 1 cc



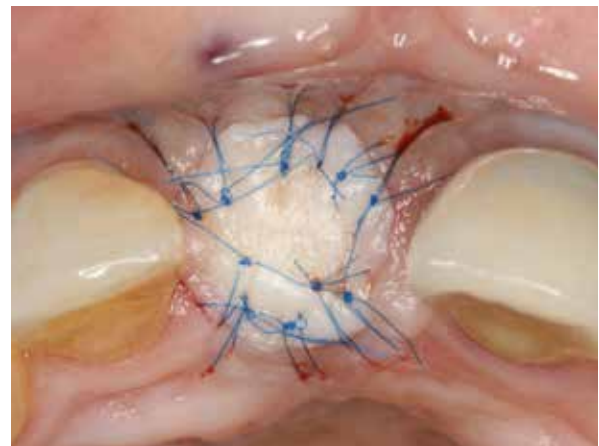
1 Initial situation, fractured central incisor needs to be extracted.



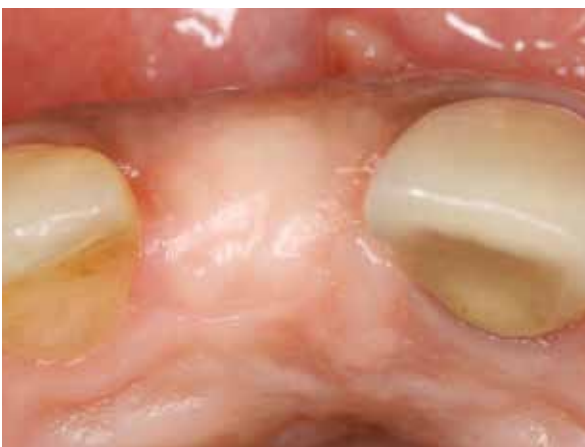2 Atraumatic extraction, socket intact.



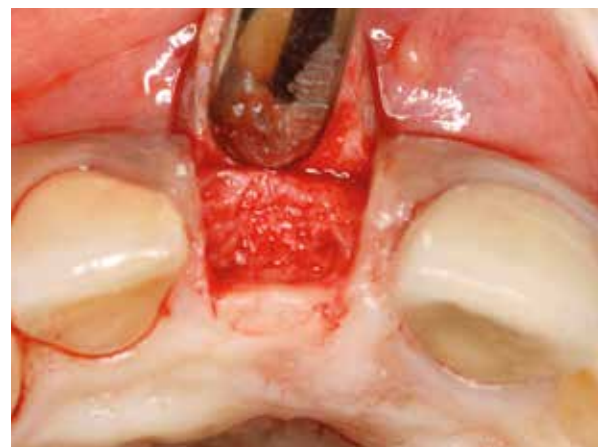3 Socket augmentation using Puros Allograft Cancellous Particles.



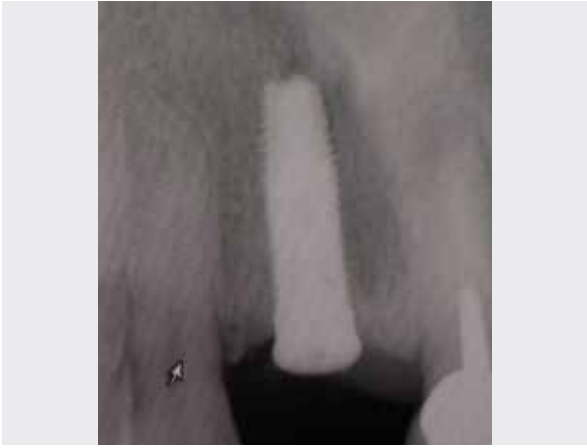4 Covered with a free gingival graft.



5 Soft tissue, 6 months post-op.



6 Bone situation, 6 months post-op.



7 Radiograph taken after implant placement, showing implant placed in healed bone.

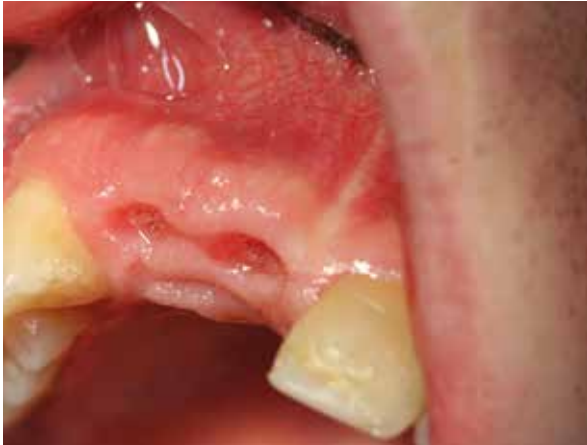CASE 2 Ridge Preservation After Multiple Extraction, Site [11-12]

PRACTITIONER

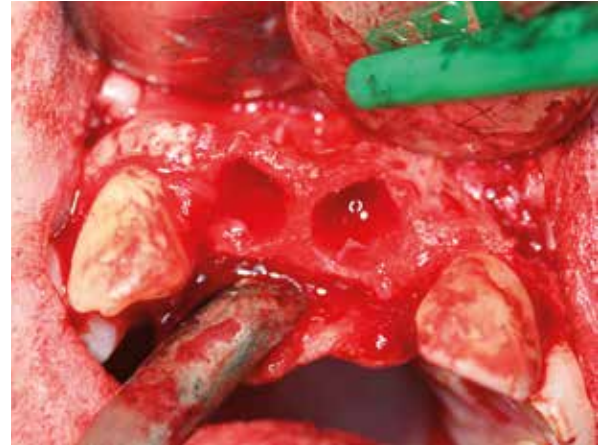
R. Stutzki
Magdeburg (Germany)

MATERIAL

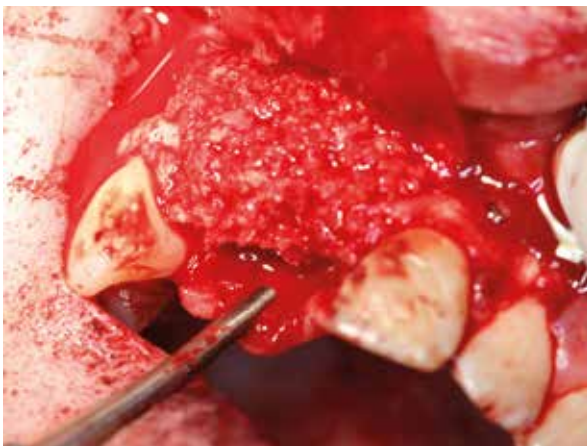
- Puros Allograft Cancellous Particles 0.25–1 mm, 2 cc
- CopiOs Pericardium Membrane 30 x 40 mm
- Tapered Screw-Vent Implants



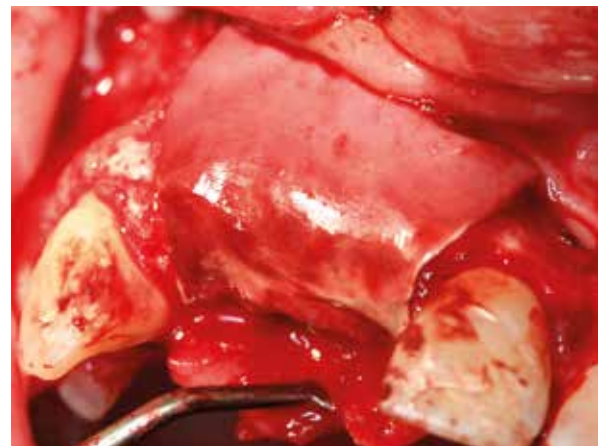
1 Initial situation, healed soft tissue after extraction of tooth [11] and [12].



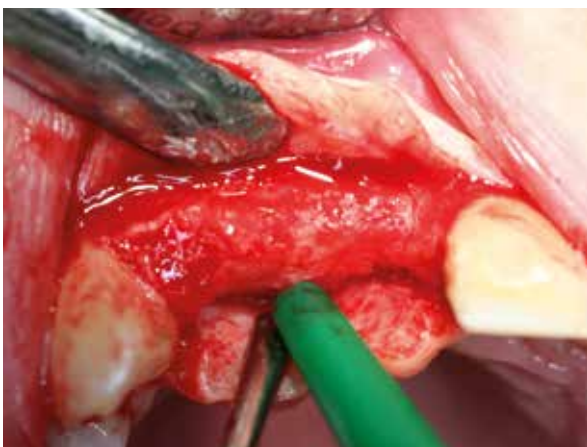2 Horizontal bone deficiency after flap elevation.



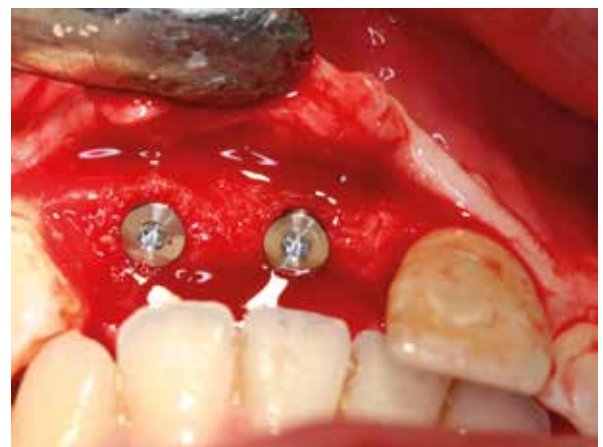3 Augmentation with Puros Allograft Cancellous Particles.



4 Covering with a CopiOs Pericardium Membrane.



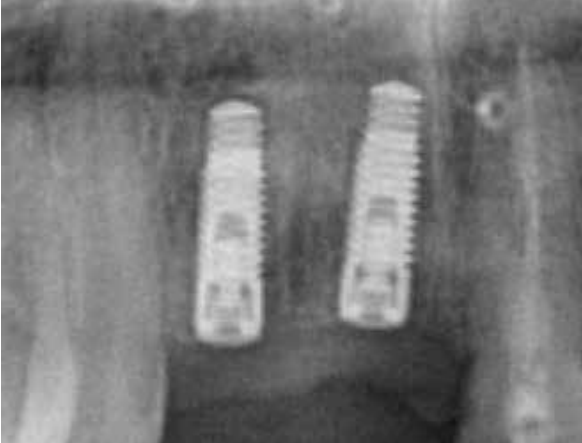
5 Bone situation at re-entry 6 months post-op.



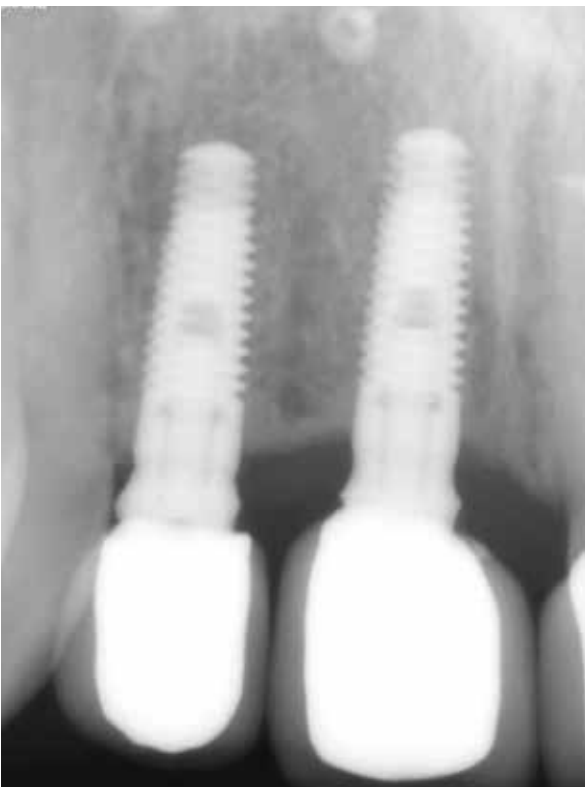6 Placement of Tapered Screw-Vent Implants, occlusal view.

Clinical photographs courtesy of R. Stutzki. Individual results may vary.

4 YEAR FOLLOW-UP



7 Final radiograph.



8 Radiograph taken 3.5 years after implantation. Note the stable bone conditions.

Clinical photographs courtesy of R. Stutzki. Individual results may vary.

PROSPECTIVE TRIAL

Grafting Of Extraction Sites With Puros Allograft Cancellous Particles Compared To Non-Grafted Sites

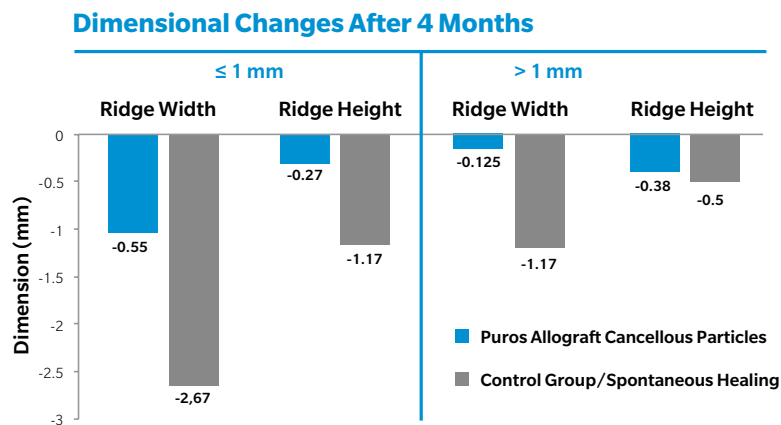
Spinato S. et al. Is socket healing conditioned by buccal plate thickness? A clinical and histologic study 4 months after mineralized human bone allografting. Clin Oral Implants Res (2014) 25:e120-6.

Study Design

After 31 extraction (flapless procedure) in 31 patients, the sockets were divided into 2 groups (I) thick buccal bone plate (> 1 mm); (II) thin buccal bone plate (\leq 1 mm). 19 sockets were grafted with Puros Allograft Cancellous Particles 0.25–1 mm (test group) and covered with a resorbable wound dressing (CollaPlug[®], Zimmer Dental). 12 patients did not receive a graft (spontaneous healing, control group). After four months, changes to socket dimensions were measured and biopsies taken.

Results

Grafting with Puros Allograft Cancellous Particles reduces height and width loss in sockets with both thin (\leq 1 mm) and thick buccal lamellae (> 1 mm) compared to spontaneous healing. The thickness of the buccal bone plate appears to affect the dimensional changes. Histomorphometry of test group (Puros): Total mineral content 41.48 vs. 45.78%; soft tissue/bone marrow 58.52 vs. 54.21% (\leq 1 mm vs. > 1 mm).



Conclusion

Spontaneous healing of extraction sites leads to significant dimensional losses, which may affect a subsequent implant placement. **Grafting with Puros Allograft can reduce the dimensional changes.**

PROSPECTIVE COMPARISON

Grafting Of Extraction Sites With Puros Allograft Cancellous Particles Healing Period 3.5 Months Vs. 6 Months

Beck TM et al. Histologic analysis of healing after tooth extraction with ridge preservation using mineralized human bone allograft. J Periodontol (2010) 81:1765-1772.

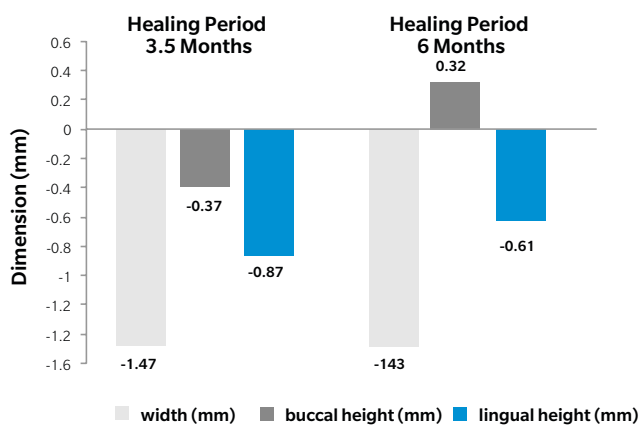
Study Design

After 38 extractions in 33 patients (flapless procedure), the sockets were grafted with Puros Allograft Cancellous Particles (particle size 0.25–1 mm) and covered with a resorbable wound dressing (CollaTape®) or Zimmer Socket Repair Membrane. Re-entry was performed after a healing period of 3.5 (Group 1)/6 months (Group 2), with dimensional changes to the sockets measured and biopsies taken.

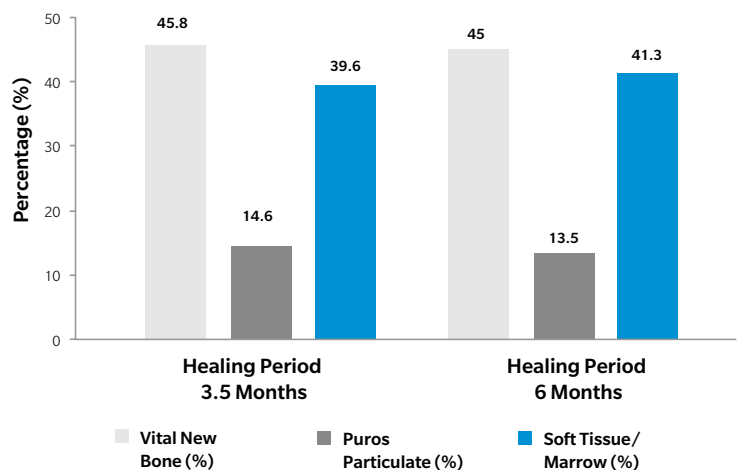
Results

All biopsies showing a **high proportion of new bone** with some residual **Puros particles, which were almost completely** surrounded by newly formed bone. No statistically significant differences were detected with respect to the dimensional changes to the sockets and bone formation.

Dimensional Changes



Histomorphometry



Conclusion

A healing period of 6 months after tooth extraction and grafting with Puros Allograft Cancellous Particles does not increase new bone formation or alter dimensional changes in comparison with a 3.5-month healing period. Implants placed after a 3.5-month healing period may have the same long-term results as implants placed after a longer healing period.

1. Block MS, Finger I, Lytle R. Human mineralized bone in extraction sites before implant placement: Preliminary results. *J Am Dentn Assoc* (2002) 133:1631-1638.
2. Minichetti JC, D'amore JC, Hong AY, Cleveland DB. Human histologic analysis of mineralized bone allograft (Puros) placement before implant surgery. *J Oral Implantol* (2004) 30:74-82.
3. Wang HL, Kiyonobu K, Neiva RF. Socket augmentation: rationale and technique. *Implant Dent* (2004) 13:286-96.
4. Minichetti JC, D'amore JC, Hong AY. Three-year analysis of Tapered Screw-Vent implants placed into extraction sockets grafted with mineralized bone allograft. *J Oral Implantol* (2005) 31:283-93.
5. Jackson BJ, Morcos I. Socket grafting: a predictable technique for site preservation. *J Oral Implantol* (2007) 33:353-64.
6. Wang HL, Tsao YP. Mineralized bone allograft-plug socket augmentation: Rationale and technique. *Implant Dent* (2007) 16:33-41.
7. Danesh-Meyer M. Management of the extraction socket: site preservation prior to implant placement. *Australasian Dental Practice* (2008) 150-158.
8. Wang HL, Tsao YP. Histologic evaluation of socket augmentation with mineralized human allograft. *Int J Periodont Rest Dent* (2008) 28:231-7.
9. Fotek PD, Neiva RF, Wang HL. Comparison of dermal matrix and polytetrafluoroethylene membrane for socket bone augmentation: a clinical and histologic study. *J Periodontol* (2009) 80:776-85.
10. Beck TM, Mealey BL. Histologic analysis of healing after tooth extraction with ridge preservation using mineralized human bone allograft. *J Periodontol* (2010) 81:1765-72.
11. El Chaar ES. Soft tissue closure of grafted extraction sockets in the posterior maxilla: the rotated pedicle palatal connective tissue flap technique. *Implant Dent* (2010) 19:370-7.
12. Fickl S. Socket Preservation zum Zeitpunkt der Zahnextraktion. *Parodontologie Nachrichten* (2010) 1:14.
13. Kistler S. Praxisgerechte Techniken der Alveolar Ridge Preservation. *dentalspiegel* (2011) 5:22-26.
14. Tolstunov L, Chi J. Alveolar ridge augmentation: comparison of two socket graft materials in implant cases. *Compendium of Continuing Education in Dentistry* (2011) 32:E16-E124.
15. Fischer K, Jockel-Schneider Y, Bechtold M, Fickl S, Schlagenhauf U. „Socket preservation“ nach Zahnextraktion. *Der Freie Zahnarzt* (2011) 55:62-68.
16. Sterio TW, Katancik JA, Blanchard SB, Xenoudi P, Mealey BL. A prospective, multicenter study of bovine pericardium membrane with Allograft Cancellous Particles for localized alveolar ridge augmentation. *Int J Perio Rest Dent* (2013) 33:499-507.
17. Richter O. Tatort ästhetische Zone. *teamwork* (2013) 1:76-81.
18. Al-Hezaimi K, Rudek I, Al-Hamdan KS, Javed F, Nooh N, Wang HL. Efficacy of using a dual layer of membrane (dPTFE placed over collagen) for ridge preservation in fresh extraction sites: a micro-computed tomographic study in dogs. *Clin Oral Implants Res* (2013) 24:1152-7.
19. Spinato S, Galindo-Moreno P, Zaffe D, Bernardello F, Soardi CM. Is socket healing conditioned by buccal plate thickness? A clinical and histologic study 4 months after mineralized human bone allografting. *Clin Oral Implants Res* (2014) 25:e120-6.
20. Fu JH, Rios H, Al-Hezaimi K, Oh TJ, Benavides E, Wang HL. A randomized clinical trial evaluating the efficacy of the sandwich bone augmentation technique in increasing buccal bone thickness during implant placement. II. Tomographic, histologic, immunohistochemical, and RNA analyses. *Clin Oral Implants Res* (2014).
21. Fischer K, Fickl S. Alveolenmanagement: Eine Übersicht: Von Sofortimplantation bis Socket-Seal-Technik. *teamwork J CONT DENT EDUC* (2014) 6-14.



CASE 1 Lateral Augmentation Prior To Implantation Site [21]

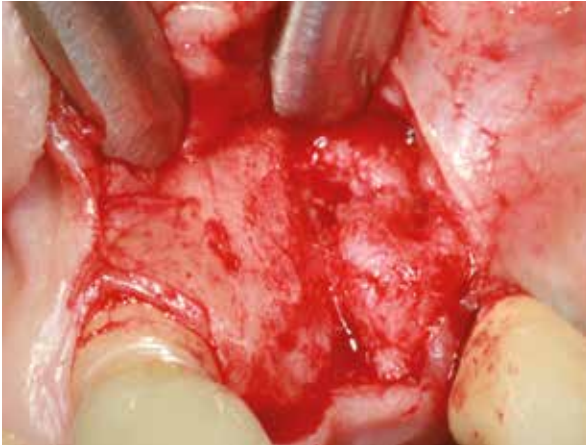PRACTITIONERS

Dr. Dr. Dr. O. Blume
Dr. Dr. T. Müller-Hotop

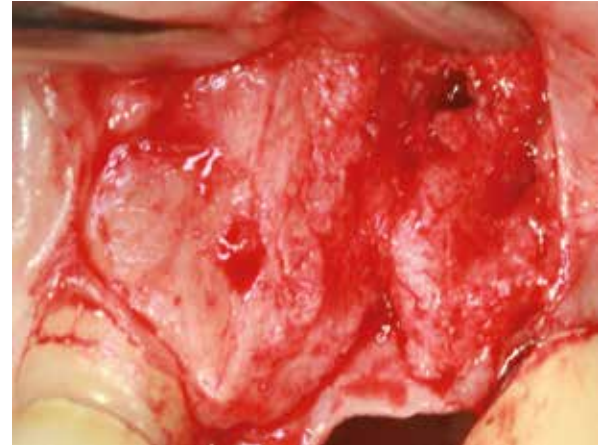
Dr. M. Back
Munich (Germany)

MATERIAL

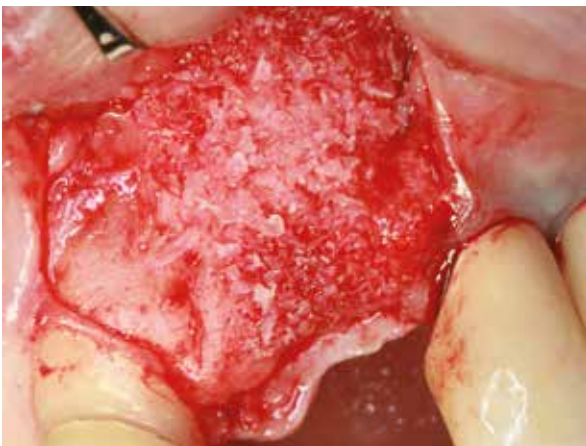- Puros Allograft Cancellous Particles 1–2 mm, 1 cc
- CopiOs Pericardium Membrane 20 x 30 mm



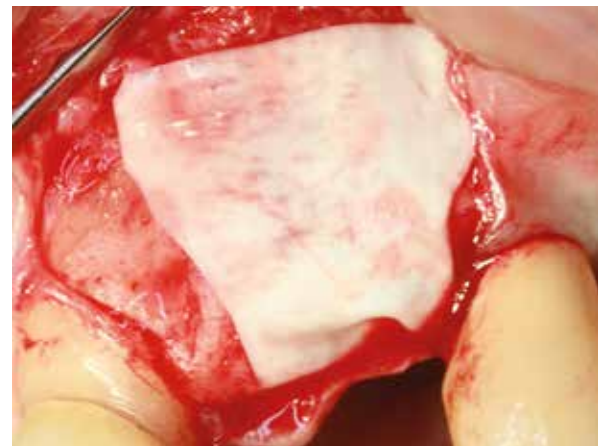
1 Initial situation; horizontal deficiency site [21].



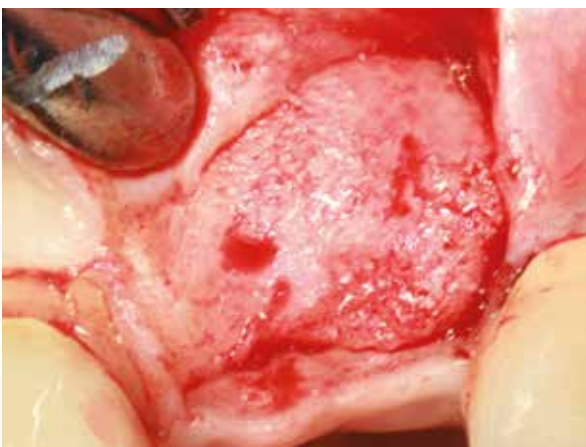2 Lateral/vertical defect, initial situation, lateral view.



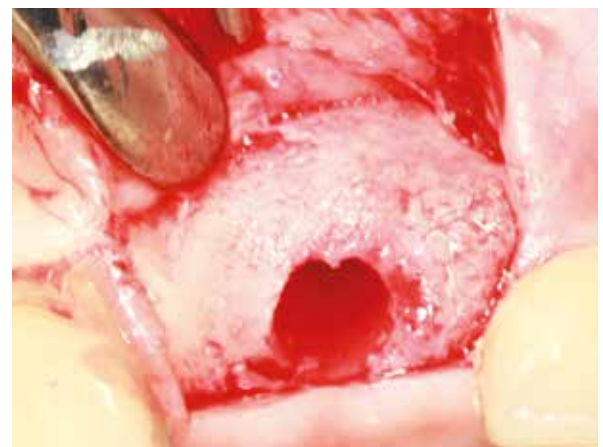3 Grafting with Puros Allograft Cancellous Particles.



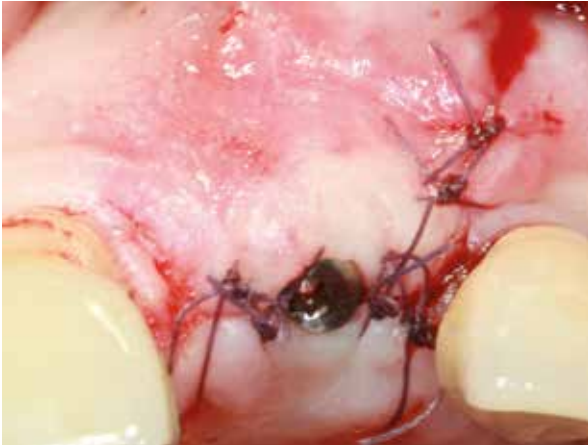4 Covering with a CopiOs Pericardium Membrane.



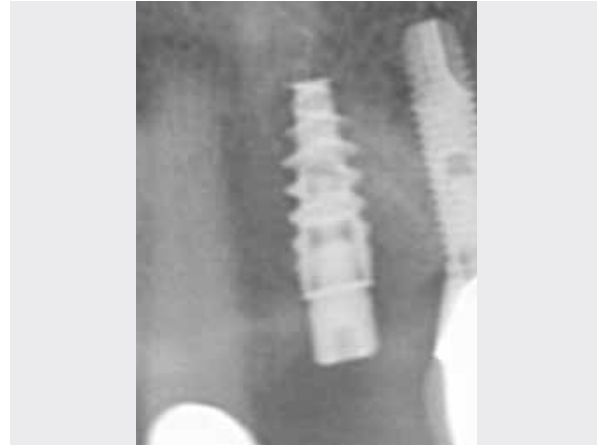5 Bone situation at re-entry 4 months post-op.



6 Final osteotomy.



7 Wound closure.



8 Radiograph taken after implant placement.

Clinical photographs courtesy of Dr. Dr. Dr. O. Blume, Dr. Dr. T. Müller-Hotop, Dr. M. Back. Individual results may vary.

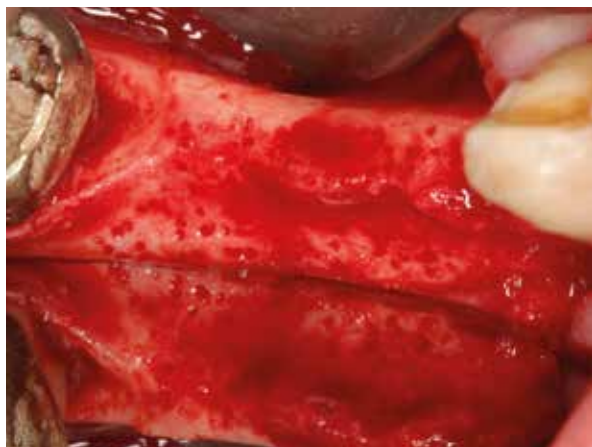
CASE 2 Lateral Augmentation Prior To Implantation Site [44-47], Histomorphometric Analysis

PRACTITIONER

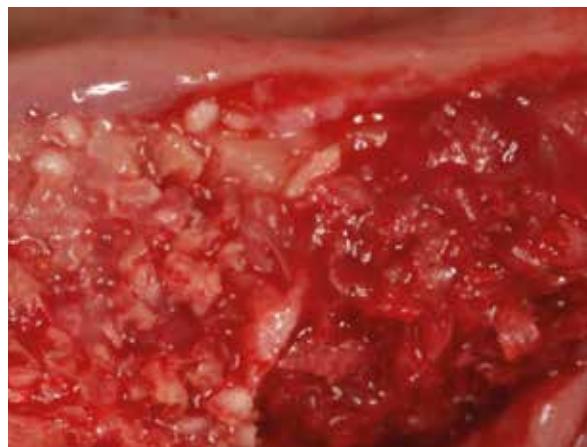
Dr. Ö. Solakoglu
Hamburg (Germany)

MATERIAL

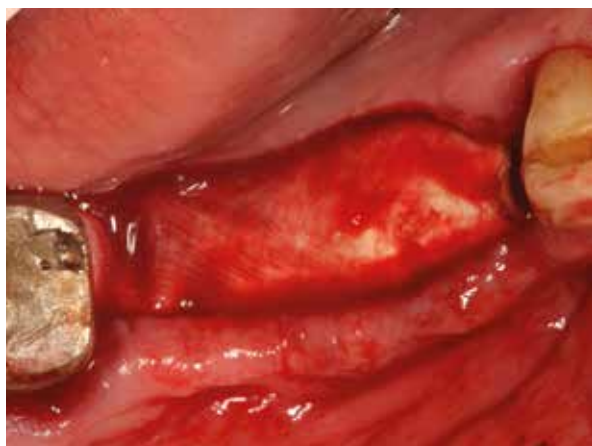- Puros Allograft Cancellous Particles 1–2 mm, 1 cc
- CopiOs Pericardium Membrane 20 x 30 mm



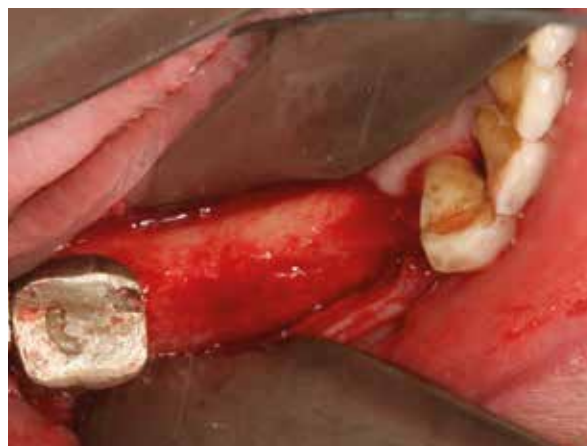1 Bony defect, reduced crestal width.



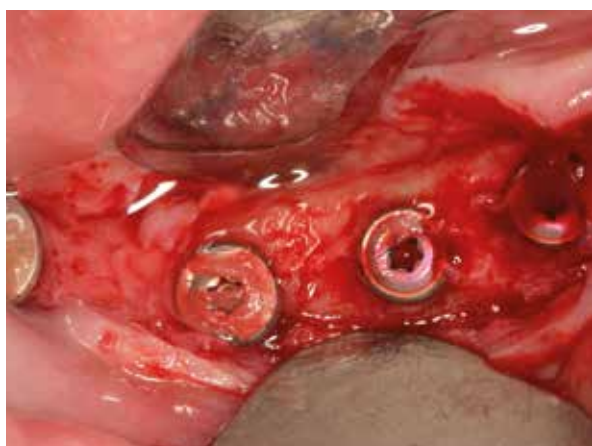
2 Augmentation with Puros Allograft Cancellous Particles, site [44] to [47].



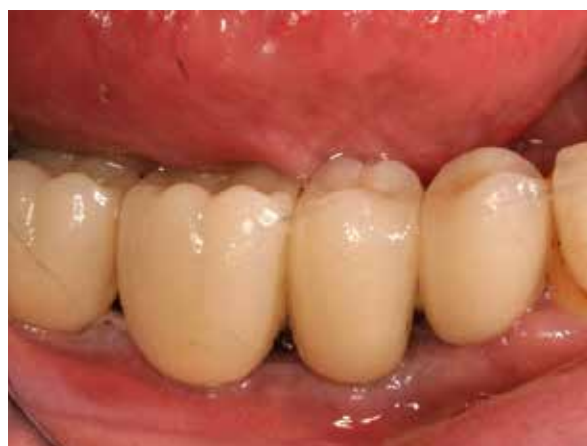3 Covering with a CopiOs Pericardium Membrane.



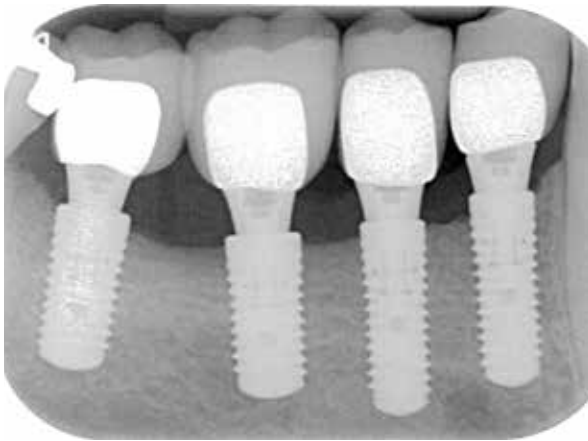
4 Bone situation at re-entry 4 months post-op. Visually vital bone with well integrated graft material.



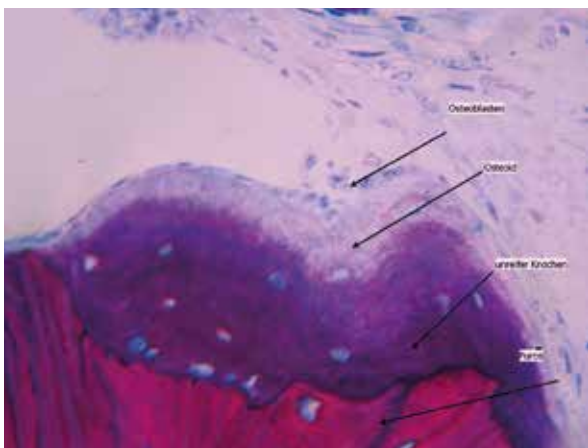
5 Exposure of implant after 4-months healing period.



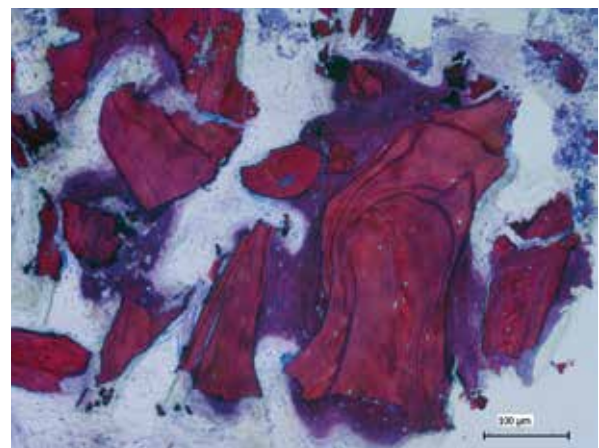
6 Final prosthetic restoration 9 months post-op, lateral view.



7 Prosthetic restoration, radiograph taken 9 months post-op, osseointegrated implants.



8 Histological cross-section (non-decalcified thin section) 10 fold: Healing period 4 months. Formation of vital, new bone (mauve) and residual graft material (reddish purple) is clearly discernible.



9 Histological cross-section (non-decalcified thin section) 40 fold: Healing period 4 months. Osteoblast activity, apposition of osteoid and conversion into immature bone (mauve) on the surface of the graft material (reddish purple).

Comments: Histological and histomorphometric analysis by M. Hasper, HIK Hannover.

The complete case series has been published:

Solakoglu Ö. Präimplantologische laterale Kieferkammaugmentation mit allogenen Knochenersatzmaterial: Eine Fallserie mit histologischer und histomorphometrischer Dokumentation.

Zeitschrift für Zahnärztliche Implantologie (2012) 27:24-32.

Histomorphometric Analysis Of Biopsy

Newly formed bone [%]	Connective tissue/ bone marrow [%]	Residual graft material [%]
27.3	65.2	7.5

Clinical photographs courtesy of Dr Ö. Solakoglu. Individual results may vary.

CASE 3 Implantation And Lateral Augmentation Site [12-22]

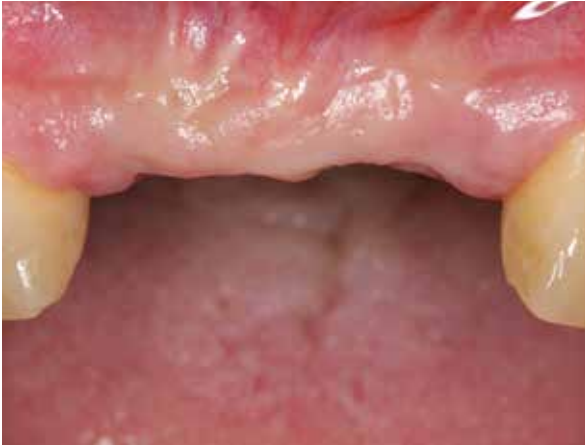PRACTITIONERS

Dr. K. Fischer
University of Witten/Herdecke
(Germany)

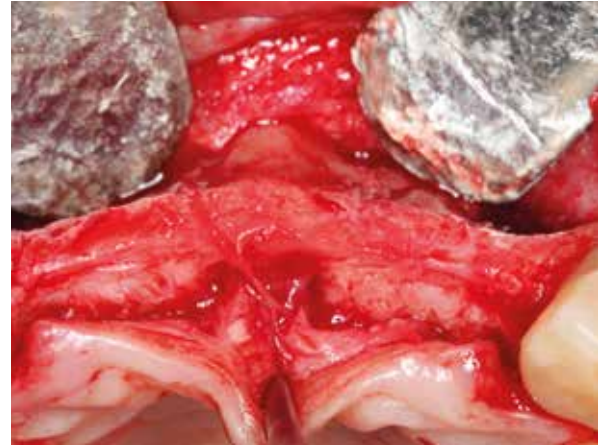
Prof. S. Fickl
University of Würzburg
(Germany)

MATERIAL

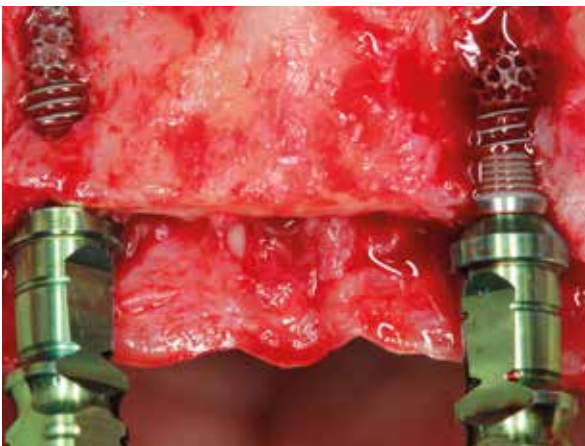
- Puros Allograft Cancellous Particles 1–2 mm, 1 cc
- CopiOs Pericardium Membrane 20 x 30 mm
- Trabecular Metal™ Implants 4.1 x 11.5 mm



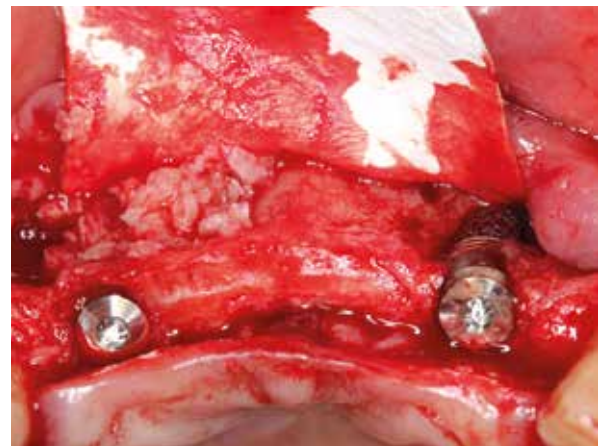1 Initial situation, four incisors are missing.



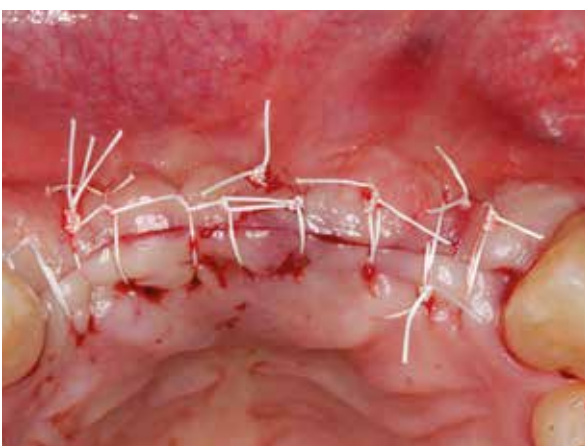2 Bony situation after flap elevation.



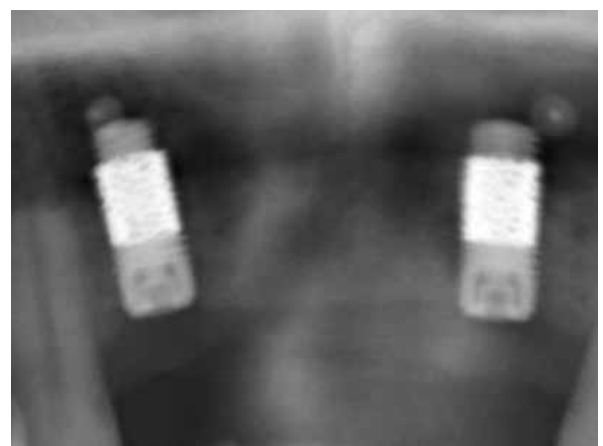
3 Trabecular Metal Implants in place, lateral fenestrations.



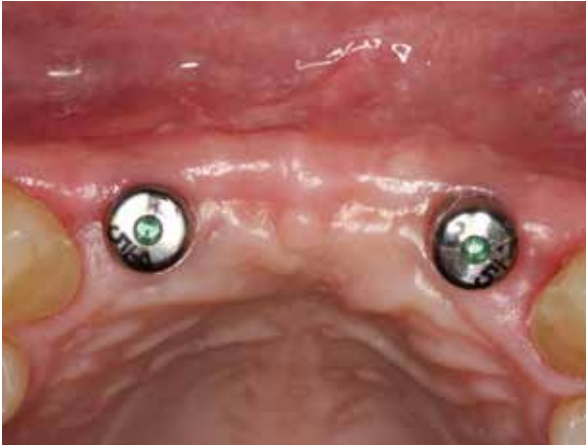4 Augmentation with Puros Allograft Cancellous Particles and covering with a CopiOs Pericardium Membrane.



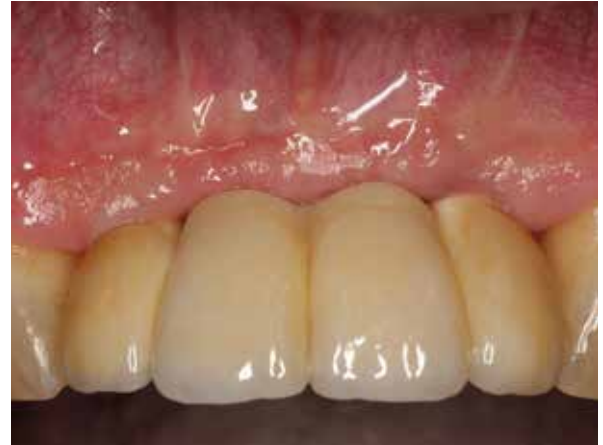5 Wound closure.



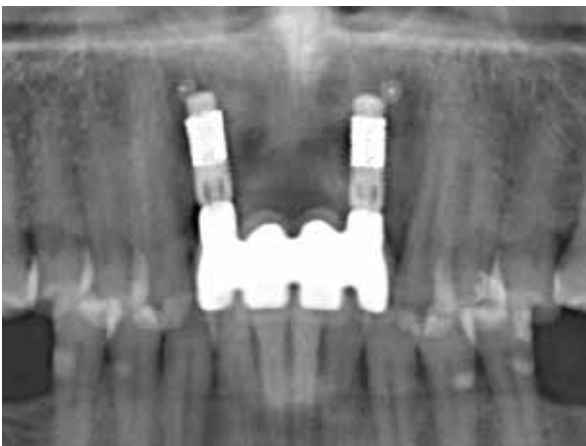6 Radiograph taken after implant placement.



7 4 months post-op during making of impression, occlusal view.



8 Screw-retained ceramic bridge restoration.



9 Radiograph taken after prosthetic restoration.

Clinical photographs courtesy of Dr K. Fischer, Prof. Dr S. Fickl. Individual results may vary.

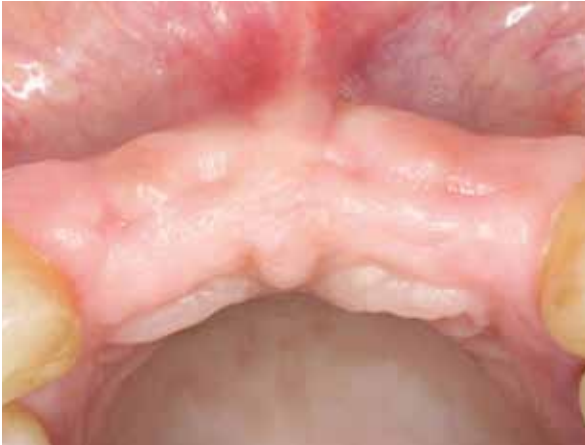CASE 4 Implantation And Lateral Augmentation Site [12-22]

PRACTITIONER

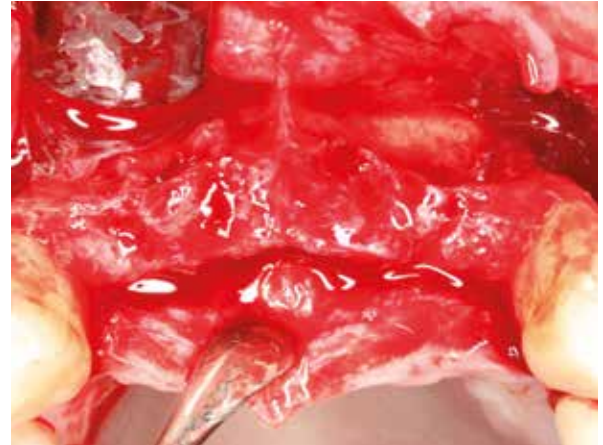Dr. O. Richter
Hamburg (Germany)

MATERIAL

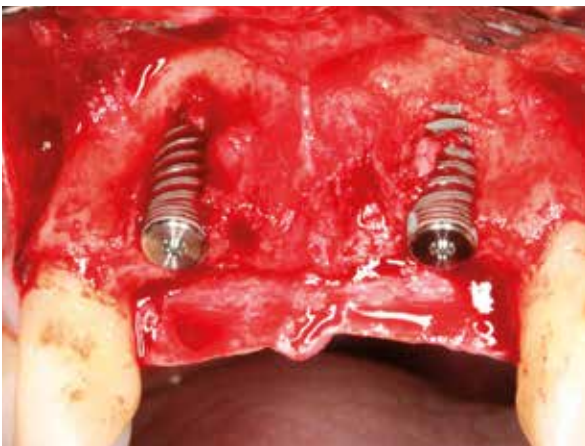
- Puros Allograft Cancellous Particles 0.25–1 mm, 1 cc
- CopiOs Pericardium Membrane 15 x 20 mm



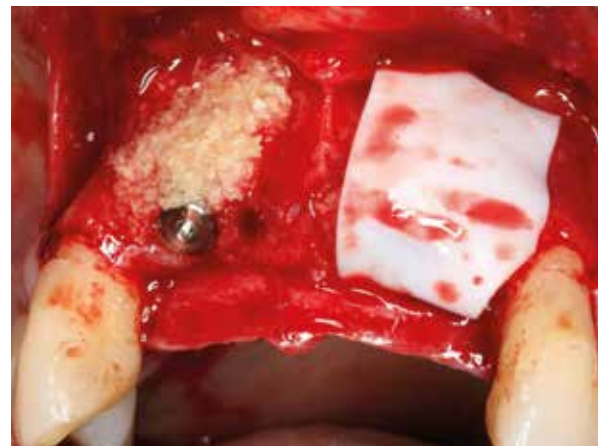1 Initial situation, four incisors are missing.



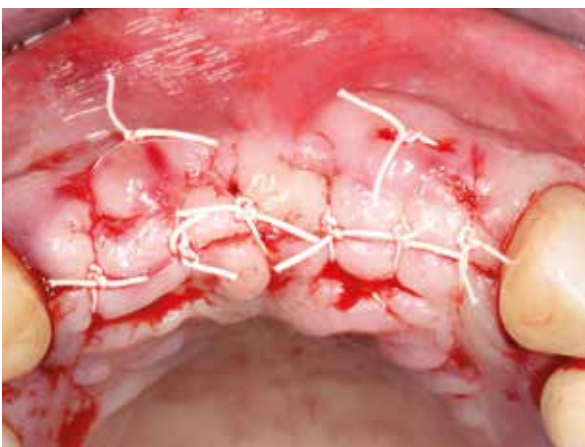
2 Elevated flap showing reduced ridge width.



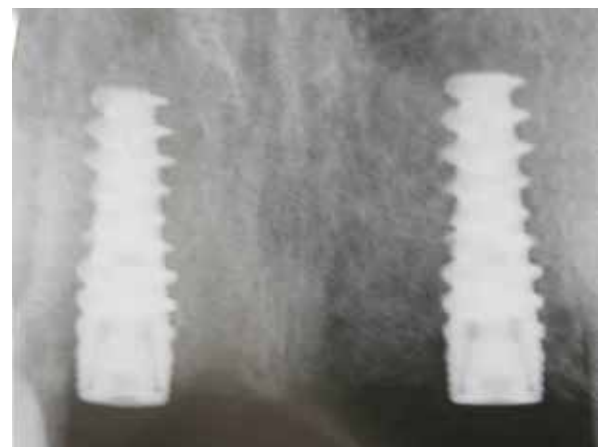3 Implants placed resulting in lateral fenestrations.



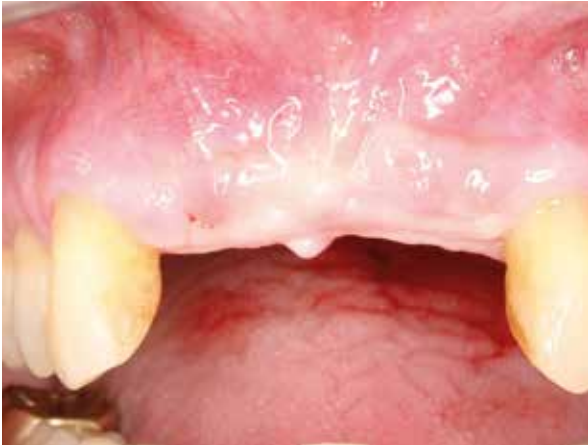4 Sites grafted with Puros Allograft Cancellous Particles and covered with a CopiOs Pericardium Membrane.



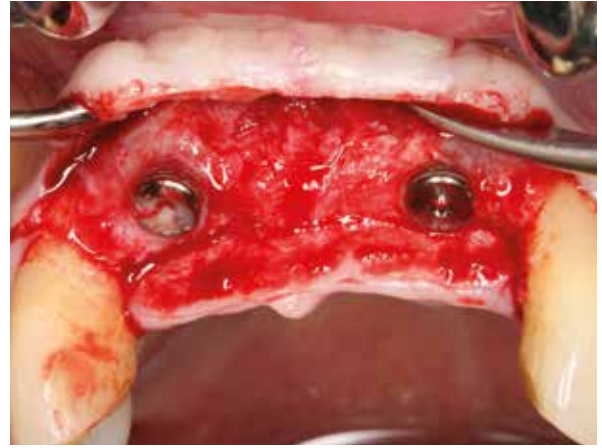
5 Wound closure.



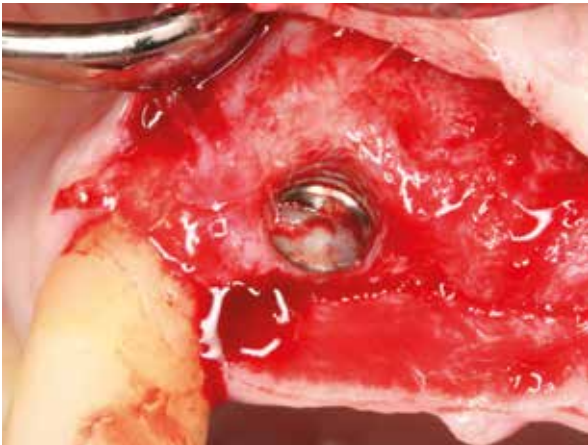
6 Radiograph taken after implant placement.



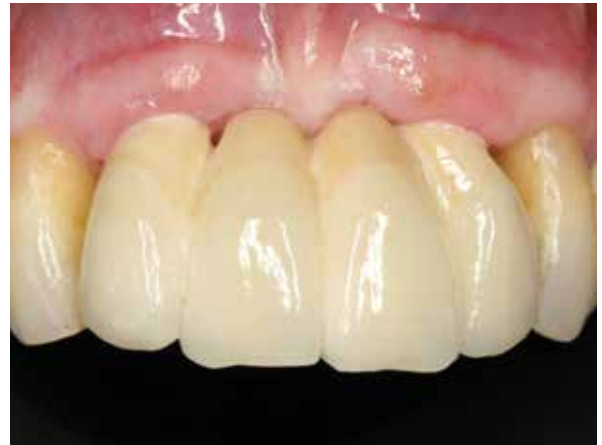7 Soft tissue, 4 months post-op.



8 Re-entry 4 months post-op, newly formed bone on implants.



9 Implant site [12], newly formed bone covering the implant.



10 Screw-retained fixed partial denture.

Clinical photographs courtesy of Dr O. Richter. Individual results may vary.

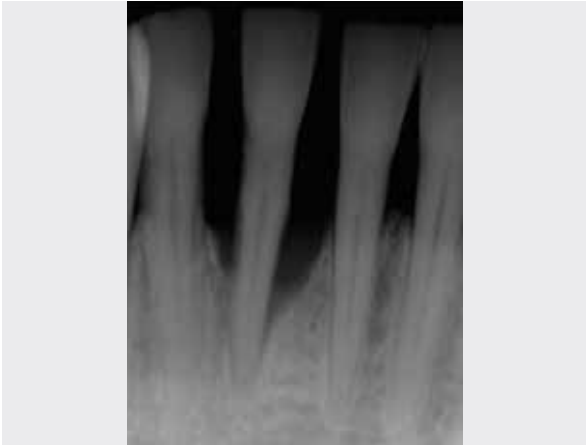
CASE 5 Delayed Implant Placement And Vertical Augmentation, Site [43]

PRACTITIONER

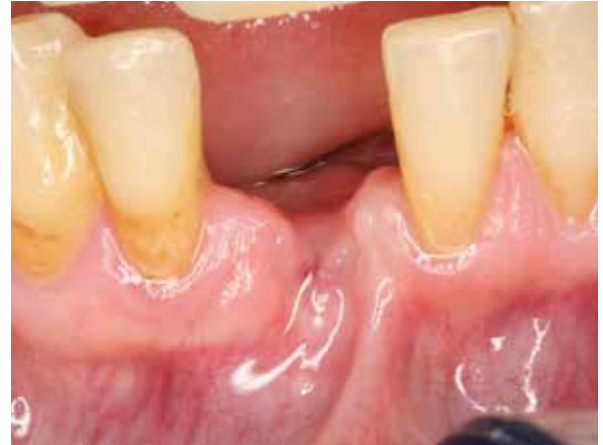Dr. O. Richter
Hamburg (Germany)

MATERIAL

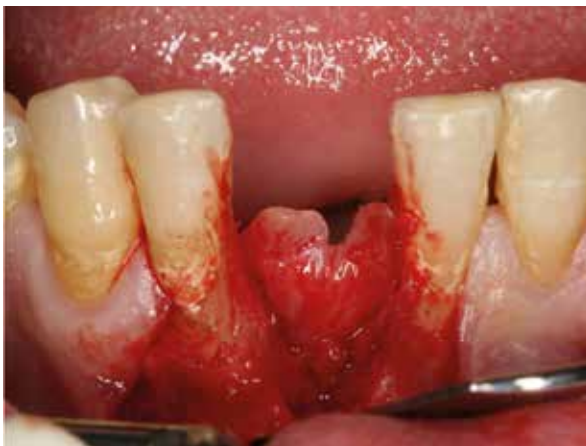- Puros Allograft Cancellous Particles 0.25–1 mm, 1 cc
- CopiOs Pericardium Membrane 15 x 20 mm



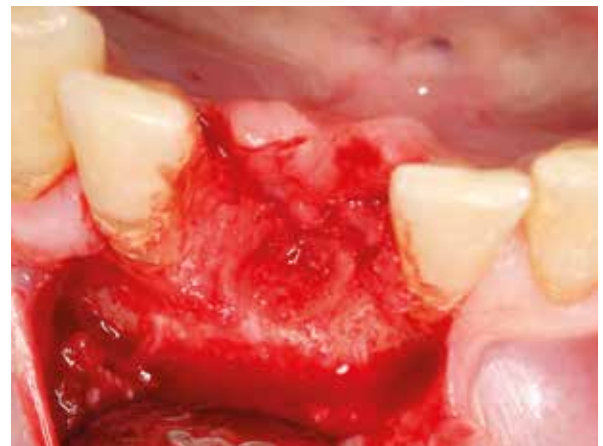1 Radiograph of initial situation showing vertical bone loss site [43].



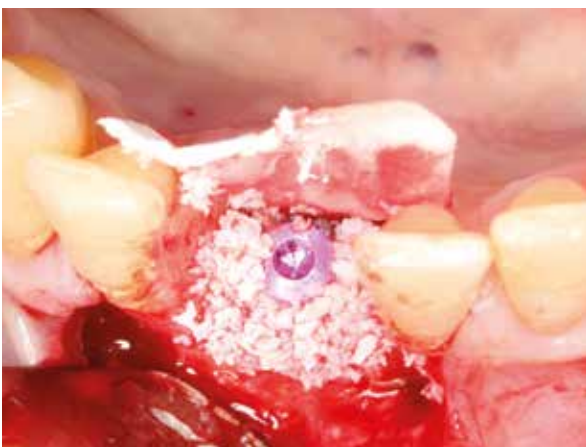2 Healed soft-tissue situation after extraction.



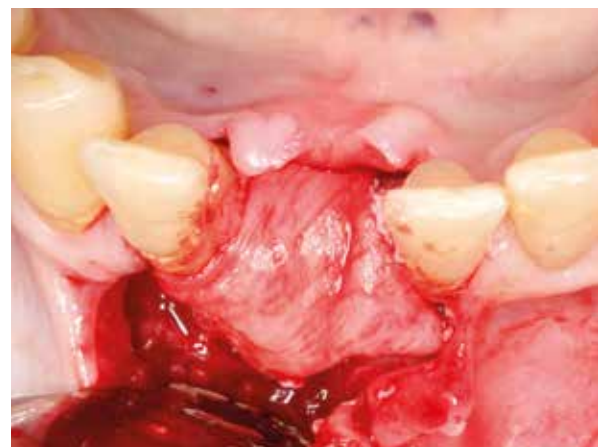3 Elevated flap revealing one wall, vertical bone defect.



4 Hard-tissue situation, occlusal view.

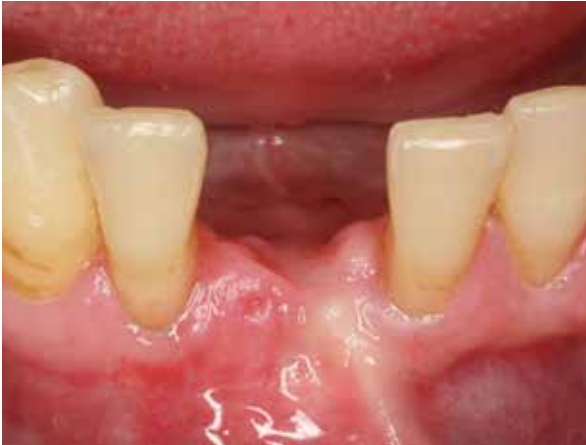

5 Implant placed and gaps filled with Puros Allograft Cancellous Particles.

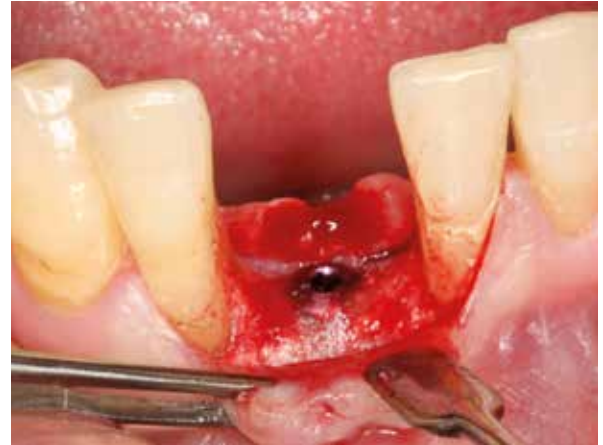

6 Covered with a CopiOs Pericardium Membrane.

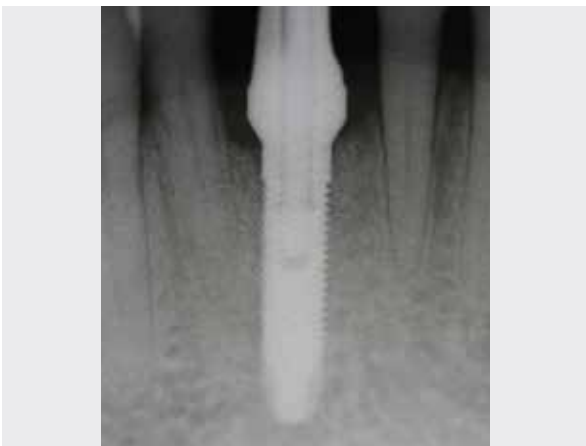4 YEAR FOLLOW-UP



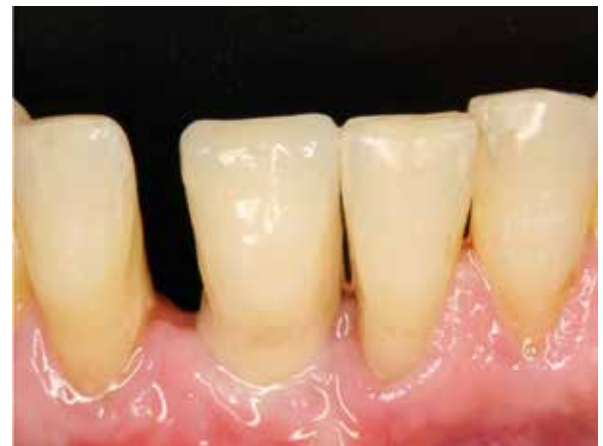7 Soft-tissue, 4 months post-op.



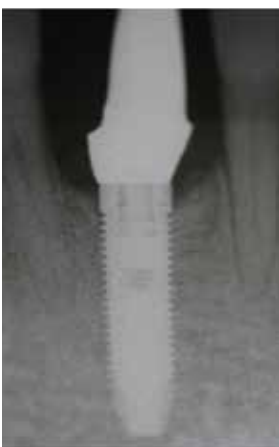
8 Re-entry 4-months post-op.



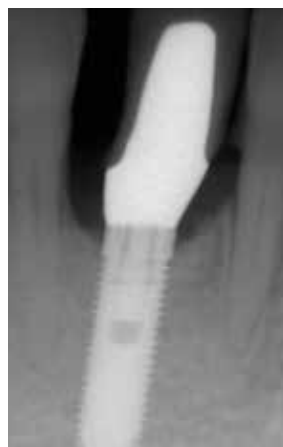
9 Radiograph taken 4 months after implant placement.



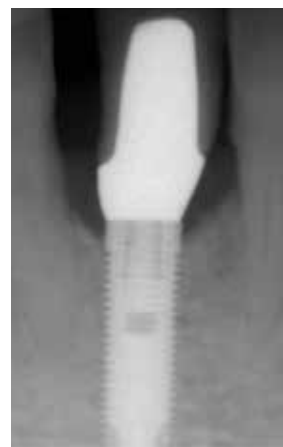
10 Definitive prosthetic restoration.



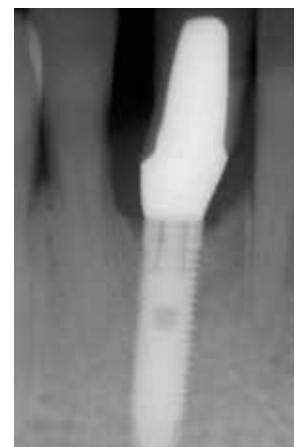11 Radiograph taken 8 months after implant placement.



12 Radiograph taken 12 months after implant placement.



13 Radiograph taken 24 months after implant placement.



14 Radiograph taken 48 months after implant placement, stable bone conditions.

Clinical photographs courtesy of Dr O. Richter. Individual results may vary.

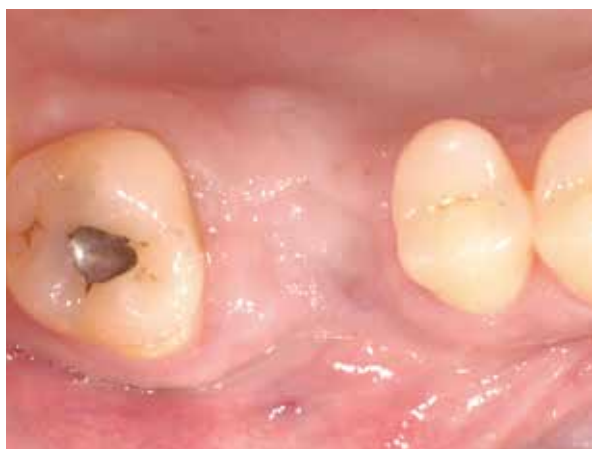CASE 6 Lateral Augmentation Prior To Implantation Site [16] With Xenogeneic Bone Substitute, Histomorphometric Analysis

PRACTITIONER

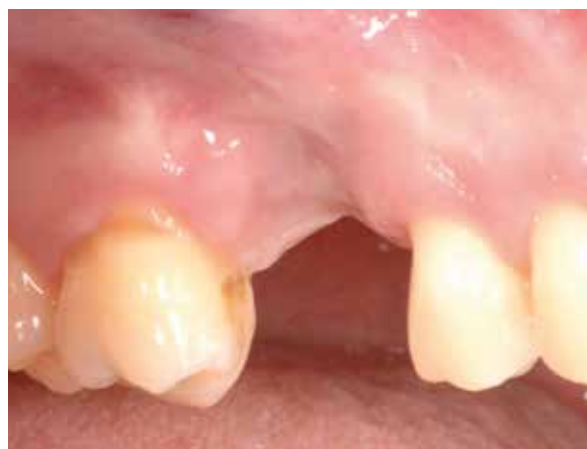Dr. K. Fischer
University of Witten/Herdecke (Germany)

MATERIAL

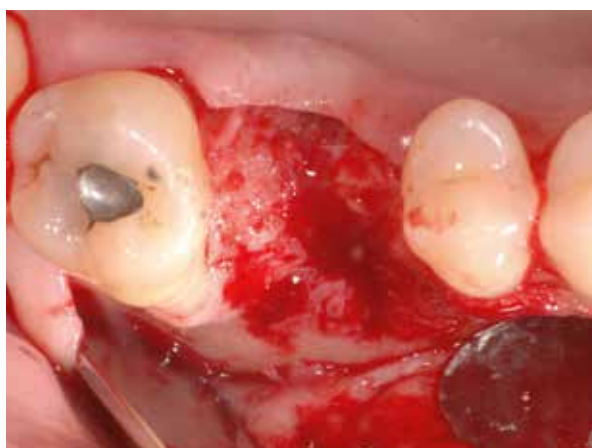- CopiOs Xenograft Cancellous Particles 0.25–1 mm, 2 cc
- CopiOs Pericardium Membrane 20 x 30 mm



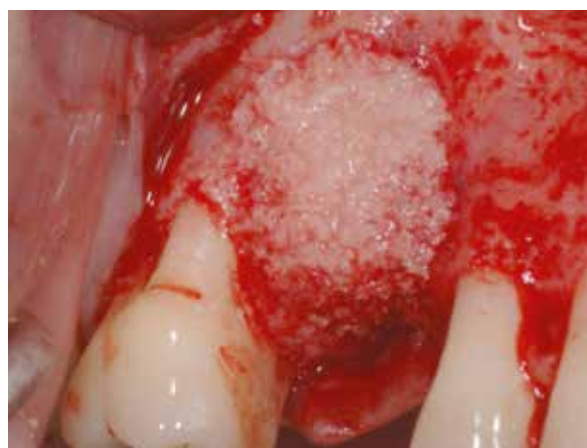1 Initial situation showing horizontal deficiency, occlusal view.



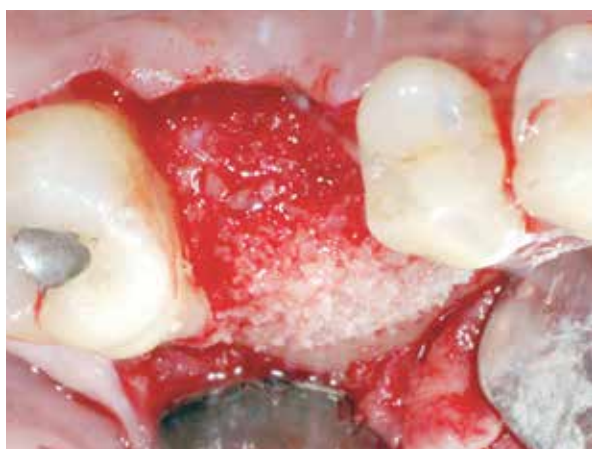2 Initial situation showing vertical deficiency, lateral view.



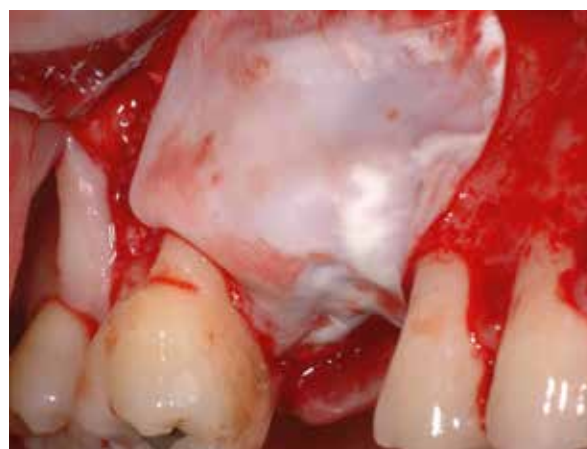3 Bony defect after flap elevation.



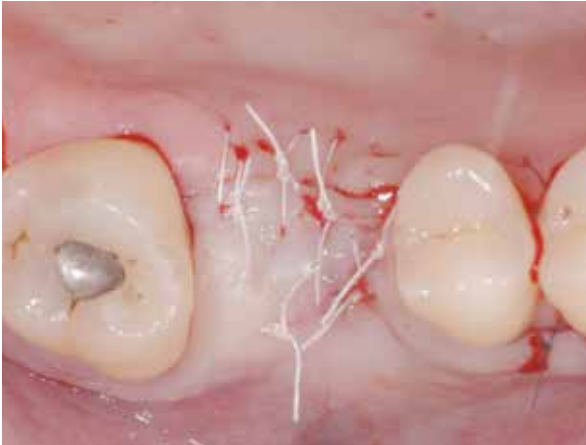4 Augmentation with CopiOs Xenograft Cancellous Particles, lateral view.



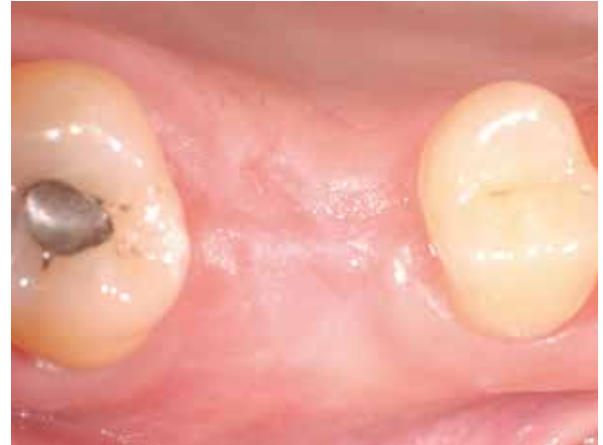5 CopiOs Xenograft Cancellous Particles in place, occlusal view.



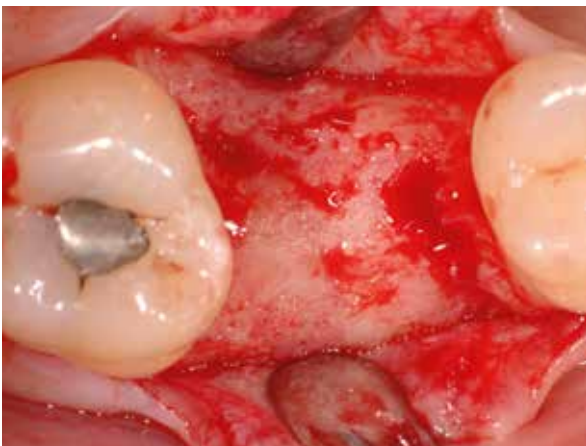6 Covered with a CopiOs Pericardium Membrane.



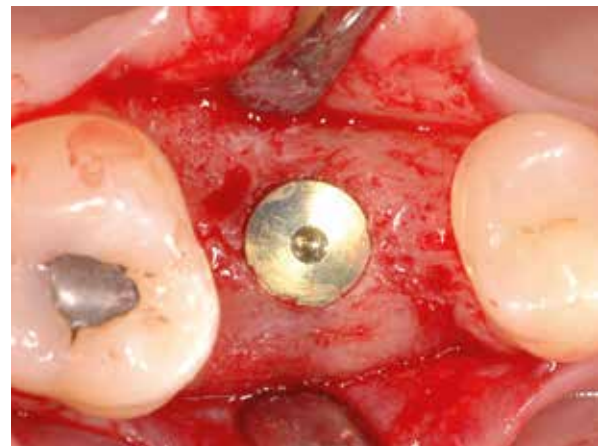7 Wound closure.



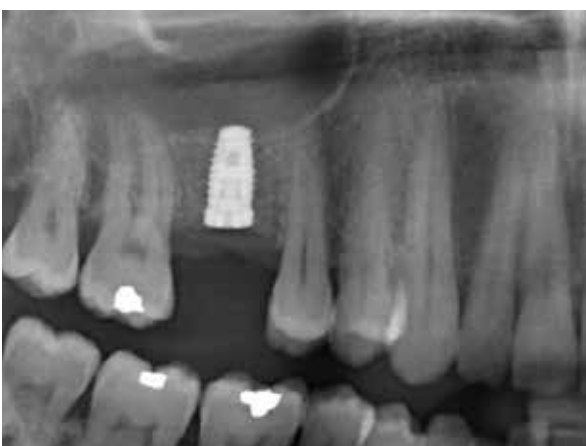8 Soft-tissue situation and contour 6-months post-operative.



9 Bony situation at re-entry 6 months post-op. Visually vital bone with well integrated graft material.



10 Implant in place.



11 Radiograph taken after implant placement.

[Histology on next page >](#)

Clinical photographs courtesy of Dr K. Fischer. Individual results may vary.

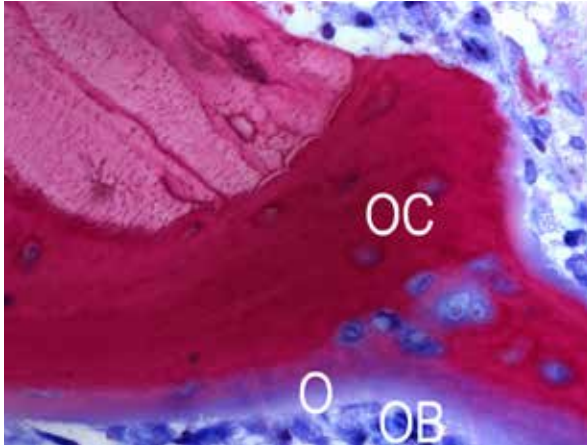
CASE 6 Lateral Augmentation Prior Implantation Site [16] With Xenogeneic Bone Substitute, Histomorphometric Analysis

PRACTITIONER

Dr. K. Fischer
University of Witten/Herdecke (Germany)

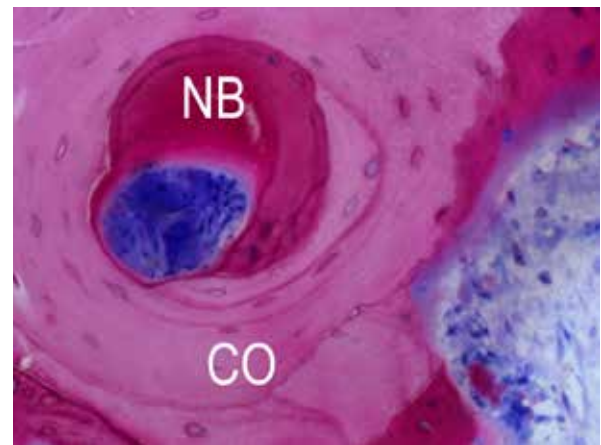
MATERIAL

- CopiOs Xenograft Cancellous Particles 0.25–1 mm, 2 cc
- CopiOs Pericardium Membrane 20 x 30 mm



HISTOLOGICAL CROSS-SECTION

(non-decalcified thin section), 400-fold: healing time 6 months; osteoblasts (OB, blue) produce osteoid (O, purple rim) and osteocytes (OC) immured in new bone (purple); residual CopiOs Xenograft Cancellous Particles (reddish purple).



HISTOLOGICAL CROSS-SECTION

(non-decalcified thin section), 200-fold: healing time 6 months; new osteon formation within CopiOs Xenograft Cancellous Particles (CO) and new bone formation (NB).

NOTE:

Histological analysis by Dr H. Nagursky, University of Freiburg.



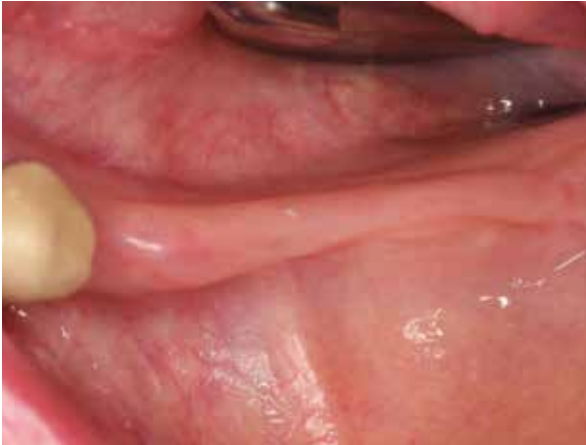CASE 7 Lateral Augmentation Prior Implantation Site [34-37] With Xenogeneic Bone Substitute

PRACTITIONER

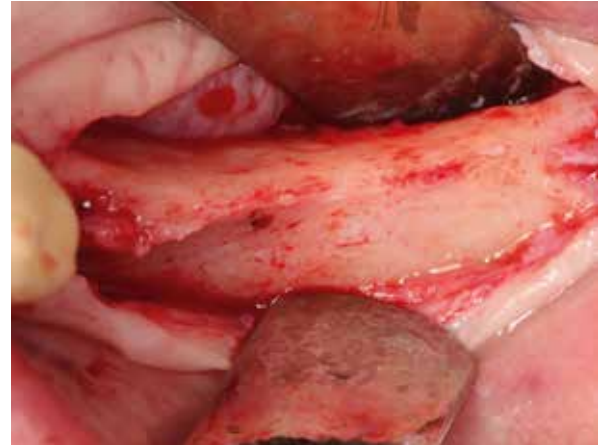
Prof. S. Fickl,
University of Würzburg (Germany)

MATERIAL

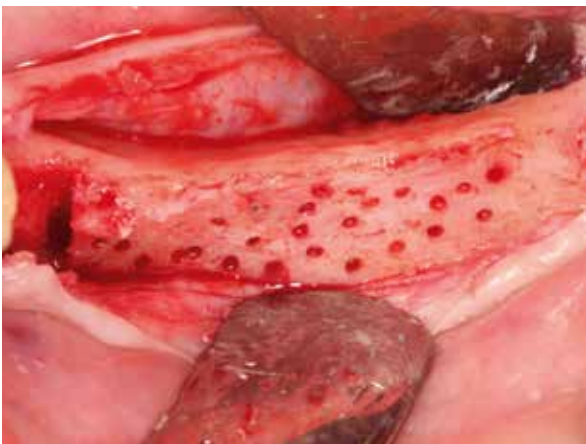- CopiOs Xenograft Cancellous Particles 0.25–1 mm, 2 cc
- Cytoplast Ti-250, 25 x 30 mm dPTFE membrane



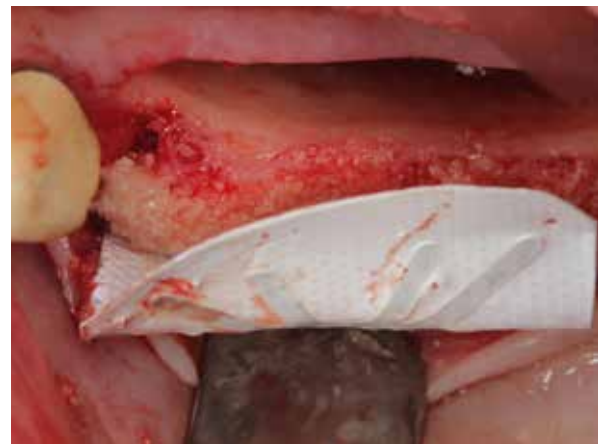
1 Initial situation, narrow ridge left mandible, occlusal view.



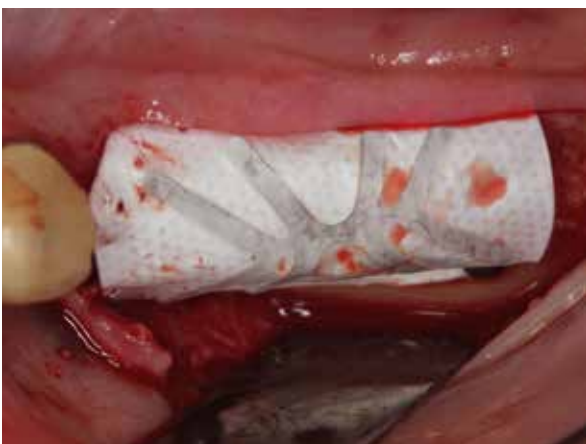2 Narrow ridge.



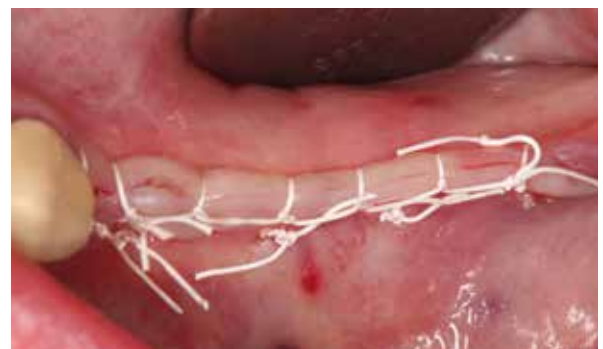3 Perforated cortical bone to induce bleeding.



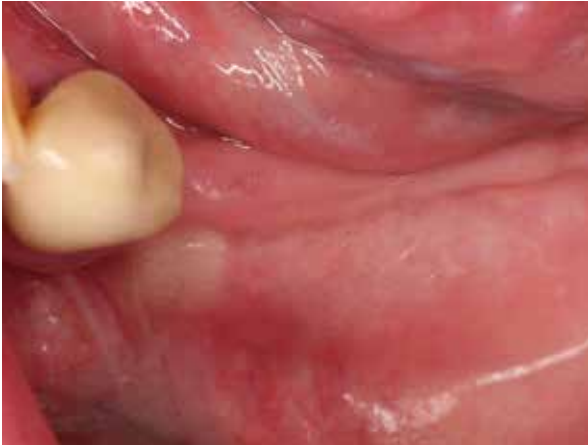4 Augmentation with CopiOs Xenograft Cancellous Particles and stabilization with a dPTFE membrane.



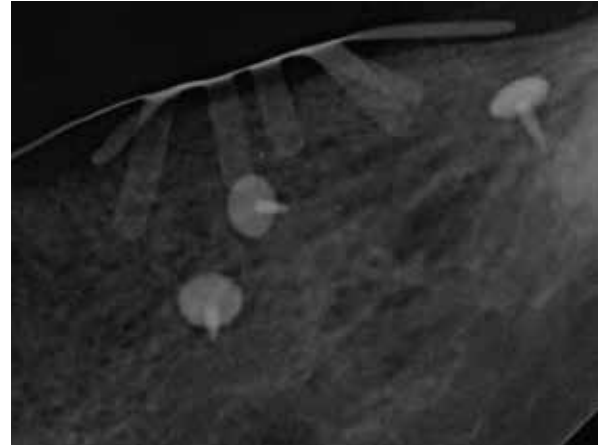
5 Titanium-reinforced dPTFE membrane in place.



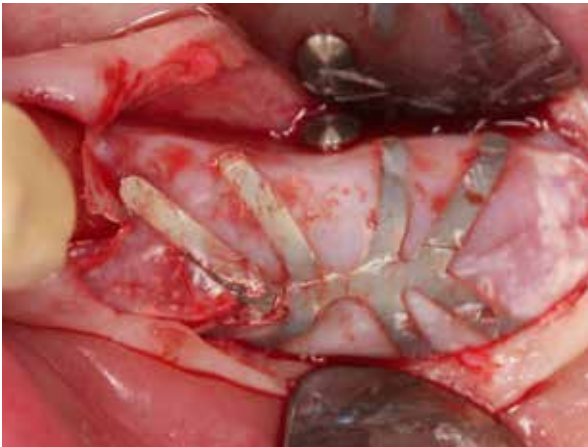
6 Wound closure.



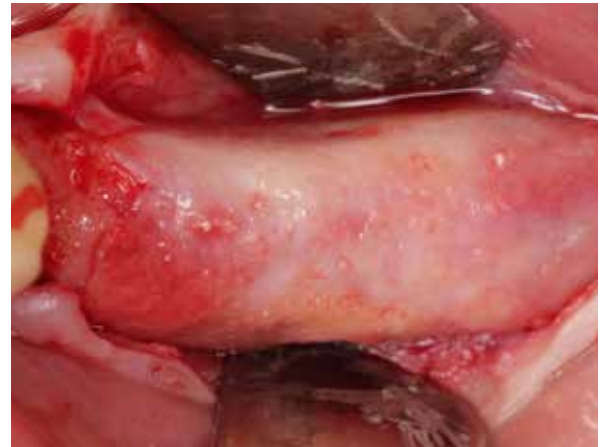7 Soft tissue, 5-months post-operative.



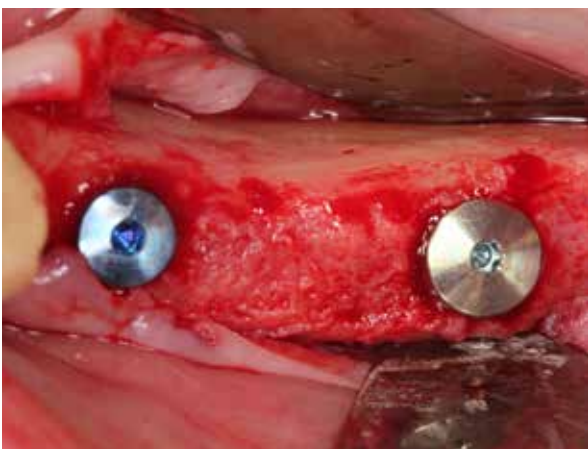
8 5 months post-op.




9 Re-entry 5-months post-op.



10 Bony situation at re-entry 5 months post-op. Visually vital bone with well integrated graft material.



11 Implants in place.



12 Radiograph taken after implant placement.

Clinical photographs courtesy of Dr S. Fickl. Individual results may vary.

PROSPECTIVE RANDOMIZED CLINICAL TRIAL

Augmentation Of Facial Dehiscences On Implant Surfaces With Puros Allograft Particles Effect Of Covering With a CopiOs Pericardium Membrane

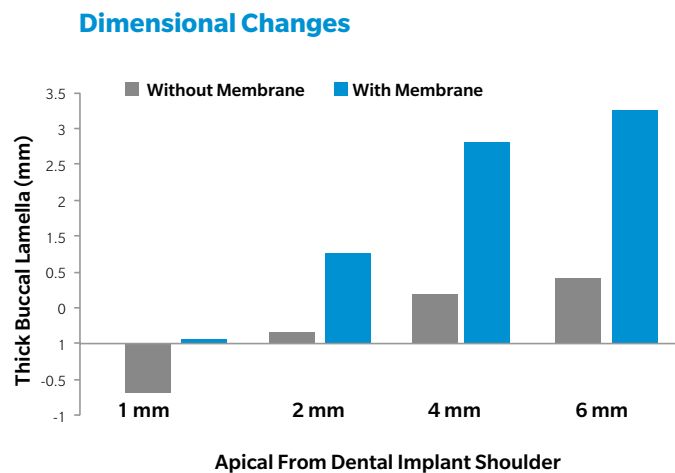
Fu JH et al. A randomized clinical trial evaluating the efficacy of the sandwich bone augmentation technique in increasing buccal bone thickness during implant placement surgery: I. Clinical and radiographic parameters. Clin Oral Implants Res (2014) 25:458-67.

Study Design

Patients (n=26) with an anterior maxillary defect, received implants (TSV[®] with machined rim). All implants were inserted primary stable (≥ 35 Ncm). Due to missing bone at the buccal lamellae implants threads were not fully covered by bone. These dehiscences were grafted using a defined quantity of Puros Allograft particles 0.25–1 mm and then either covered with a CopiOs Pericardium Membrane (test group, n=13) and closed, or closed without membrane (control group, n=13). At re-entry after 6 months, percentage of defect fill and the thickness of the buccal lamellae have been determined.

Results

Grafting with Puros Allograft Particles in combination **with a CopiOs Pericardium Membrane (test group)** leads to a significant increase in the width of the buccal lamellae compared to the control group without membrane. Defect fill was 90.6% in the test group and 75.7% in the control group.



Conclusion

Use of a CopiOs Pericardium Membrane reduces resorption of buccal plate compared with defects grafted without a membrane.

Lateral Augmentation With Puros Allograft Particles: Histology And Histomorphometry

Solakoglu Ö. Präimplantologische laterale Kieferkammaugmentation mit allogenem Knochenersatzmaterial: A case series with histological and histomorphometric documentation. Zeitschrift für Zahnärztliche Implantologie (2012) 27:24-32.

Study Design

In the case series (n=5) lateral bone defects were grafted with Puros Allograft Cancellous Particles and covered with a CopiOs Pericardium Membrane. After a healing time of four, six or twelve months, biopsies were taken from the graft site prior to implant placement and histological and histomorphometric analysis was performed.

Results

Ridge widenings can be reliably obtained by lateral **augmentation with Puros Allograft Cancellous Particles and a CopiOs Pericardium Membrane**. All implants achieved primary stability at the time of placement. Histomorphometry results show that the bone graft is fully remodeled after a period of six and twelve months. **Active osteoclasts and osteoblastic cells were detected on the surface of the grafting material. The new bone is vital, and depending on the healing period, free of residual graft material.**

Conclusion

Patient	Biopsy Sample (Mo)	Bone (%)	Connective Tissue (%)	Residual Graft Material (%)
1	4	3.54	34.68	61.79
2	4	27.28	65.18	7.54
3	6	45.68	47.62	0
4	12	69.00	31.00	0
5	12	94.10	5.90	0

This procedure and materials described above can achieve promising results in lateral ridge augmentation.

PROSPECTIVE STUDY

Defect Fill With CopiOs Xenograft Cancellous Particles Compared To Xenogenic Materials

Thorwarth M et al. Evaluation of substitutes for bone: comparison of microradiographic and histological assessments. Br J Oral Max Surg (2007) 45:41-47.

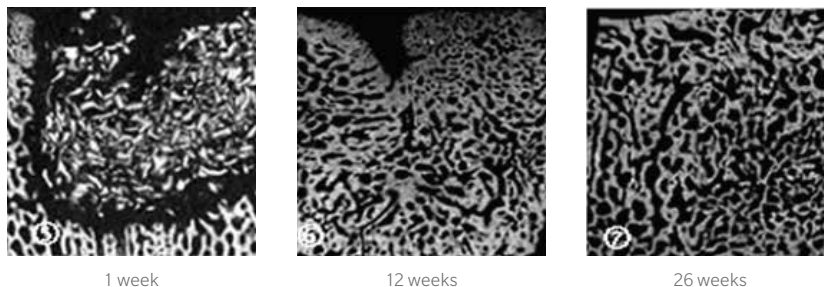
Study Design

Defined defects were created in the calvaria of pigs (diameter 10 mm and depth 10 mm). The defects were grafted with a variety of bone substitutes (Osteograft[®]/N-300, Dentsply; Bio-Oss, Geistlich Pharma AG; Aligpore[™], Dentsply; Navigraft[™], Tutogen Medical GmbH) followed by soft-tissue closure. Control groups were one dummy and one defect filled with autogenous bone. Two animals were sacrificed after healing periods of 1, 2, 4, 8, 12 and 26 weeks. Tissue sections from the graft site were evaluated microradiographically and the integration of each material was evaluated and quantified. Histological sections were stained with toluidine blue and quantified.

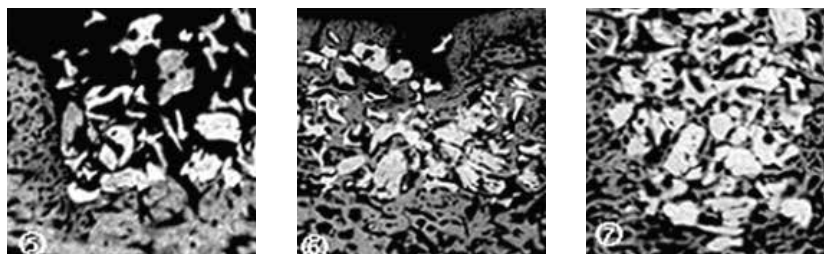
Results

Defect fill in the dummy group was incomplete after 26 weeks. The second control group (autogenous bone), exhibited full regeneration. Osteograft and Bio-Oss were surrounded by newly formed bone. After a healing period of 26 weeks, residual particles of Bio-Oss and Osteograft were detected. Aligpore was well integrated and 20% of the material was still present after 26 weeks. Navigraft (now **CopiOs Xenograft Cancellous Particles**) showed signs of initial resorption after a healing period of two weeks. After four weeks Navigraft and new bone were no longer distinguishable by microradiography. After a healing period of 26 weeks the defect had undergone complete regeneration (see illustration).

CopiOs Xenograft Particles



Bovine Xenograft*



Microradiograph of defects grafted with CopiOs Xenograft Cancellous Particles (top) and Geistlich Bio-Oss (bottom) following various healing periods. Note the complete integration and defect fill after 26 weeks in the CopiOs group. In the Bio-Oss group, incomplete bone regeneration can be seen cranially and centrally.

Conclusion

CopiOs Xenograft Cancellous Particles is largely converted to vital bone within 26 weeks resulting in fully regenerated defects.

* Bio-Oss from Geistlich.

1. Block MS, Degen M. Horizontal ridge augmentation using human mineralized particulate bone: Preliminary results. *J Oral Maxillofac Surg* (2004) 62:67-72.
2. Minichetti JC, D'amore JC, Hong AY. Three-year analysis of Tapered Screw-Vent implants placed into extraction sockets grafted with mineralized bone allograft. *J Oral Implantol* (2005) 31:283-93.
3. Block MS. Horizontal ridge augmentation using particulate bone. *Atlas Oral Maxillofac Surg Clin North Am* (2006) 14:27-38.
4. Plöger M, Schau I. Rekonstruktion von Kieferkammdefekten mittels allogener Spongiosa. *Implantologie Zeitung* (2006) 10:16-18.
5. Park SH, Wang HL. Management of localized buccal dehiscence defect with allografts and acellular dermal matrix. *Int J Periodont Rest Dent* (2006) 26:589-95.
6. Schau I, Plöger M. Sofortimplantation und laterale Augmentation mit humanem Knochenersatzmaterial. *Dentale Implantologie & Parodontologie* (2006) 10:174-179.
7. Steigmann M. Barrieremembran zur Augmentation horizontaler Alveolarkammdefekte. *Zahnarzt & Praxis* (2007) 10:476-479.
8. Park SH, Lee KW, Oh TJ, Misch CE, Shotwell J, Wang HL. Effect of absorbable membranes on sandwich bone augmentation. *Clin Oral Implants Res* (2008) 19:32-41.
9. Le BT, Woo I. Alveolar cleft repair in adults using guided bone regeneration with mineralized allograft for dental implant site development: a report of 2 cases. *J Oral Maxillofac Surg* (2009) 67:1716-1722.
10. Lee A, Brown D, Wang HL. Sandwich bone augmentation for predictable horizontal bone augmentation. *Implant Dent* (2009) 18:282-90.
11. Burger BW. Use of ultrasound-activated resorbable poly-d-l-lactide pins (sonicpins) and foil panels (resorb-x) for horizontal bone augmentation of the maxillary and mandibular alveolar ridges. *J Oral Maxillofac Surg* (2010) 68:1656-1661.
12. Le B, Rohrer MD, Prasad HS. Screw "Tent-Pole" grafting technique for reconstruction of large vertical alveolar ridge defects using human mineralized allograft for implant site preparation. *J Oral Maxillofac Surg* (2010) 68:428-435.
13. Tolstunov L, Chi J. Alveolar ridge augmentation: comparison of two socket graft materials in implant cases. *Compendium Of Continuing Education In Dentistry* (2011) 32:E16-E124.
14. Fu JH, Wang HL. Horizontal bone augmentation: the decision tree. *Int J Periodontics Restorative Dent* (2011) 31:429-36.
15. Solakoglu Ö. Präimplantologische laterale Kieferkammaugmentation mit allogener Knochenersatzmaterial: Eine Fallserie mit histologischer und histomorphometrischer Dokumentation. *Z Zahnärztl Impl* (2012) 27:24-32.
16. Steigmann M, Salama M, Wang H-L. Periosteal pocket flap for horizontal bone regeneration: a case series. *Int J Periodont Rest Dent*. (2012) 32:311-320.
17. Fu J-H, Wang H-L. The sandwich bone augmentation technique. *Clinical Advances in Periodontics* (2012) 2:172-177.
18. Sterio TW, Katancik JA, Blanchard SB, Xenoudi P, Mealey BL. A prospective, multicenter study of bovine pericardium membrane with Allograft Cancellous Particles for localized alveolar ridge augmentation. *Int J Perio Rest Dent* (2013) 33:499-507.
19. Richter O. Tatort ästhetische Zone. *teamwork* (2013) 1:76-81.
20. Ronda M, Rebaudi A, Torelli L, Stacchi C. Expanded vs. dense polytetrafluoroethylene membranes in vertical ridge augmentation around dental implants: a prospective randomized controlled clinical trial. *Clin Oral Implants Res* (2014) 25:859-66.
21. Fu JH, Oh TJ, Benavides E, Rudek I, Wang HL. A randomized clinical trial evaluating the efficacy of the sandwich bone augmentation technique in increasing buccal bone thickness during implant placement surgery: I. Clinical and radiographic parameters. *Clin Oral Implants Res* (2014) 25:458-67.
22. Spinato S, Galindo-Moreno P, Zaffe D, Bernardello F, Soardi CM. Is socket healing conditioned by buccal plate thickness? A clinical and histologic study 4 months after mineralized human bone allografting. *Clin Oral Implants Res* (2014) 25:e120-6.

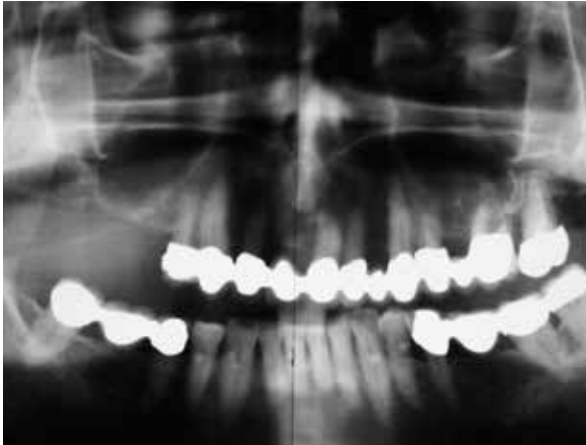CASE 1 Sinus Lift With Allogenic Bone Graft Site [15-17]

PRACTITIONER

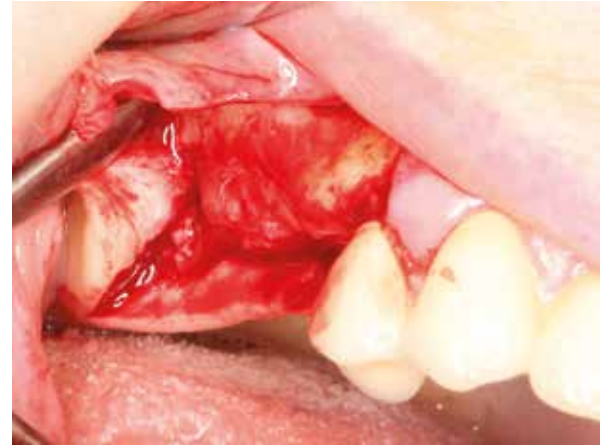Dr. O. Richter
Hamburg (Germany)

MATERIAL

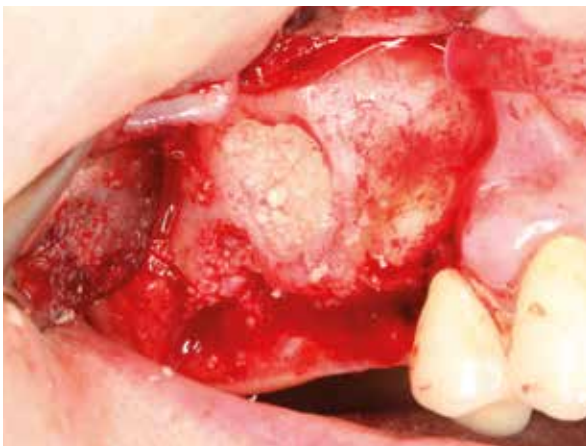- Puros Allograft Cancellous Particles 0.25–1 mm, 2 cc
- CopiOs Pericardium Membrane 15 x 20 mm



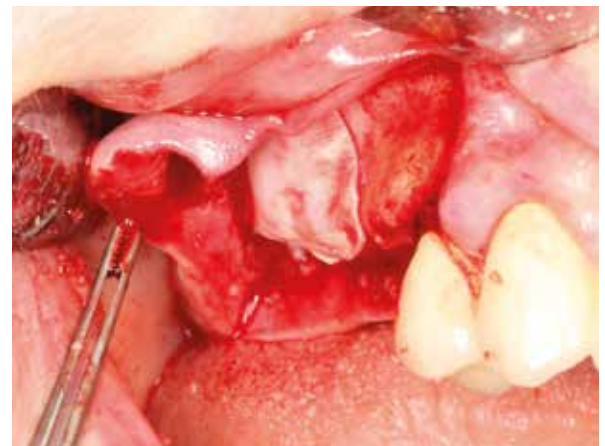1 Radiograph of initial situation showing thin sinus floor right maxilla.



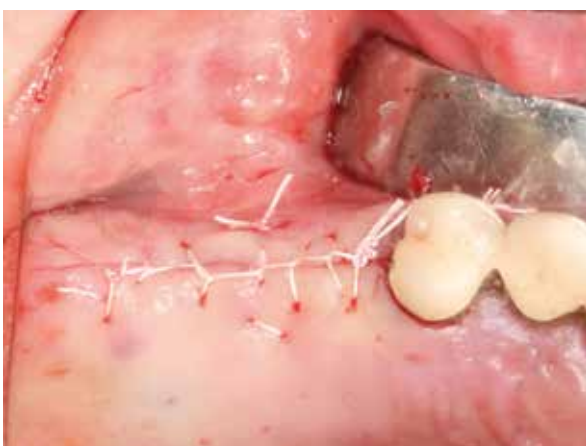2 Lateral sinus wall after raising full-thickness flap.



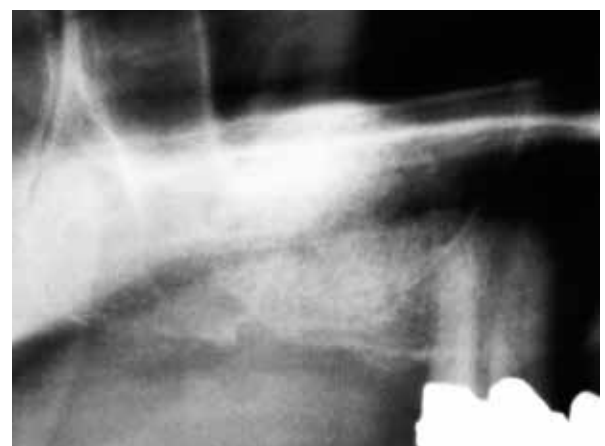3 Sinus lift using Puros Allograft Cancellous Particles.



4 CopiOs Pericardium Membrane draped over lateral window.

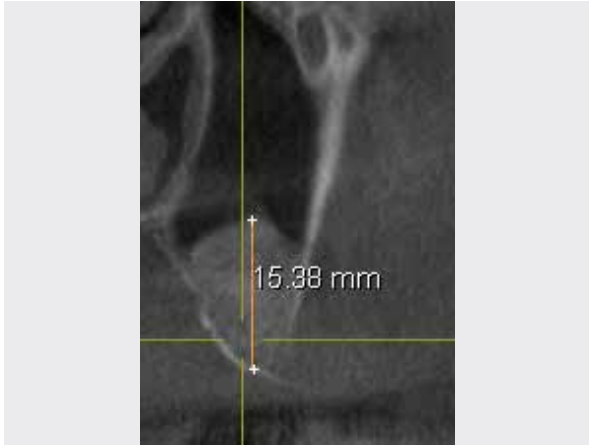


6 Wound closure.

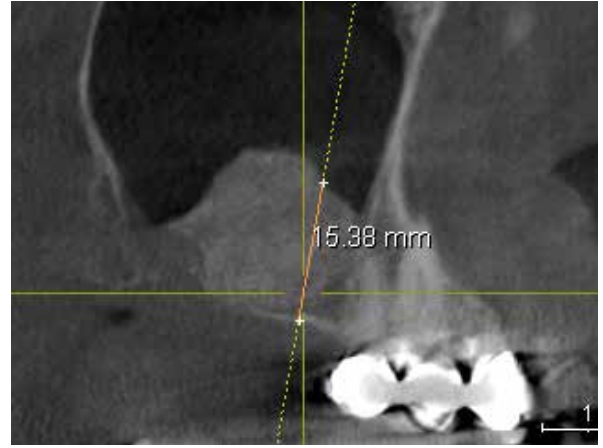

5 Post-operative radiograph.

Clinical photographs courtesy of Dr O. Richter. Individual results may vary.



7 4-months post-operative CBCT scan. sagittal cross-section, oral left, labial right.



8 4-months post-operative CBCT scan.

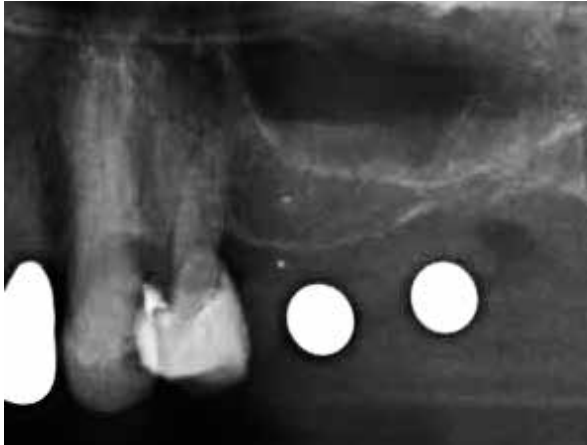CASE 2 Histological And Histomorphometric Analysis Following Sinus Lift With Allogenic Bone Graft Site [25-26]

PRACTITIONER

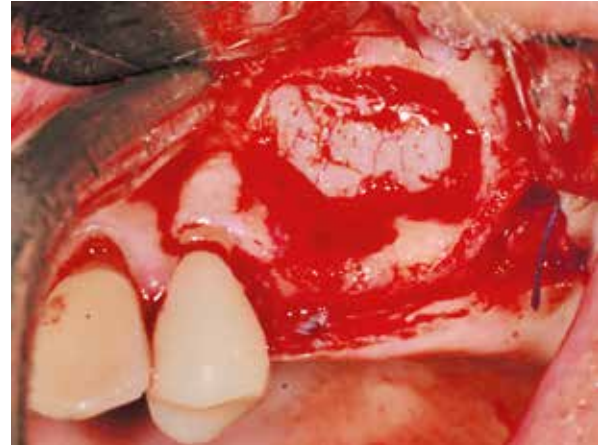
Dr. F. Conradi
Bremen (Germany)

MATERIAL

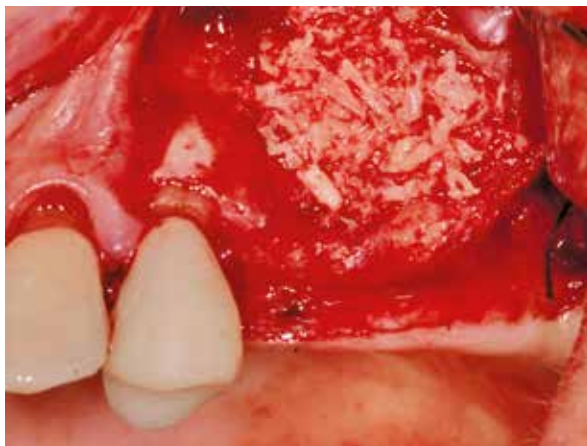- Puros Allograft Cancellous Particles 1–2 mm, 2 cc
- CopiOs Pericardium Membrane 20 x 30 mm



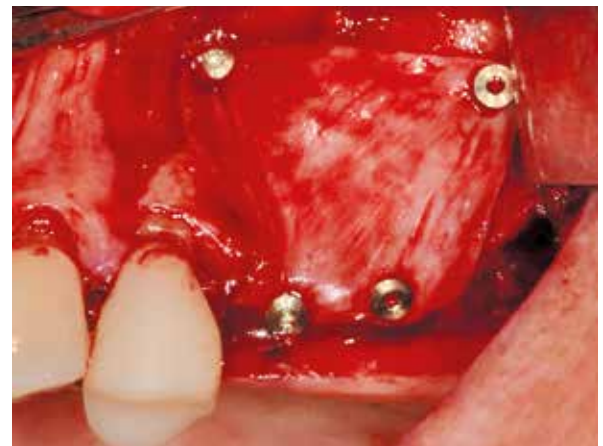1 Radiograph of initial situation, showing thin sinus floor maxilla left.



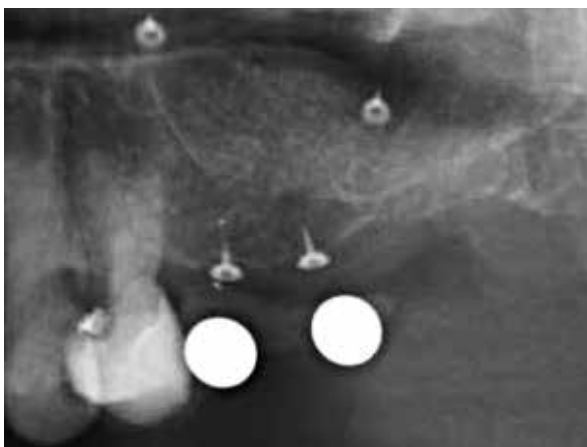2 Lateral approach was used to elevate the Schneiderian membrane.



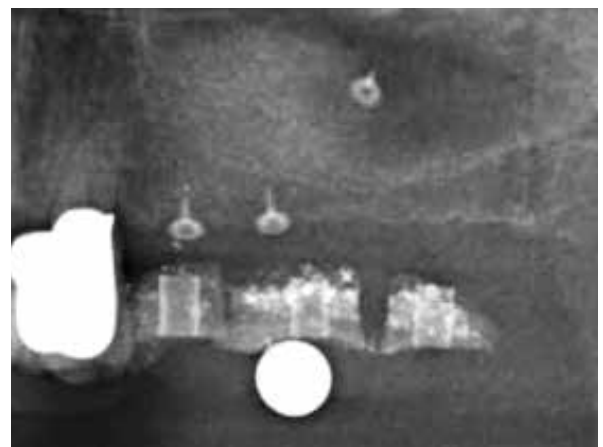
3 Puros Allograft Cancellous Particles in place.



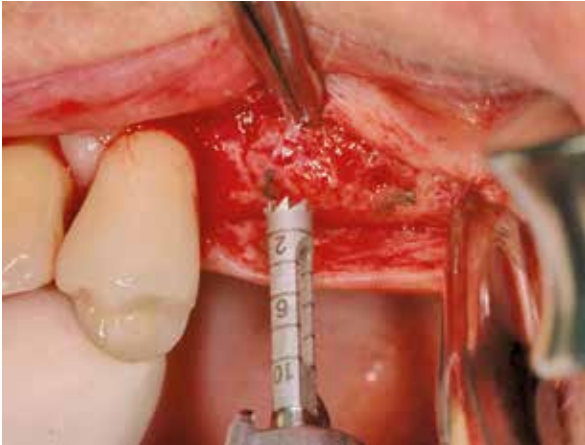4 CopiOs Pericardium Membrane fixed with pins.



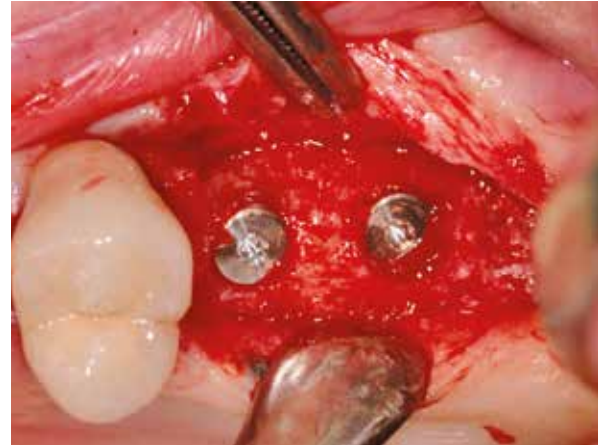
5 Post-operative radiograph.




6 5-months post-operative radiograph with surgical guide.



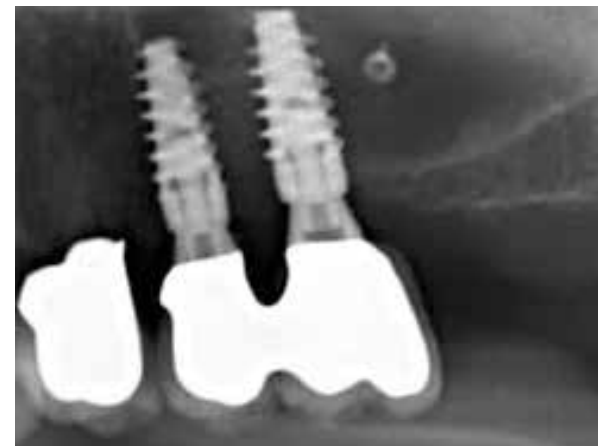7 Re-entry 5-months post-op, collection of biopsy.



8 Implants placed in grafted sites.



9 Post-placement radiograph.



10 Radiograph taken after prosthetic restoration.

Clinical photographs courtesy of Dr F. Conradi. Individual results may vary.

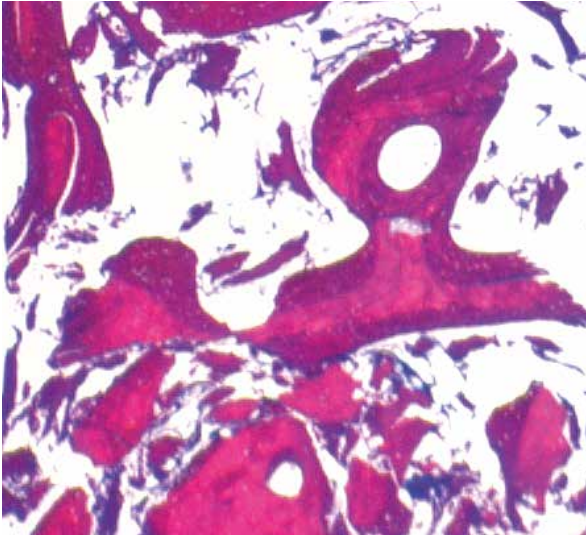
CASE 2 Histological And Histomorphometric Analysis Following Sinus Lift With Allogenic Bone Graft Site [25-26]

PRACTITIONER

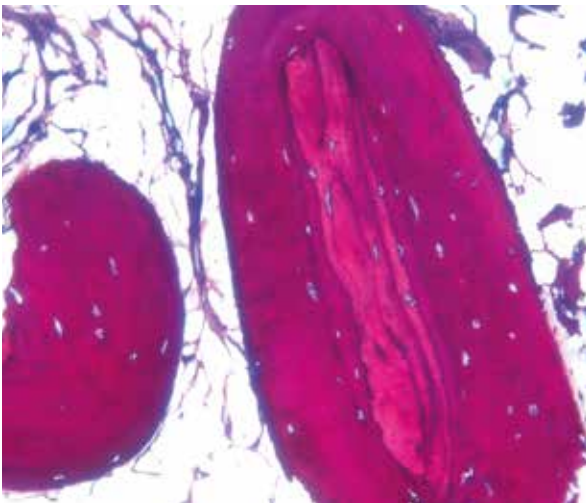
Dr. F. Conradi
Bremen (Germany)

MATERIAL

- Puros Allograft Cancellous Particles 1–2 mm, 2 cc
- CopiOs Pericardium Membrane 20 x 30 mm



11 Histological cross-section (non-decalcified thin section) 50 times: Healing period 5 months. Production of vital, newly formed bone (mauve) and residual Puros Particles (reddish purple) are clearly discernible.



12 Histological cross-section (non-decalcified thin section) 200 fold: Healing period 5 months. Newly formed bone (mauve) encloses Puros Cancellous Particle (reddish purple).

Histomorphometric Analysis Of Biopsy

New Bone Formation [%]	Connective Tissue/ Bone Marrow [%]	Residual Graft Material [%]
34.42	62.10	3.48

Histological and histomorphometric analysis by M. Hasper, HIK Hannover.



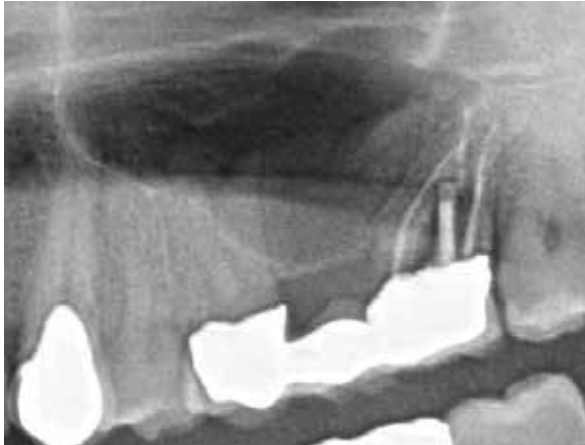CASE 3 Histological Analysis Following Sinus Lift With Xenogeneic Bone Substitute, Site [26-27]

PRACTITIONER

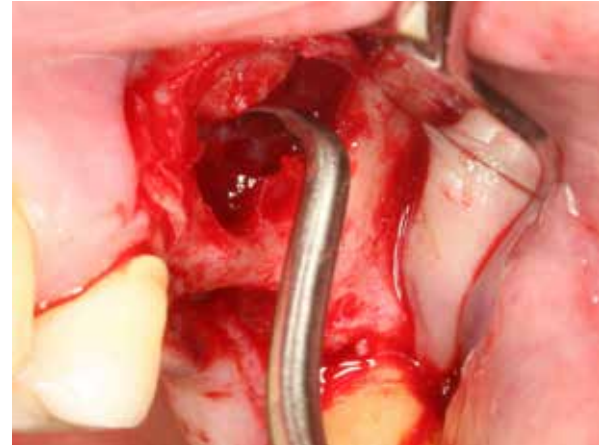
Dr. O. Richter
Hamburg (Germany)

MATERIAL

- CopiOs Xenograft Cancellous Particles 1–2 mm, 2 cc
- CopiOs Pericardium Membrane 20 x 30 mm



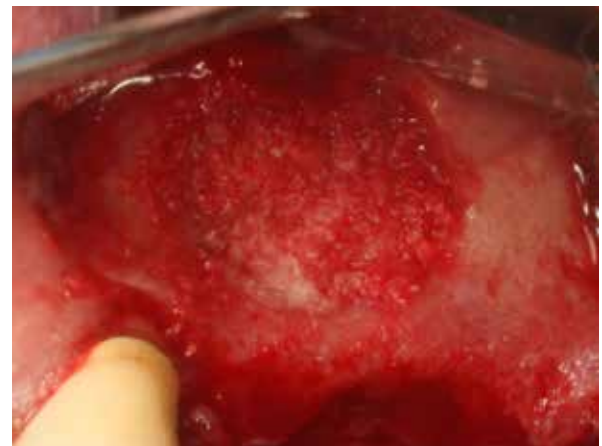1 Radiograph of severely pneumatized sinus membrane and lack of ridge.



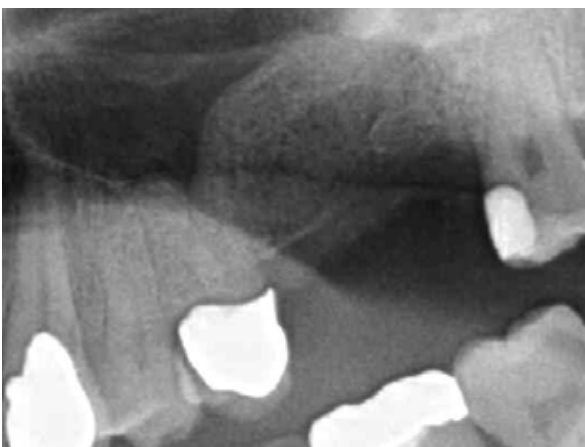2 Window created lateral approach to sinus elevation.



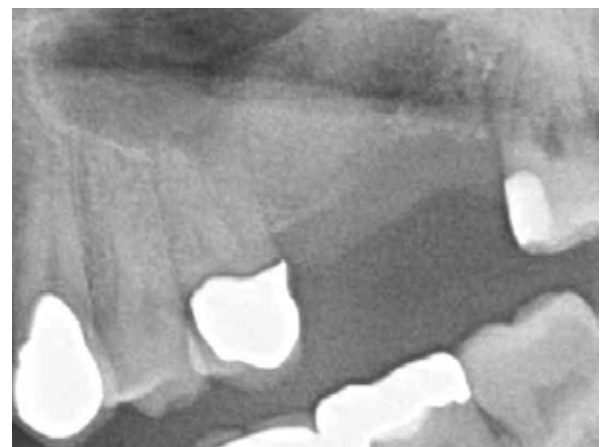3 Rehydrated CopiOs Xenograft Cancellous Particles.



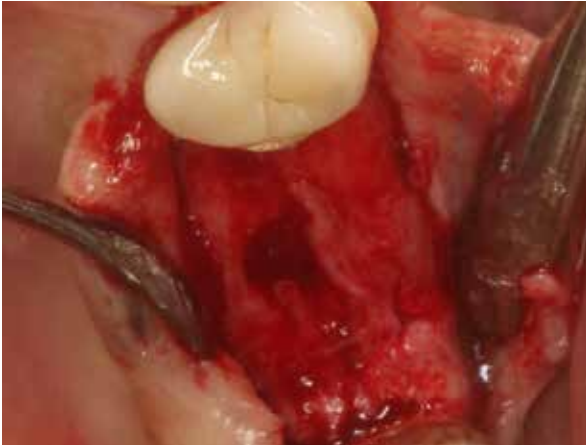4 CopiOs Xenograft Cancellous Particles in place.



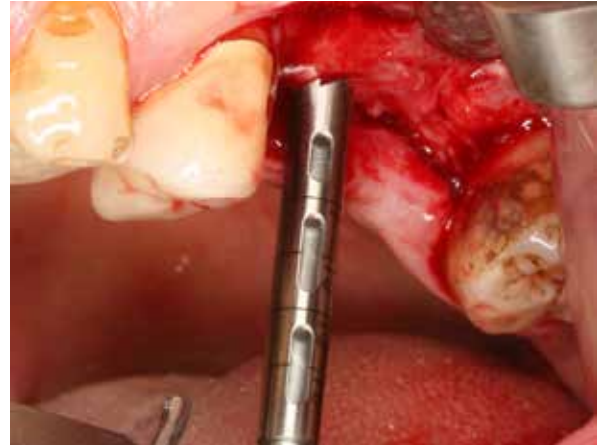5 Post-operative radiograph.



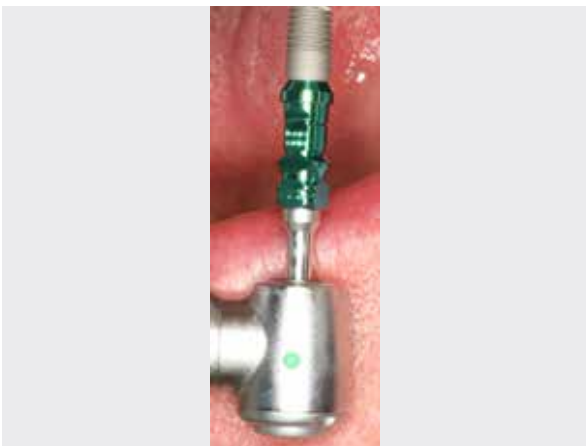
6 4-month post-operative radiograph, healing with good volume stability.



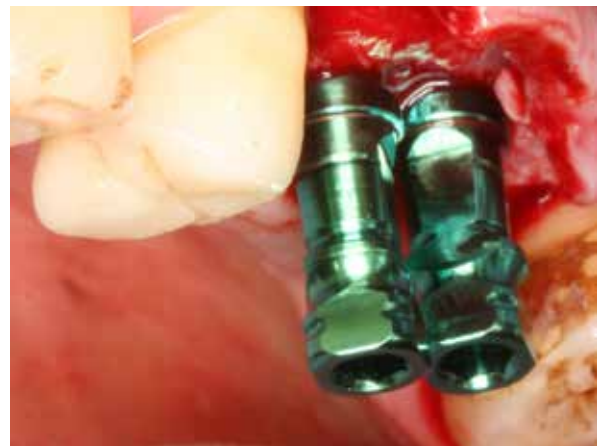7 Re-entry 4-months post-op, adequate supply of bucco/oral bone.



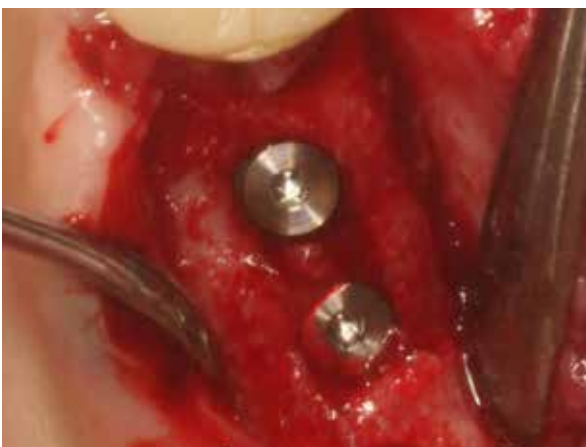8 Biopsy taken at re-entry.



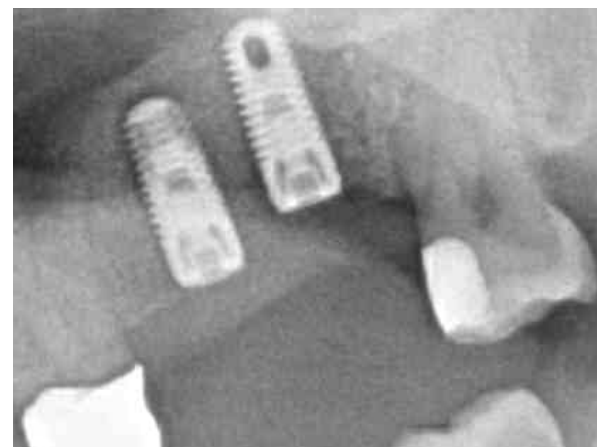
9 TSV-T Implant 4.1x10 mm.



10 TSV-T Implants in place.



11 Implants in place, occlusal view.



12 Post-placement radiograph.

Clinical photographs courtesy of Dr. O. Richter. Individual results may vary.

[Histology on next page >](#)

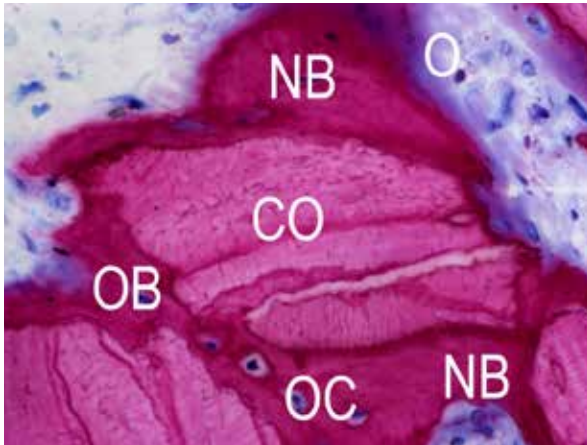
CASE 3 Histological Analysis Following Sinus Lift With Xenogeneic Bone Substitute, Site [26-27]

PRACTITIONER

Dr. O. Richter
Hamburg (Germany)

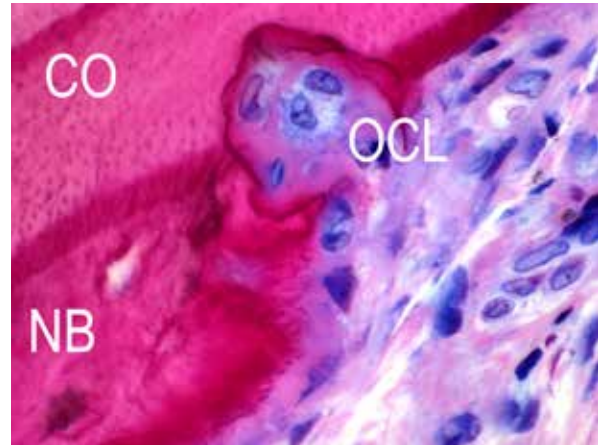
MATERIAL

- CopiOs Xenograft Cancellous Particles 1–2 mm, 2 cc
- CopiOs Pericardium Membrane 20 x 30 mm



HISTOLOGICAL CROSS-SECTION

(non-decalcified thin section), 400-fold : healing period 4 months; osteoblasts (OB, blue) produce osteoid (O, purple rim); Newly formed bone (NB, mauve) and osteocytes (OC) immured in new bone; residual CopiOs Xenograft Cancellous Particles (CO, reddish purple).



HISTOLOGICAL CROSS-SECTION

(non-decalcified thin section), 630-fold: healing period 4 months; production of vital, newly formed bone (NB, mauve) and residual particles from the CopiOs Xenograft Cancellous Particles (CO, reddish purple) and osteoclasts (OCL) are clearly discernible.

NOTE:

Histological analysis by Dr H. Nagursky, University of Freiburg.



PROSPECTIVE STUDY

Maxillary Sinus Augmentation With Puros Allograft Cancellous Particles

Maxillary Sinus Augmentation With Bio-Oss, BoneCeramic And Autologous Bone

Schmitt CM et al. Histological results after maxillary sinus augmentation with Straumann® BoneCeramic, Bio-Oss, Puros and autologous bone. A randomized controlled clinical trial. Clin Oral Implants Res (2013) 24:576-585.

Study Design

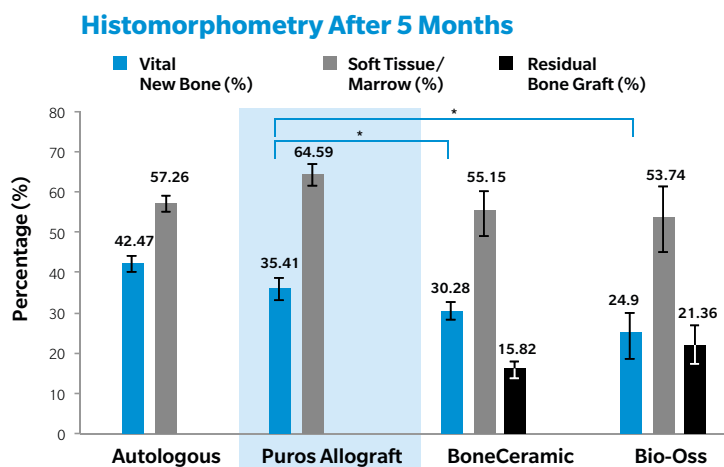
Patients (n=30) with residual bone height ≤ 4 mm in posterior maxilla were divided into four groups and maxillary sinus floor augmentations performed. The augmentations were performed with: (I) autologous bone (intraoral); (II) Puros Allograft Cancellous Particles 0.25–1 mm; (III) Straumann BoneCeramic 0.1–0.5 mm and (IV) Geistlich Bio-Oss 0.25–1 mm. At re-entry after a healing period of 5 months a total of 53 biopsies were taken and 94 implants inserted. The composition of the biopsies were subjected to a histological and histomorphometric analysis.

Results

The volume of newly formed, vital bone in the Puros Allograft group is higher than in the BoneCeramic and Bio-Oss groups.

In the Puros Allograft group, after a healing period of 5 months no residual Puros particles were quantified/detected. The percentage of non-vital residual particles found in the Bone Ceramic group was 15.82% and 21.36% in the Bio-Oss group.

Conclusion



Puros Allograft Cancellous Particles have been largely converted to vital bone within 5 months. Placement of primary stable implants can be achieved.

PROSPECTIVE STUDY

Maxillary Sinus Augmentation With Puros Allograft Particles

Maxillary Sinus Augmentation With Bio-Oss

Froum SJ et al. Comparison of mineralized cancellous bone allograft (Puros) and anorganic bovine bone matrix (Bio-Oss) for sinus augmentation: histomorphometry at 26 to 32 weeks after grafting. *Int J Periodont Rest* (2006) 26:543-551.

Study Design

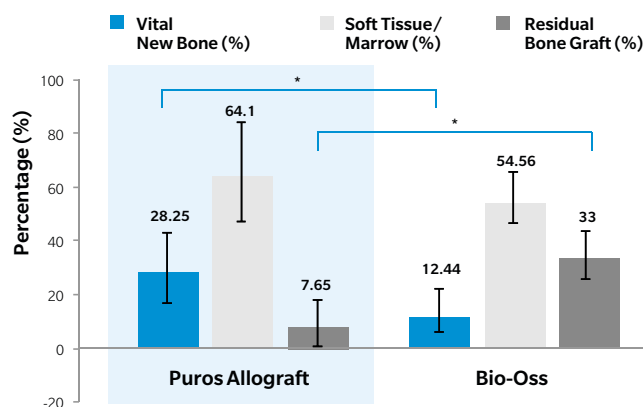
Patients (n=13) with residual bone height ≤ 5 mm in posterior maxilla were divided into two groups and bilateral maxillary sinus floor augmentations performed. The augmentations were performed in the split mouth design with: (I) Puros Allograft Cancellous Particles 50:50 (0.25–1 : 1–2 mm); (II) Bio-Oss 50:50 (0.25–1 : 1–2 mm). At re-entry (after a healing period of 6 to 7 months) a total of 20 biopsies were taken and a histological and histomorphometric analysis conducted.

Results

The volume of newly formed, vital bone in the Puros Allograft group is higher than in the Bio-Oss group. The proportion of non-vital residual particles is significantly lower in the Puros Allograft group than in the Bio-Oss.

Conclusion

Histomorphometry After 6–7 Months Healing Time



Puros Allograft Cancellous Particles are a suitable alternative to autologous bone or bovine bone substitute in maxillary sinus floor augmentation. **New bone formation is significantly higher compared to Bio-Oss.**

1. Tadic D, Beckmann F, Donath T, Epple M. Comparison of different methods for the preparation of porous bone substitution materials and structural investigations by synchrotron μ -computer tomography. *Materialwiss. Werkstofftech.* (2004) 35:240-244.
2. Thorwarth M, Schlegel KA, Srour S, Wiltfang J. Knöcherne Reparatur ossärer Defekte - Einsatz partikulärer homologer und boviner Knochenersatzmaterialien - erste tierexperimentelle Ergebnisse. *ZWR* (2004) 113:427-436.
3. Tadic D, Epple M. A thorough physicochemical characterisation of 14 calcium phosphate-based bone substitution materials in comparison to natural bone. *Biomaterials* (2004) 25:987-94.
4. Froum SJ, Tarnow DP, Wallace SS, Jalbout Z, Cho SC, Rohrer MD, Prasad HS. The use of a mineralized allograft for sinus augmentation: an interim histological case report from a prospective clinical study. *Compend Contin Educ Dent* (2005) 26:259-265.
5. Noubissi SS, Lozada JL, Boyne PJ, Rohrer MD, Clem D, Kim JS, Prasad H. Clinical, histologic, and histomorphometric evaluation of mineralized solvent-dehydrated bone allograft (Puros) in human maxillary sinus grafts. *J Oral Implantol* (2005) 31:171-9.
6. Schau I, Plöger M. Externer Sinuslift step-by-step: die laterale Window-Technik. *Dentale Implantologie & Parodontologie* (2005) 9:548-555.
7. Shin HI, Sohn DS. A method of sealing perforated sinus membrane and histologic finding of bone substitutes: a case report. *Implant Dent.* (2005) 14:328-33.
8. Froum SJ, Wallace SS, Elian N, Cho SC, Tarnow DP. Comparison of mineralized cancellous bone allograft (Puros) and anorganic bovine bone matrix (Bio-Oss) for sinus augmentation: histomorphometry at 26 to 32 weeks after grafting. *Int J Periodont Rest Dent* (2006) 26:543-51.
9. Gapski R, Neiva R, Oh TJ, Wang HL. Histologic analyses of human mineralized bone grafting material in sinus elevation procedures: a case series. *Int. J. Periodont. Rest. Dent.* (2006) 26:59-69.
10. Whitesides LM, Radwan A, Sharawy M. Sinus floor augmentation using a composite graft of bone morphogenic protein-2 and allogenic cancellous bone (puros): case report. *J Oral Implantol.* (2006) 32:259-264.
11. Kneser U, Stangenberg L, Ohnolz J, Buettner O, Stern-Straeter J, Möbest D, Horch RE, Stark GB, Schaefer DJ. Evaluation of processed bovine cancellous bone matrix seeded with syngenic osteoblasts in a critical size calvarial defect rat model. *J Cell Mol Med* (2006) 10:695-707.
12. Aghaloo TL, Moy PK. Which hard tissue augmentation techniques are the most successful in furnishing bony support for implant placement? *Int J Oral Maxillofac Implants* (2007) 22 Suppl:49-70.
13. Thorwarth M, Wehrhan F, Srour S, Schultze-Mosgau S, Felszeghy E, Bader RD, Schlegel KA. Evaluation of substitutes for bone: comparison of microradiographic and histological assessments. *Br J Oral Maxillofac Surg* (2007) 45:41-7.
14. Baumgarten S. Allograft-Sinuslift mit XIVE-S plus Implantat. *Implant/Direkt* (2008) 3:6-9.
15. Minichetti JC, D'amore JC, Hong AY. Three-year analysis of tapered screw vent implants placed into maxillary sinuses grafted with mineralized bone allograft. *J Oral Implantol* (2008) 34:135-41.
16. Pikos MA. Maxillary sinus membrane repair: update on technique for large and complete perforations. *Implant Dent.* (2008) 17:24-31.
17. Meyer S, Floerkemeier T, Windhagen H. Histological osseointegration of Tutobone (R): first results in human. *Arch Orthop Traum Su* (2008) 128:539-544.
18. Tudor C, Srour S, Thorwarth M, Stockmann P, Neukam FW, Nkenke E, Schlegel KA, Felszeghy E. Bone regeneration in osseous defects - application of particulated human and bovine materials. *Oral Surg Oral Med O* (2008) 105:430-436.
19. Sohn DS, Lee JK, An KM, Shin HI. Histomorphometric Evaluation of Mineralized Cancellous Allograft in the Maxillary Sinus Augmentation: A 4 Case Report *Implant Dent* (2009) 18:172-181.
20. Baumgarten S. Sinus grafting with mineralized allograft and staged implant placement. *Quintessence Int.* (2010) 41:197-202.
21. Noubissi SS, Kleinman AJ. A comparative clinical, histological and histomorphometric study of mineralized allograft and xenograft materials in the treatment of atrophic maxillary sinuses. *Journal of Implant and Advanced Clinical Dentistry* (2010) 2:47-60.
22. Zimmer Dental. Der Sinuslift: Risiken und Möglichkeiten eines etablierten Routineeingriffs. *ZWR* (2010) 119:450,450.

23. Annibaldi S, Cristalli MP, La Monaca G, Bignozzi I, Scarano A, Corrado R, Lo Muzio L. Human maxillary sinuses augmented with mineralized, solvent-dehydrated bone allograft: a longitudinal case series. *Implant Dent* (2011) 20:445-54.
24. Soardi CM, Spinato S, Zaffe D, Wang HL. Atrophic maxillary floor augmentation by mineralized human bone allograft in sinuses of different size: an histologic and histomorphometric analysis. *Clin Oral Implants Res* (2011) 22:560-6.
25. Bernardello F, Righi D, Cosci F, Bozzoli P, Soardi Carlo M, Spinato S. Crestal sinus lift with sequential drills and simultaneous implant placement in sites with <5 mm of native bone: a multicenter retrospective study. *Implant Dent* (2011) 20:439-444 10.1097/ID.0b013e3182342052.
26. Soardi CM, Wang H-L. New crestal approach for lifting sinus in the extremely atrophic upper maxillae. *Clinical Advances in Periodontics* (2012) 2:179-185.
27. Ayobian-Markazi N, Fouroutan T, Kharazifar MJ. Comparison of cell viability and morphology of a human osteoblast-like cell line (SaOS-2) seeded on various bone substitute materials: An in vitro study. *Dental research journal* (2012) 9:86-92.
28. Schmitt CM, Doering H, Schmidt T, Lutz R, Neukam FW, Schlegel KA. Histological results after maxillary sinus augmentation with Straumann(R) BoneCeramic, Bio-Oss(R), Puros(R), and autologous bone. A randomized controlled clinical trial. *Clin Oral Implants Res* (2013) 24:576-85.
29. Berberi A, Nader N. Subantral augmentation with mineralized cortical bone allograft material: clinical, histological, and histomorphometric analyses and graft volume assessments. *Implant Dent* (2016) 25:353-60.
30. Soardi CM, Clozza E, Turco G, Biasotto M, Engebretson SP, Wang H-L, Zaffe D. Microradiography and microcomputed tomography comparative analysis in human bone cores harvested after maxillary sinus augmentation: a pilot study. *Clin Oral Implants Res* (2014) 25:1161-1168.

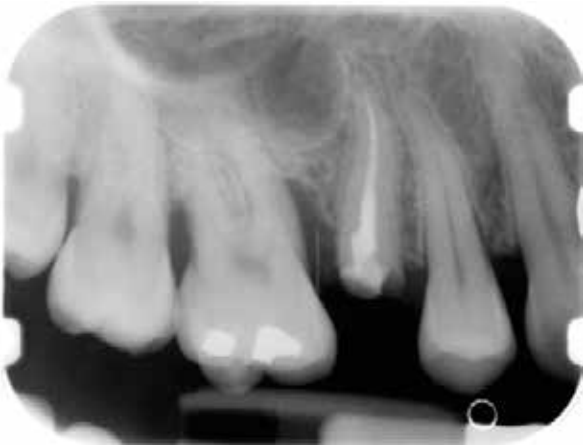CASE 1 Tooth [14-16]

PRACTITIONER

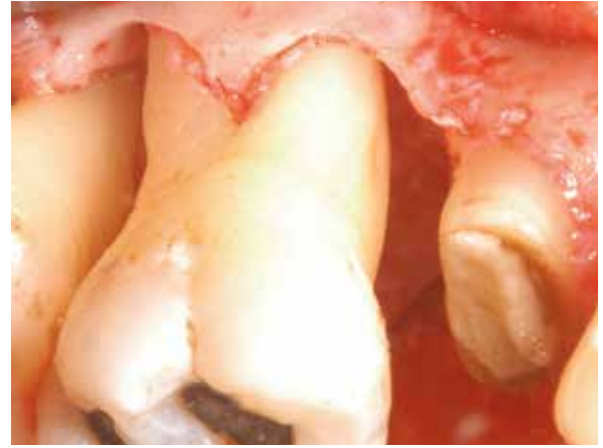Dr. D. Engler-Hamm
Munich (Germany)

MATERIAL

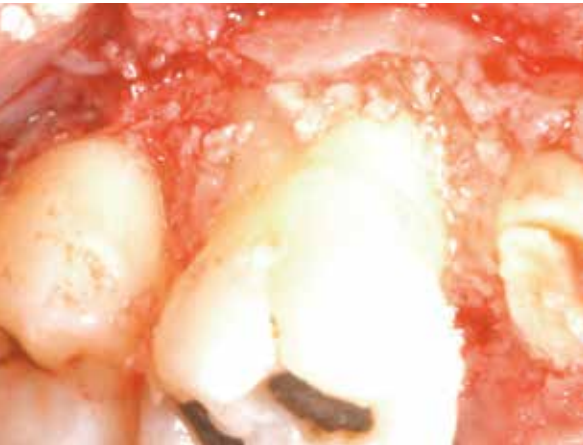• Puros Allograft Cancellous Particles 0.25–1 mm, 0.5 cc*



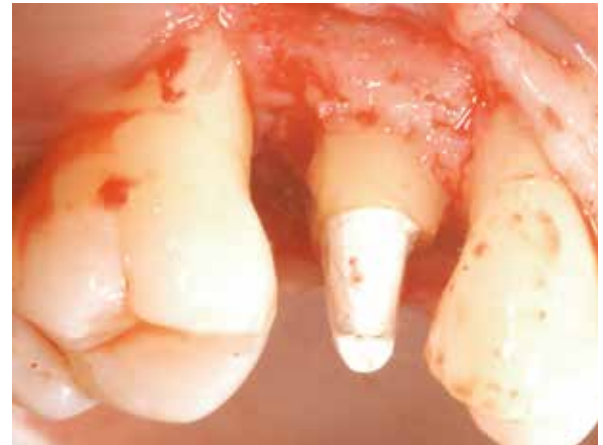1 Bony defect mesially, tooth [16].



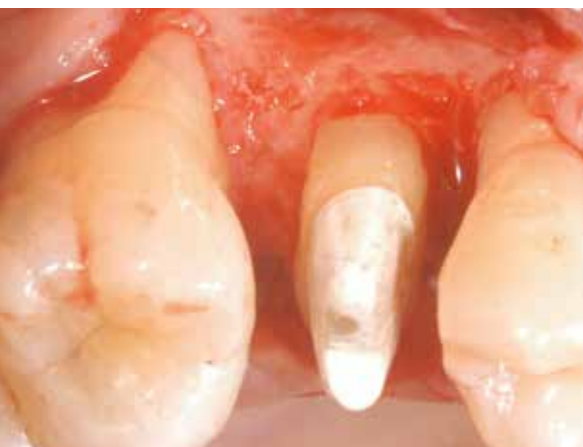2 Intraoperative bony defect, probing depth 7 mm following Phase I treatment.



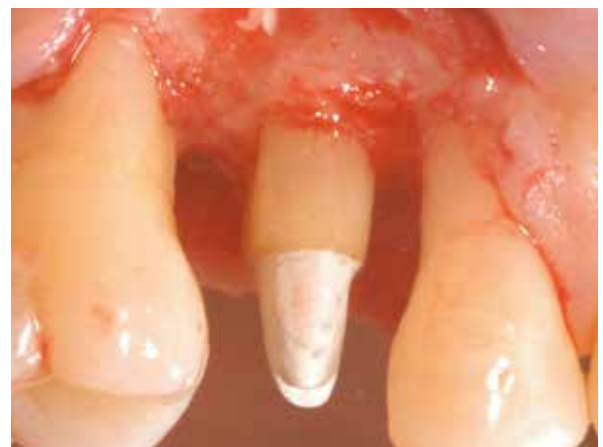3 Augmentation with Puros Allograft Cancellous Particles.*



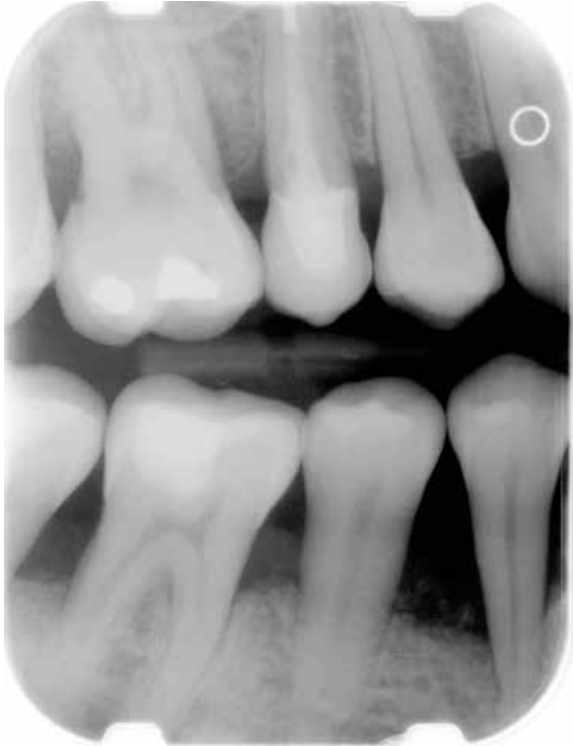4 Re-entry 9 months post-op due to need for surgical crown extension mesial of tooth [15].



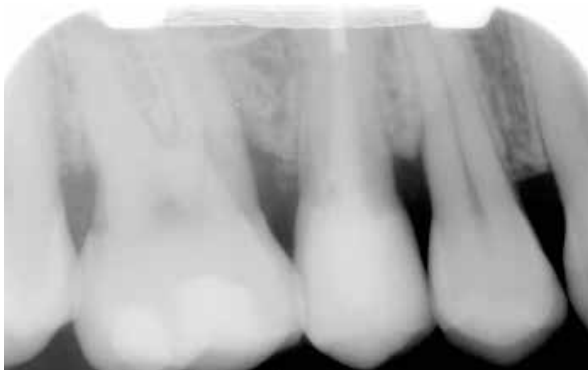5 Occlusal view following odontoplasty (mesial) tooth [15], ostectomy and osteoplasty.



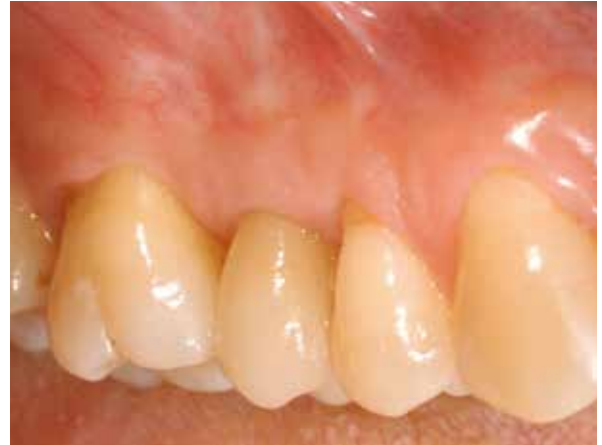6 Lateral view following surgical crown extension.



7 Radiograph taken 12 months after regenerative procedure.



9 Periapical radiograph taken 5 years after regenerative procedure.



8 5-year follow up. Lateral view.

* in combination with with enamel matrix proteins.

Clinical photographs courtesy of Dr. D. Engler-Hamm. Individual results may vary.

SCIENTIFICALLY PROVEN: INTERNATIONAL LITERATURE REVIEW

CASE SERIES

Treatment of periodontal defects using Puros Allograft Cancellous Particles

Browning ES et al. Evaluation of a mineralized cancellous bone allograft for the treatment of periodontal osseous defects: 6-month surgical reentry. Int J Periodont Rest Dent (2009) 29:41-47.

Study Design

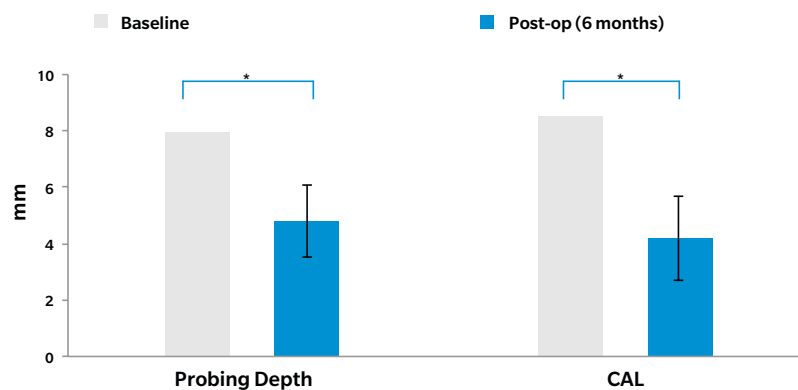
In patients (n=20, av. 55 years) with chronic periodontitis and at least one intrabony defect (radiological bone defect ≥ 4 mm, probing depth ≥ 7 mm) the study evaluated the effectiveness of Puros Allograft Cancellous Particles for the treatment of periodontal osseous defects. A full flap procedure was followed by debridement of the defect, root planning, placement of bone graft, and then flap closure. Clinical and surgical measurements were taken at baseline and at 6-month re-entry.

Results

Following grafting and healing, **average probing depth reduction** was 4.8 ± 1.3 mm. Average **gain in clinical attachment (CAL)** was 4.2 ± 1.5 mm. Both changes were statistically significant. Bone fill was $66.8\% \pm 26.2\%$ and average percent defect resolution was $71.5\% \pm 25.5\%$.

Conclusion

Clinical Measurements After 6 Months



Puros Allograft Cancellous Particles are a promising and effective material for the treatment of osseous defects in patients with chronic periodontitis.

BIBLIOGRAPHY

1. Yukna RA, Vastardis S, Mayer ET. Puros vs. Demineralized freeze-dried bone in human periodontal osseous defects. in IADR/AADR/CADR 83rd General Session. 2005. Baltimore.
2. Tsao YP, Neiva R, Al-Shammari K, Oh TJ, Wang HL. Effects of a mineralized human cancellous bone allograft in regeneration of mandibular Class II furcation defects. *J Periodontol* (2006) 77:416-25.
3. Vastardis S, Yukna RA. Evaluation of allogeneic bone graft substitute for treatment of periodontal osseous defects: 6-month clinical results. *Compend Contin Educ Dent* (2006) 27:38-44.
4. Wang HL, Boyapati L. "PASS" principles for predictable bone regeneration. *Implant Dent* (2006) 15:8-17.
5. Browning ES, Mealey BL, Mellonig JT. Evaluation of a mineralized cancellous bone allograft for the treatment of periodontal osseous defects: 6-month surgical reentry. *Int J Periodont Rest Dent* (2009) 29:41-47.
6. Koylass JM, Valderrama P, Mellonig JT. Histologic evaluation of an allogeneic mineralized bone matrix in the treatment of periodontal osseous defects. *Int J Periodontics Restorative Dent* (2012) 32:405-11.
7. Engler-Hamm D, Fickl S. Langzeiterfolg der parodontalen Regeneration. *Quintessenz* (2015) 66:761-767.

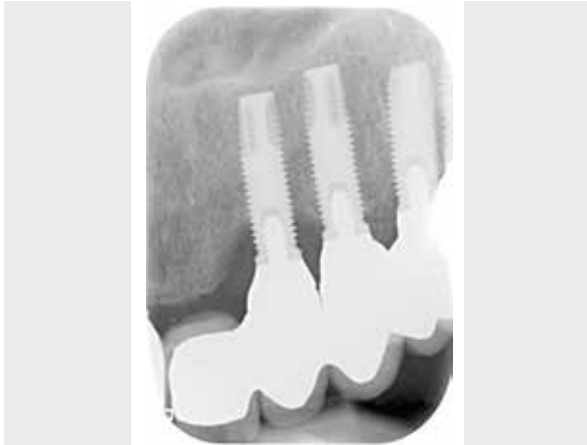CASE 1 Site [21-22]

PRACTITIONER

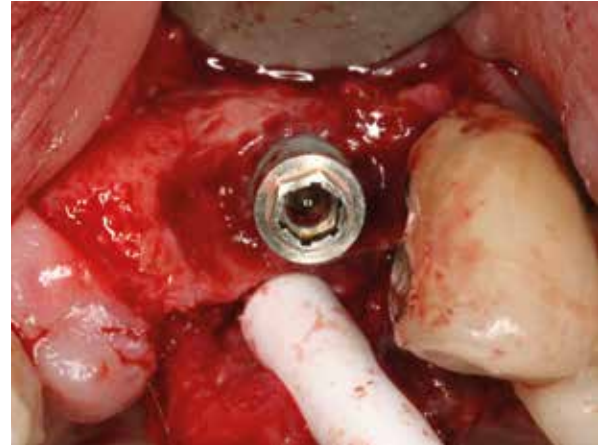
Dr. Ö. Solakoglu
Hamburg (Germany)

MATERIAL

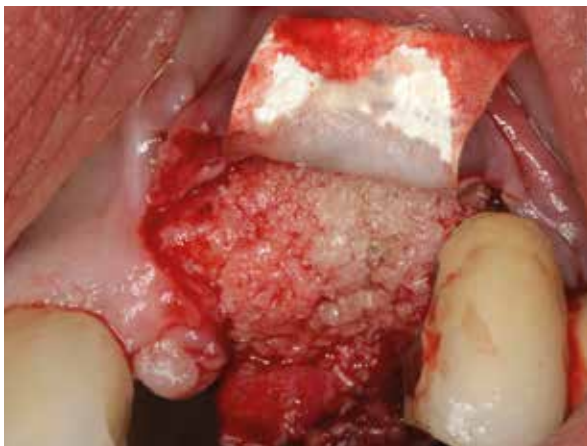- Puros Allograft Cancellous Particles 0.25–1 mm, 0.5 cc
- CopiOs Pericardium Membrane 15 x 20 mm



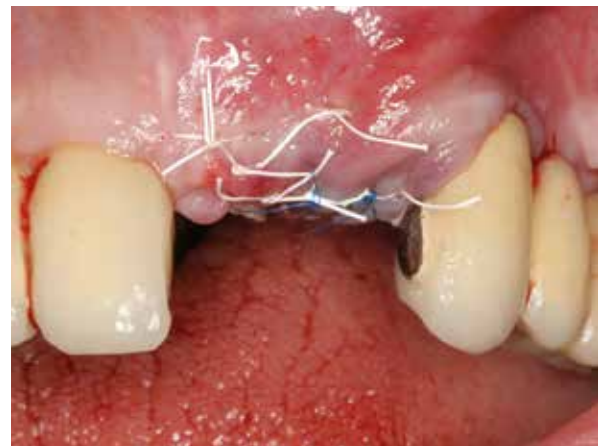1 Peri-implant bone defect in site [22] on a Brånemark System® Mk IV Implant, 12 years in place.



2 Bone defect after flap formation.*



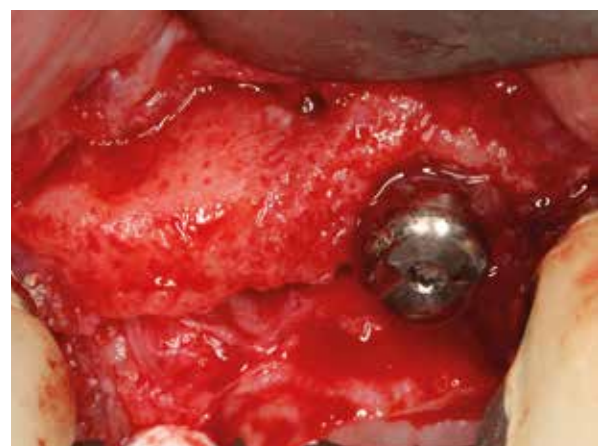3 Augmentation with Puros Allograft Cancellous Particles** and draping with CopiOs Pericardium Membrane.



4 Wound closure.



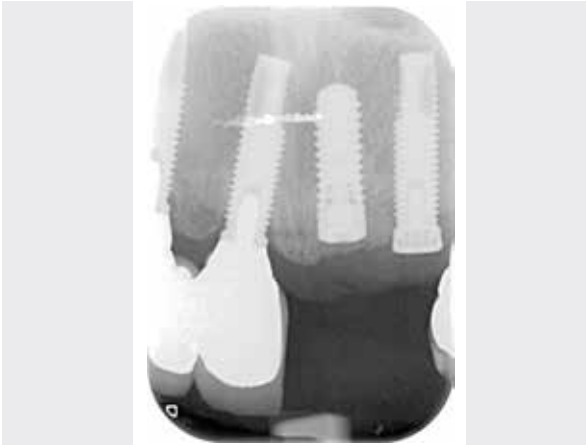5 Radiograph site [22] after peri-implantitis treatment.



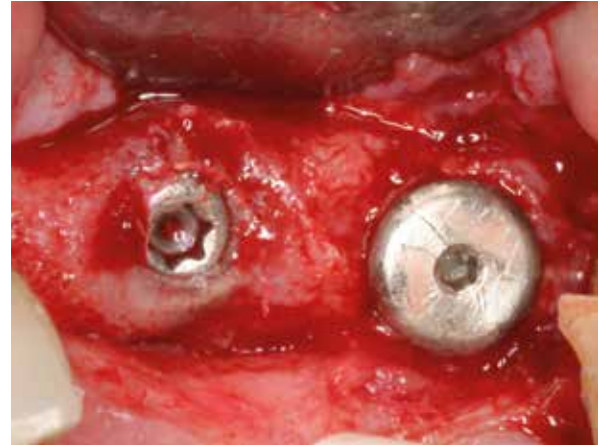6 4-month post-op re-entry, regenerated vital bone around implant.

* Decontamination of implant surface: Details of the decontamination of the implant surface are presented in detail in the published article.

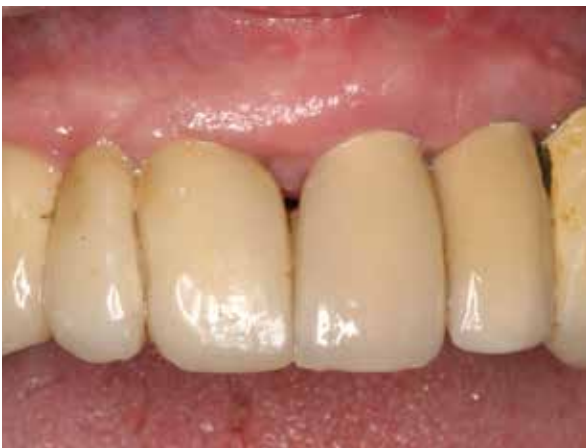** Puros Allograft Cancellous Particles were mixed with PRGF before delivery (third phase).



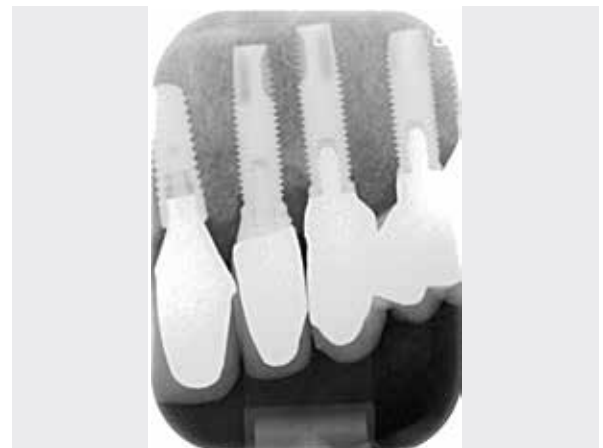7 Post-implant radiograph of site [21].



8 Reentry, site [21], healing period 4 months.



9 Definitive prosthetic restoration with PFM crowns 9 months post-augmentation, lateral view.



10 Radiograph taken after 9 months post-augmentation with prosthetics.

The procedure is published:

Solakoglu Ö. Therapie der Periimplantitis – ein Protokoll für klinischen Erfolg.

Zahnarzt & Praxis (2011) 14:306-315.

Clinical photographs courtesy of Dr. Ö. Solakoglu. Individual results may vary.

1. Solakoglu Ö. Therapie der Periimplantitis - ein Protokoll für klinischen Erfolg. *Zahnarzt & Praxis* (2011) 14:306-315.
2. Froum SJ, Froum SH, Rosen PS. Successful management of peri-implantitis with a regenerative approach: a consecutive series of 51 treated implants with 3- to 7.5-Year follow-up. *Int J Periodont Rest Dent* (2012) 32:11-20.

PUROS ALLOGRAFT – FACTS YOU SHOULD KNOW

Zimmer Biomet's Puros family of hard-tissue grafting products provides an effective and predictable¹ clinical outcome for patients requiring bony enhancement in a timely manner. Puros Cancellous Particulates act as an osteoconductive scaffold, enabling the ingrowth of vascular and cellular connective tissue.²

Leading

Puros Allograft products are used worldwide in clinical practice.

Clinically And Scientifically Proven

Puros Allografts, a leading allograft brand, are distributed in many countries worldwide, and have more than 200 studies in dental applications supporting their reliability and predictability during bony augmentation procedures. A face-to-face study shows superior bone formation and remodeling compared to freeze-dried allograft particulates.³

Multi-Step Safety System

1. Donor Selection

Donor selection and serological testing comply with EU⁴⁻⁶ and national guidelines.⁷⁻⁹

2. Tissue processing in the Tutoplast Process

The Tutoplast process gently removes unwanted components. The process preserved the biomechanical properties and has been validated for inactivation of viruses and pathogens. Virus inactivation by $\leq 12 \log^{10}$ has been validated and confirmed by several different, independent institutions.¹⁰

3. Terminal low-dose gamma irradiation

All Puros Allograft products are sterilized using terminal low-dose gamma irradiation: Sterility assurance level: 10^{-6} .¹¹

Vitality

Puros Allograft products have the structural properties of natural tissue. These properties allow them to produce more new, vital bone in comparison with xenogeneic and synthetic products.¹²

Handling And Strength

The Tutoplast process does not affect the mechanical properties of the products.¹³ This enables comfortable handling and secure fixing of Puros Allograft products (e.g. Puros Allograft Bone Blocks).

Safety, Reliability, Consistency

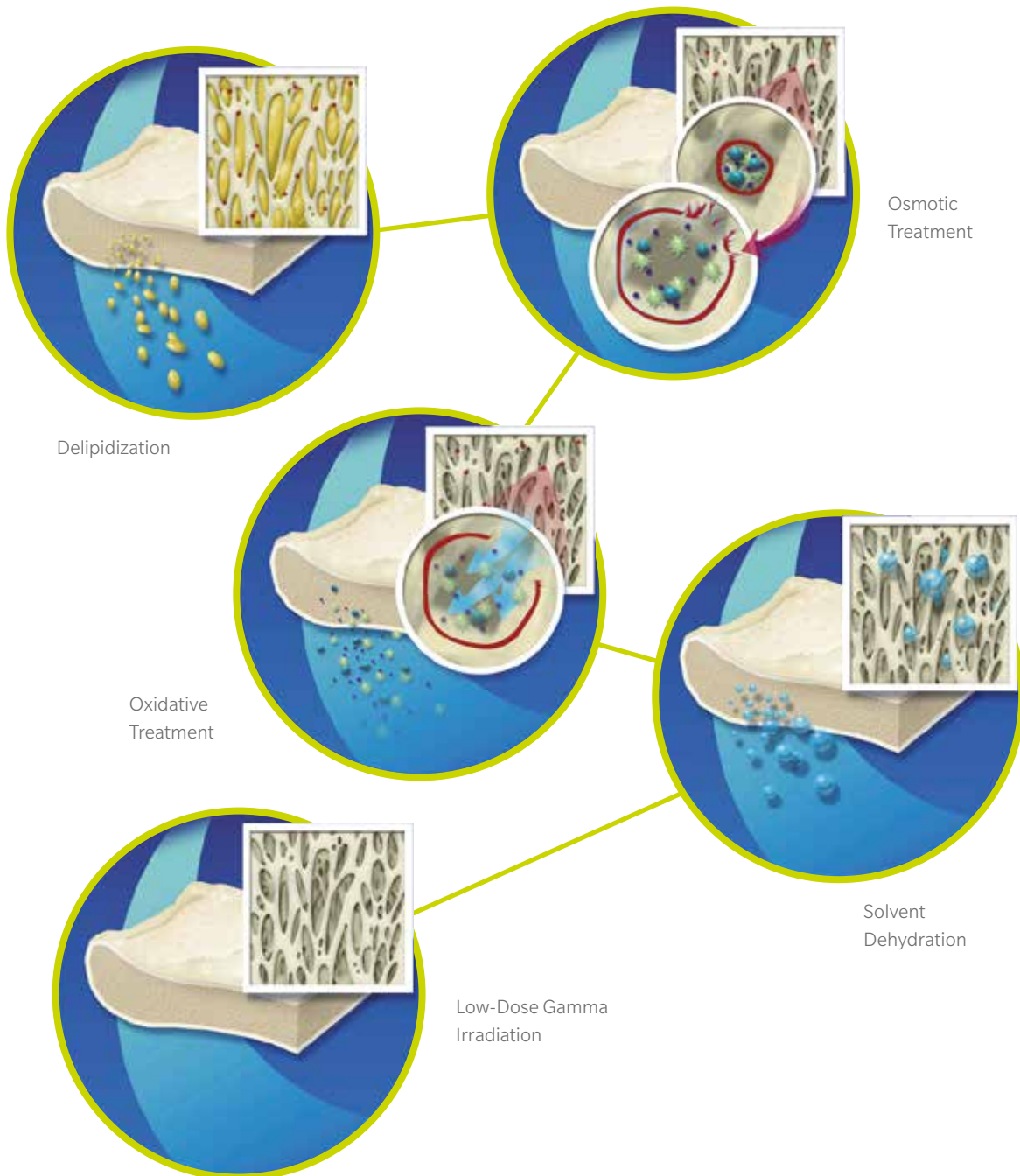
For over 40 years, Tutoplast processed tissues have been safely used in more than 5 million procedures.¹⁰

REFERENCES

1. Sterio TW, Katancik JA, Blanchard SB, Xenoudi P, Mealey BL. A prospective, multicenter study of bovine pericardium membrane with cancellous particulate allograft for localized alveolar ridge augmentation. *Int J Periodont Rest Dent* (2013) 33:499-507.
2. Minichetti JC, D'Amore JC, Hong AY, Cleveland DB. Human histologic analysis of mineralized bone allograft (Puros) placement before implant surgery. *J Oral Implantol* (2004) 30:74-82.
3. Monje A, O'valle F, Monje-Gil F, Ortega-Oller I, Mesa F, Wang HL, Galindo-Moreno P. Cellular, vascular, and histomorphometric outcomes of solvent-dehydrated vs freeze-dried allogeneic graft for maxillary sinus augmentation: a randomized case series. *Int J Oral Maxillofac Implants* (2017) 32:121-127.
4. European Commission: Directive 2004/23/EC. DIRECTIVE 2004/23/EC OF THE EUROPEAN PARLIAMENT AND OF THE COUNCIL of 31 March 2004 on setting standards of quality and safety for the donation, procurement, testing, processing, preservation, storage and distribution of human tissues and cells. *Official Journal of the European Union* (2004) L102:48-58.
5. European Commission: Directive 2006/17/EC. COMMISSION DIRECTIVE 2006/17/EC of 8 February 2006 implementing Directive 2004/23/EC of the European Parliament and of the Council as regards certain technical requirements for the donation, procurement and testing of human tissues and cells. *Official Journal of the European Union* (2006) L38:40-52.
6. European Commission: Directive 2006/86/EC. COMMISSION DIRECTIVE 2006/86/EC of 24 October 2006 implementing Directive 2004/23/EC of the European Parliament and of the Council as regards traceability requirements, notification of serious adverse reactions and events and certain technical requirements for the coding, processing, preservation, storage and distribution of human tissues and cells. *Official Journal of the European Union* (2006) L294:32-50.
7. Regulation on quality and safety requirements on collection of tissue samples and their transfer in accordance with the Transplant Act (TPA Tissue Regulation: TPG-GewV) of 26 March 2008. 2008, *Federal Law Gazette Part I No. 12*. p. 512-520.
8. Bundesärztekammer. Richtlinien zum Führen einer Knochenbank. *Deutsches Ärzteblatt* (2001) 98:A1011-A1016.
9. Paul-Ehrlich-Institut, Bundesgesundheitsamt. Virussicherheit / Diagnostik - Validierung: Anforderungen an Validierungsstudien zum Nachweis der Virussicherheit von Arzneimitteln aus menschlichem Blut oder Plasma. *Bundesanzeiger* (1994) 84:4742-4744.
10. Data on file at Tutogen and RTI Biologics, Inc.
11. DIN EN ISO 11137-1, Sterilisation von Produkten für die Gesundheitsfürsorge – Strahlen – Teil 1: Anforderungen an die Entwicklung, Validierung und Lenkung der Anwendung eines Sterilisationsverfahrens für Medizinprodukte. 2013.
12. Schmitt CM, Doering H, Schmidt T, Lutz R, Neukam FW, Schlegel KA. Histological results after maxillary sinus augmentation with Straumann(R) BoneCeramic, Bio-Oss(R), Puros(R), and autologous bone. A randomized controlled clinical trial. *Clin Oral Implants Res* (2013) 24:576-85.
13. Thull R, Sturm A, Pesch H-J, *Mechanische Eigenschaften nativer und präparierter Spongiosa*, in *Osteologie aktuell VII*, H.-J. Pesch, H. Stoess, and B. Kummer, Editors. 1993, Springer: Berlin. p. 157-163.

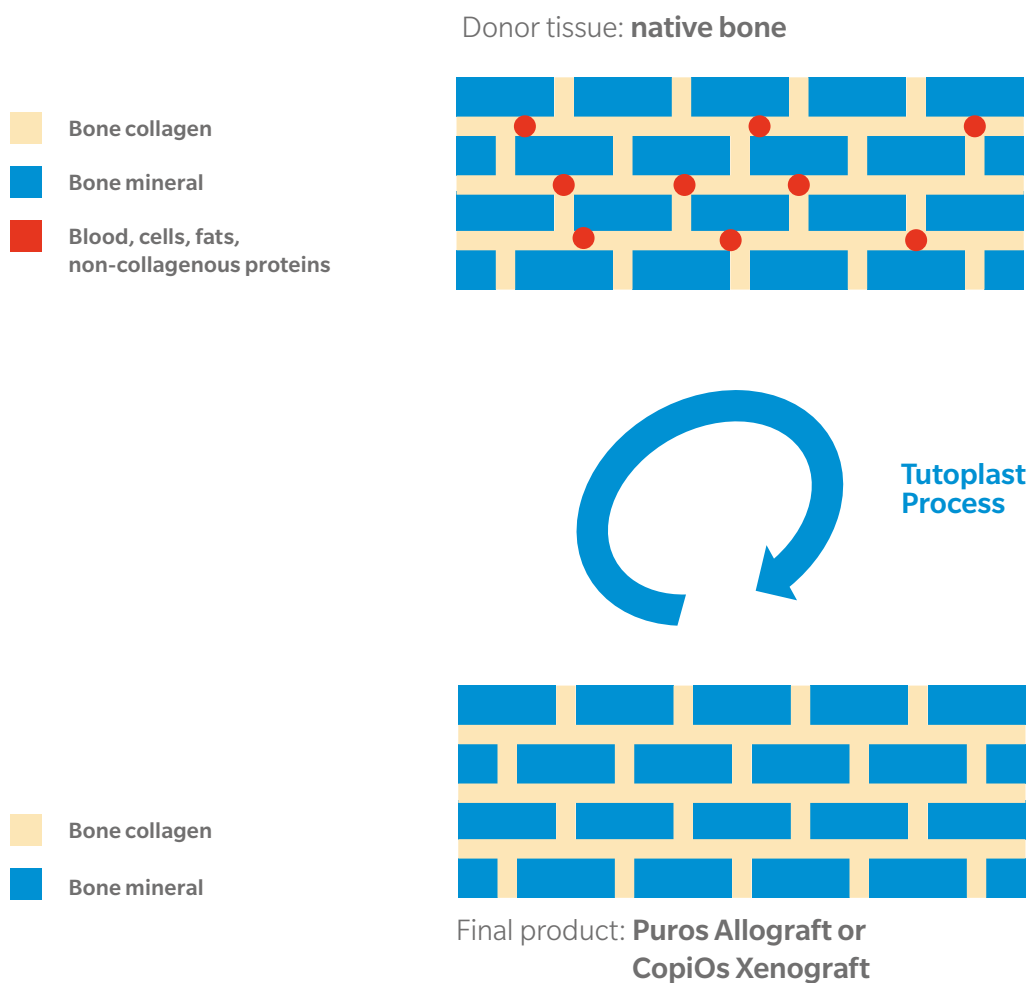
THE PROPRIETARY TUTOPLAST® PROCESS

Processing Of Puros Allograft And
CopiOs Xenograft Bone Grafts



The Proprietary Tutoplast Process

Puros Allograft and CopiOs Xenograft products are manufactured using the Multi-Step Tutoplast Process. The **process** aims to preserve the **natural collagen and mineral structure** of the hard tissue, providing a scaffold for regeneration and assimilation into the recipient bed. The Tutoplast Process has been scientifically validated for **preservation** of tissue biomechanical properties, viral, bacterial and spore inactivation. It has been used for more than **40 years** in the manufacture and sterilization of donated tissues. Tutoplast-processed tissues have been used in more than **5 million procedures** to date.¹ The safety of the Tutoplast Process is attested by the fact that there has not been a **single reported case** of allograft-associated infection.¹



1. Data on file at RTI Surgical, Inc.





Contact us at 1-800-342-5454 or visit

zimmerbiometdental.com



Zimmer Biomet Dental
Global Headquarters
4555 Riverside Drive
Palm Beach Gardens, FL 33410
Phone: +1-561-776-6700
Fax: +1-561-776-1272

+31(0) 577 - 46 1927 | www.implacom.nl

Name of the medicinal product: PUROS® ALLOGRAFT | **Composition:** Human cancellous tissue (with cortical component in the Puros® Allograft Blend version), preserved using the Tutoplast® Process, sterilised by gamma irradiation. | **Therapeutic indications:** To cover or fill bone defects or to create bony structures in maxillofacial surgery. Therapeutic indications for which positive experience has been reported include the following: Regeneration of periodontal bone defects; Regeneration of furcation defects; Regeneration following cyst resection and apicoectomy; Regeneration of extraction sockets; Regeneration of gaps between the alveolar wall and dental implants; Regeneration of defects following block removal; Regeneration of gaps around block grafts; Horizontal alveolar ridge augmentation (particles); Sinus augmentation; Three-dimensional (horizontal and/or vertical) alveolar ridge augmentation (block augmentation). Further applications have been described in other surgical specialties. | **Contraindications:** None known. | **Undesirable effects** (frequency cannot be estimated from the available data): Graft rejection, implant site reaction, graft failure. As with every surgical procedure, there is the possibility of infection due to the procedure itself. | **Warnings:** Store dry, sunlight protected and not over 30 °C. Do not freeze. Discard any unused material; do not resterilise! See also instruction for use. Keep out of reach of children. | **General classification for supply:** Prescription only. | **Further information:** see package leaflet; | **Date of revision of the text:** 02.2018 „11“. | **Pharmaceutical Entrepreneur:** Tutogen Medical GmbH, Industriestraße 6, 91077 Neunkirchen am Brand, Germany | **Co-distributor:** Zimmer Dental GmbH, Wilhelm-Wagenfeld-Str. 28, D - 80807 München.

Unless otherwise indicated, as referenced herein, all trademarks are the property of Zimmer Biomet; and all products are manufactured by one or more of the dental subsidiaries of Zimmer Biomet Holdings, Inc. and marketed and distributed by Zimmer Biomet Dental and its authorized marketing partners. Tutoplast is a registered trademark of Tutogen Medical GmbH. Bio-Oss is a registered trademark of Geistlich Pharma AG. Brånemark System is a registered trademark of Nobel Biocare Services AG. CollaPlug and CollaTape are registered trademarks of Integra Life Sciences Corporation. Cytoplast is a registered trademark of Osteogenics Biomedical, Inc. Straumann and BoneCeramic are trademarks of Institut Straumann AG. Osteograf and Algipore are trademarks of Dentsply. CollaPlug and CollaTape are manufactured by Integra. The Zimmer Socket Repair Membrane is manufactured by Collagen Matrix, Inc. Puros is manufactured by RTI Surgical, Inc. CopiOs Pericardium are manufactured by Tutogen Medical GmbH. CopiOs Pericardium is manufactured by RTI Surgical, Inc. For additional product information, please refer to the individual product labeling/IFU. Product clearance and availability may be limited to certain countries/regions. This material is intended for clinicians only and does not comprise medical advice or recommendations. This material may not be copied or reprinted without the express written consent of Zimmer Biomet. ZB0012 REV A 05/19 ©2019 Zimmer Biomet, All rights reserved.

